

# Progress Report

## Orthotopic Cardiac Prosthesis for Two-Stage Cardiac Replacement\*

DENTON A. COOLEY, M.D., F.A.C.C., DOMINGO LIOTTA, M.D., GRADY L. HALLMAN, M.D., F.A.C.C.,  
ROBERT D. BLOODWELL, M.D., F.A.C.C., ROBERT D. LEACHMAN, M.D., F.A.C.C. and  
JOHN D. MILAM, M.D.

Houston, Texas

Clinical experience with cardiac transplantation has evidenced the feasibility of cardiac replacement in man but has made apparent the need for a mechanical device that will provide circulation and sustain life in emergency conditions while a suitable allograft is obtained. The cardiac prosthesis used in a 47 year old man consisted of two reciprocating pumps constructed entirely of synthetic materials and activated pneumatically in the orthotopic position by a control console connected by tubes passed through the patient's chest wall. The device supported the patient's circulation for 64 hours while a donor for cardiac transplantation was obtained. Death of the recipient from *Pseudomonas pneumonia* occurred 32 hours after the allografting. The first successful prolonged use of a total mechanical substitute for the human heart is recorded.

SINCE THE FIRST SUCCESSFUL HUMAN TRANSPLANTATION in December 1967, the need for a temporary mechanical device to support circulation in a patient dying of cardiac decompensation has been apparent.<sup>1,2</sup> The circumstances of cardiac allografting pose a unique problem since salvaging the life of a recipient must coincide with the simultaneous death of a donor. Synchronization of the events may not be possible for many reasons, and the potential recipient is the victim of the situation. In answer to this problem a concept of two-staged cardiac replacement was evolved using a mechanical pump with properties better suited for prolonged circulatory support than the usual mechanical heart-lung device used for temporary cardiopulmonary bypass. Long-term circulatory support by the mechanical heart-lung is precluded by the continuous flow characteristics of the roller pumps and the trauma to blood from the artificial oxygenators. Thus, prolonged safe perfusion was sought in development of a total

orthotopic cardiac prosthesis which produced a pulsatile flow and provided respiratory function by utilization of the patient's own lungs.

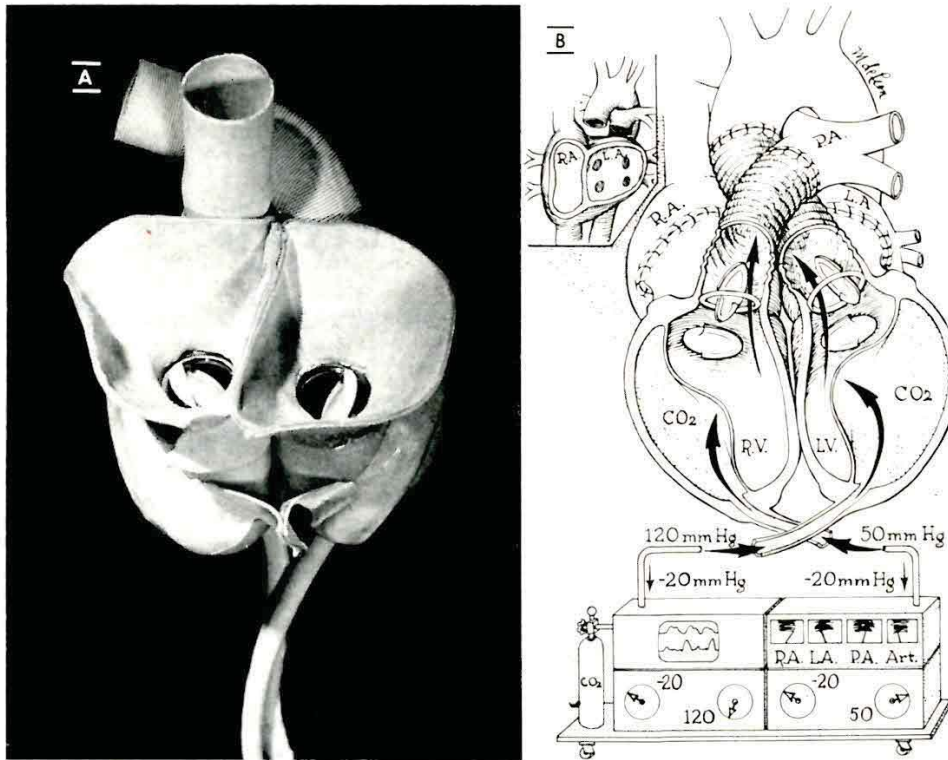
This report describes the emergency use of a total mechanical cardiac replacement for 64 hours in a 47 year old man with terminal cardiac disease who died 32 hours after cardiac transplantation.

### THE CARDIAC PROSTHESIS

The pneumatically controlled, double-ventricle cardiac prosthesis was a reciprocating pump of the diaphragm type fabricated of Dacron<sup>®</sup> (U. S. Catheter and Instrument Corp.) embedded in Silastic<sup>®</sup> (Dow Corning Corp.) (Fig. 1). Details of design and flow characteristics have been reported elsewhere.<sup>3</sup> A prototype was described in 1961.<sup>4</sup> Wada-Cutter hingeless valves were incorporated in the inflow and outflow areas of the prosthesis. These valves were chosen for their large central orifice, which provided unobstructed flow of blood, and for

\* From The Texas Heart Institute of St. Luke's-Texas Children's Hospitals, Houston, Texas. Manuscript received August 1, 1969, accepted August 18, 1969.

Address for reprints: Denton A. Cooley, M.D., The Texas Heart Institute of St. Luke's-Texas Children's Hospitals, P. O. Box 20345, 6621 Fannin St., Houston, Texas 77025.



**Figure 1.** A, photograph of total cardiac prosthesis consisting of two pumps or ventricles and four hingeless Wada-Cutter valve prostheses. B, diagram showing technique of implantation and method of activating the reciprocating pump units with an extracorporeal pneumatic system. Art. = arterial; L.A. = left atrium; P.A. = pulmonary artery; R.A. = right atrium; R.V. = right ventricle.

their low clinical incidence of thromboembolic complications. The pump chambers, cuff-shaped inflow tracts (atria), and infundibular-shaped outflow tracts were lined with a special reticular fabric to promote the formation of an autologous blood interface. The flexible inflow tracts were impervious to air and fluid, and the grafts (25 mm.) used for the pulmonary artery and aorta were of tightly woven Dacron. Constructed of Dacron and Silastic, the pumps were fabricated in three components: body, dome and diaphragms. A new type of diaphragm, especially fabricated to 0.045 in. thickness with modifications to minimize stress and wear, was used in this pump.

**Control System of the Cardiac Prosthesis:** The orthotopic pumps were connected to the external energizing unit by Silastic tubing (inner diameter 5 mm.) covered with a special Dacron fabric. The tubes were tunneled downward from the prosthesis and emerged at the left hypochondrium. Two pneumatic power units, each containing a motor-driven pump, generated the pressure and vacuum required for pulsing the prosthesis (designed and manufactured by Texas Medical Instruments and William O'Ban-

non, P. O. Box 36221, Houston, Texas.) (Fig. 2). Carbon dioxide was used as the transmitting medium. The pulse timer unit consisted of rate and duration circuits which controlled the solenoid valve.

**Performance of the Prosthesis:** The hydraulic pressures used to activate the pumps were as follows:

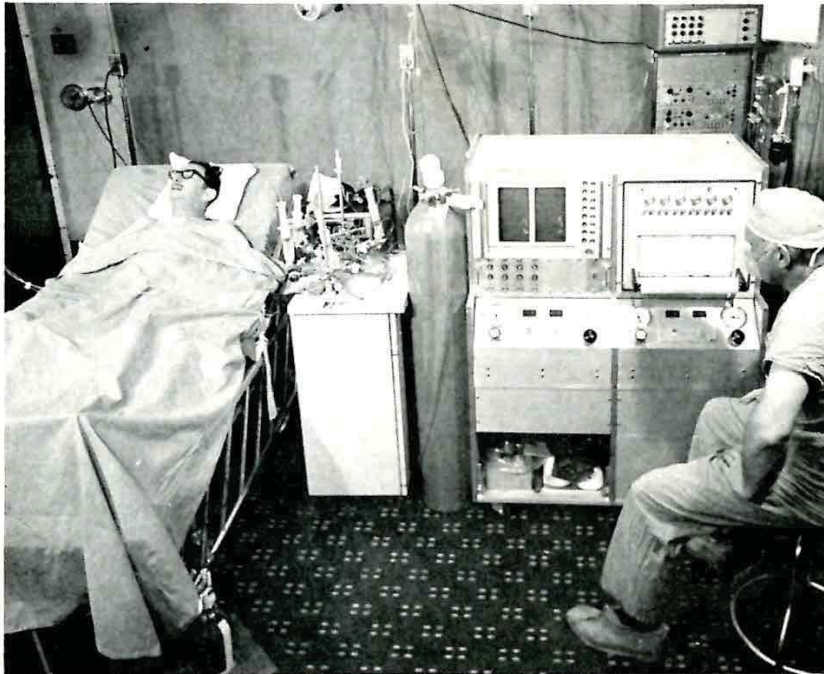
	Pressures (mm. Hg)		Systolic Duration (msec.)
	Systolic	Diastolic	
Left ventricle	105-110	-20	290
Right ventricle	45-50	-20	350

Occasional adjustments of the pressure in the pneumatic system were necessary to maintain atrial pressure in a range of 10 to 20 mm. Hg. During the entire postoperative period right and left atrial and radial arterial pressures were recorded, and chamber blood pressure in the right prosthetic ventricle was recorded as evidence of pulmonary arterial pressure.

#### CASE REPORT

A 47 year old man was admitted to The Texas Heart Institute on March 5, 1969, with advanced

coron  
block  
exper  
A sec  
was  
rhyth  
ischi  
synco  
sertec  
decor  
regim  
captu

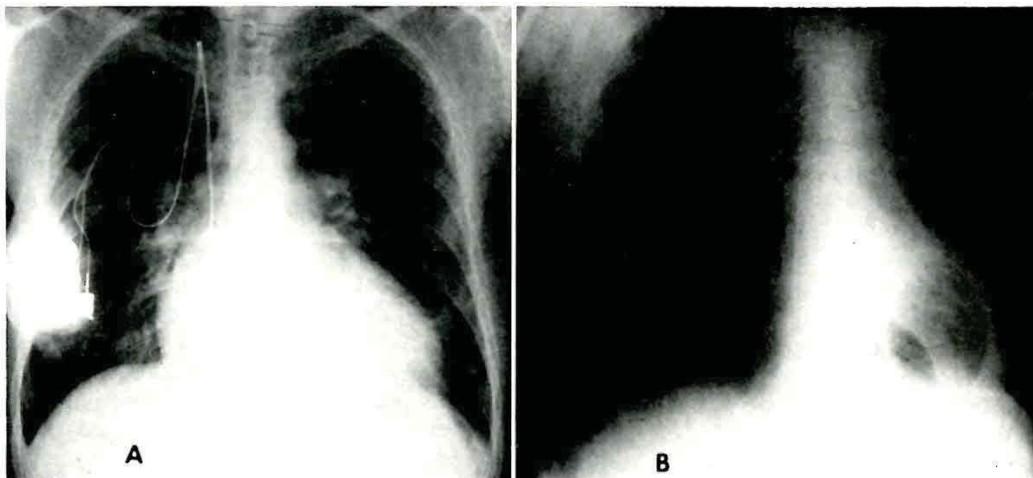


**Figure 2.** Photograph of control console and manometers more than 48 hours after insertion of orthotopic cardiac prosthesis and before cardiac allografting.

coronary arterial occlusive disease and complete heart block. Ten years previously, at age 37 years, he had experienced his first major myocardial infarction. A second infarction had occurred in 1966, and he was subsequently hospitalized five times with arrhythmias, congestive failure and acute myocardial ischemia. After three episodes of Stokes-Adams syncope a demand transvenous pacemaker was inserted in May 1968. In December 1968, cardiac decompensation prompted intensification of the drug regimen and an increase in pacemaker rate to capture completely the ventricular response. Anginal

pain and tachycardia occurred with minor exertion, and the patient was considered to be in functional class III bordering on class IV (New York Heart Association classification). His father had died of a myocardial infarction at age 57 years.

The patient was orthopneic and mildly dyspneic at rest. Blood pressure was 110/80 mm. Hg and the pulse was regular at 72 beats/min. synchronous with the pacemaker. The heart was moderately enlarged, and the pacemaker cartridge was palpable in the right pectoral region (Fig. 3). Crepitant pulmonary rales were present over the lower lobes.



**Figure 3.** Roentgenograms of the chest. **A**, before operation, showing cardiomegaly involving mostly the left ventricle, and intracardiac pacemaker with battery unit located subcutaneously in right pectoral fold. **B**, 36 hours after insertion of prosthesis, revealing unusually normal cardiac contour with double gas shadow indicating that the pumps were in systolic phase.

Table I. Function of Orthotopic Cardiac Prosthesis

Date & Time	HCT (%)	WBC (per cu. mm.)	Platelets (cu. mm.)	Plasma Hgb (mg. %)	BUN (mg. %)	Cardiac Output (L./min.)
4/4/69 8:00 A.M.	36			...	26	
4:00 P.M.	<i>Cardiac prosthesis functioning</i>					4.5*
6:00 P.M.	35	14,100	79,000	300	32	
4/5/69 6:00 A.M.	35	10,700	122,000	209	32	1.95†
6:00 P.M.	35	9,200	77,000	146	35	2.94‡
4/6/69 6:00 A.M.	36	9,900	66,000	52	30	
6:00 P.M.	35	2,700	55,000	32	60	
4/7/69 6:00 A.M.	35	3,200	60,000	...		
7:00 A.M.						5.2‡
8:00 A.M.	<i>Cardiac prosthesis discontinued</i>					
	36	5,400		65		
6:00 P.M.	38	2,850	70,000	130	70	
4/8/69 6:00 A.M.	40	4,600		87	65	
2:00 P.M.	<i>Patient died</i>					

\* Chest open, immediately after implantation of cardiac prosthesis. Determined by electromagnetic flowmeter.

† Start Arfonad drip.

‡ Change directly related to the use of Arfonad.

BUN = blood urea nitrogen; HCT = hematocrit; Hgb = hemoglobin; WBC = white blood cell count.

Complete atrioventricular block was identified in the electrocardiogram recorded on admission, and the ventricle was activated by the pacemaker impulse, thus obscuring any diagnostic configuration. Urinalysis, blood urea nitrogen and other blood chemistry determinations were normal. Blood type was O, Rh positive. Paradoxical expansion and delayed emptying of the left ventricle were seen by left ventricular angiogram. The left ventricular end-diastolic pressure was elevated to 25 mm. Hg. Pulmonary arterial pressure was 45/19 mm. Hg. Coronary arteriograms revealed severe narrowing of the right coronary artery 4 cm. beyond its origin; many collateral vessels, including one to the left coronary system; and complete occlusion of the anterior descending and left circumflex arteries, with small collateral arteries supplying the myocardium.

The patient was opposed to a cardiac transplantation, which was considered the operation of choice, and preferred a myocardial excision with ventriculoplasty—a procedure he knew of from news reports. After one month of intensive medical treatment without improvement, operation was performed.

#### FIRST SURGICAL PROCEDURE

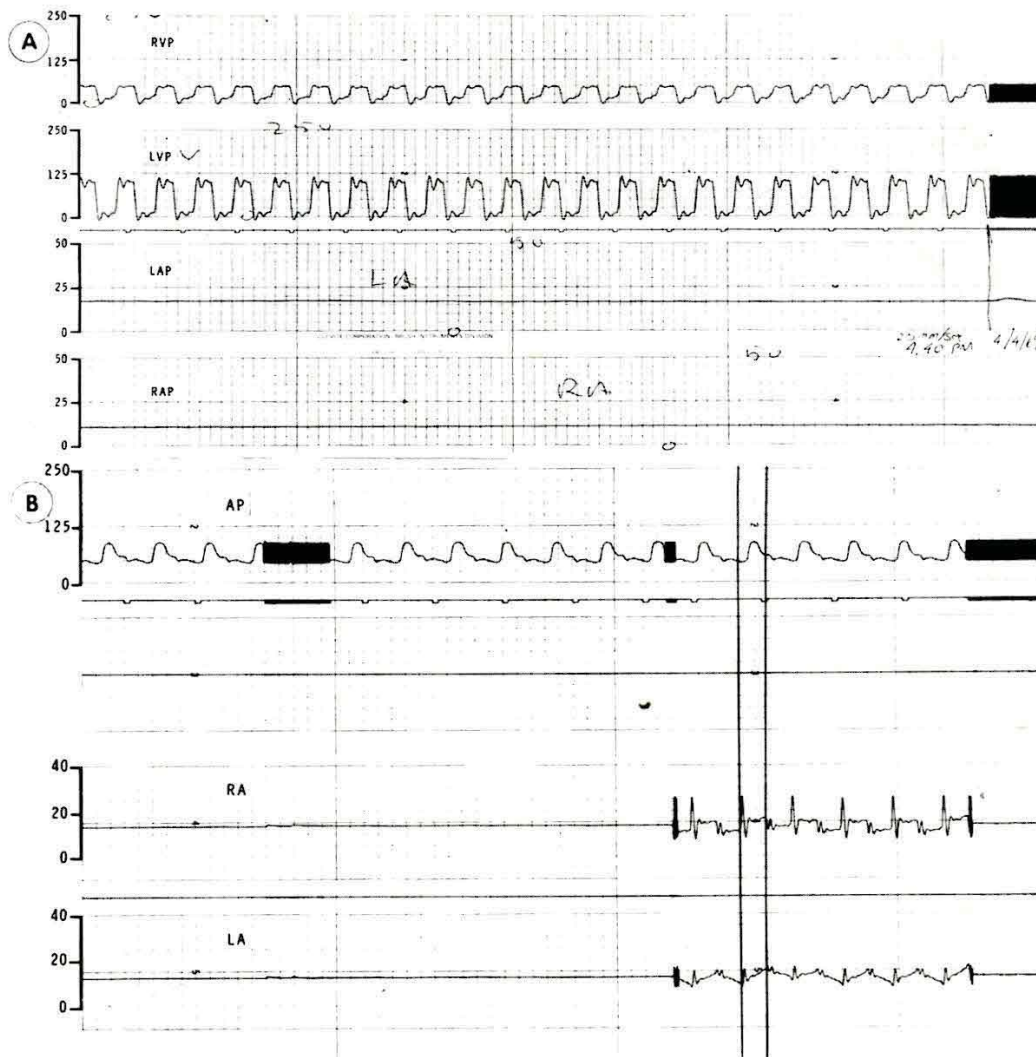
On April 4, 1969, the heart was exposed under general anesthesia by a median sternotomy incision. Cannulations were made for cardiopulmonary bypass using the superior and inferior venae cavae for venous outflow and the right femoral artery for return of oxygenated blood. A plastic disposable oxygenator primed with 5 per cent dextrose in water was used for extracorporeal circulation, and the patient was maintained normothermic.<sup>4,5</sup> Heparin was administered, 3.0 mg./kg. of body weight. With the ascending aorta clamped, extensive adhesions between the left ventri-

cle and pericardium were divided and the ventricle was incised. Little intact myocardium remained since scar tissue replaced over two-thirds of the left ventricular myocardium and almost the entire septum. An extensive area of fibrous transformation of the left ventricle and septum was excised and ventriculoplasty performed. Attempts at resuscitation of the heart failed, and cardiopulmonary bypass was continued while the heart was removed in the same manner used for cardiac transplantation.<sup>2,6</sup> The cardiac prosthesis was placed in the pericardial sac after the atrial cuffs and arterial grafts were trimmed and tailored to ensure proper fit. The left atrium, right atrium, main pulmonary artery and ascending aorta were sequentially anastomosed with the use of continuous suture technic with 2-0 and 3-0 Dacron. The CO<sub>2</sub> energizing tubes were directed through the thoracic cage and connected to the extracorporeal console control. As the venae cavae and ascending aorta were released, the prosthesis was activated and cardiopulmonary bypass discontinued. The caval and right femoral arterial cannulas were removed. The anticoagulant effect of heparin was counteracted with protamine sulfate, 4.5 mg./kg. of body weight. With the thoracic incision still open, and a 24 mm. electromagnetic flowmeter probe placed around the 25 mm. Dacron pulmonary artery, the output of the right ventricular pump was 4.5 L./min. The incision was closed with the usual intrathoracic drainage. The patient remained in the operating room, which was converted into an intensive care unit providing the necessary equipment for monitoring, respirator support and isolation.

#### POSTOPERATIVE COURSE

The patient regained consciousness within 15

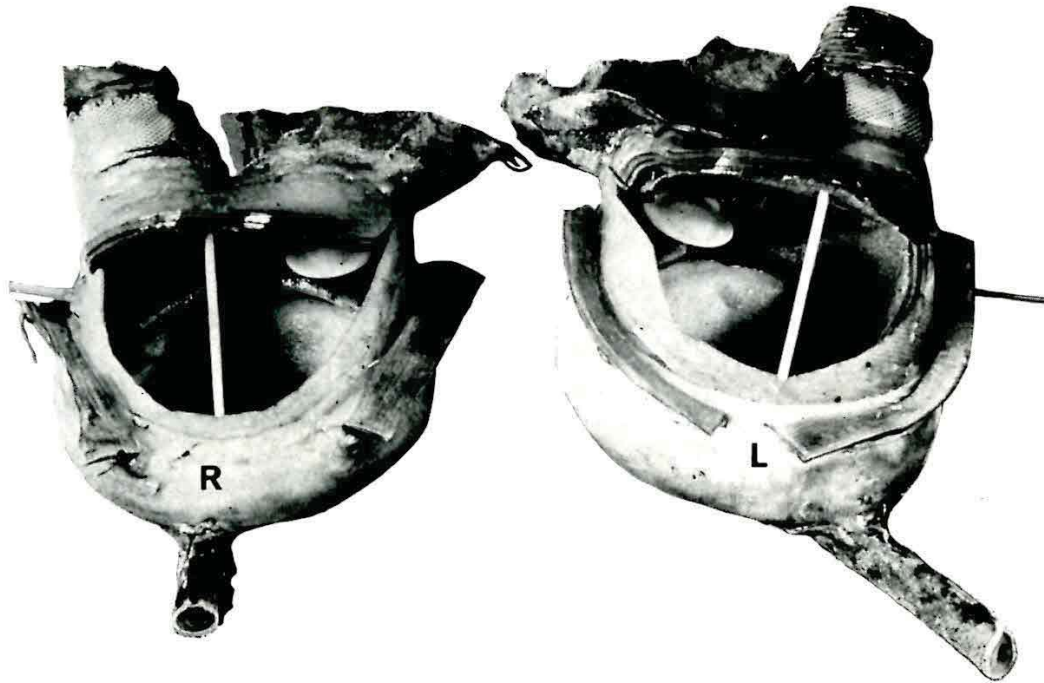
minu  
verba  
colore  
Plasm  
ensui  
prost  
plasm  
Soon  
open,  
press  
wavef  
appro  
some  
obtai  
ventri  
4B ill  
about



**Figure 4.** A, pressures (mm. Hg) measured on April 4, 1969, just after implantation of prosthesis with chest open. **From top to bottom:** right ventricular pressure, 50/0; left ventricular pressure, 120/0; left atrial pressure, 16; right atrial pressure, 10. B, pressures measured on April 7, 1969, just before removal of prosthesis and during administration of Arfonad. **From top to bottom:** radial pressure, 95/50; right atrial pressure, 14; left atrial pressure, 12.

minutes after the incision was closed. He responded to verbal commands and moved all limbs. Urine was colored with blood at the termination of bypass. Plasma hemoglobin was 300 mg. per cent. During the ensuing three days, while the orthotopic cardiac prosthesis was supporting circulation, the level of plasma hemoglobin steadily decreased (Table 1). Soon after implantation, with the patient's chest still open, right ventricular pressure and left ventricular pressure were measured. Figure 4A shows that the waveform of right and left ventricular pressures approximated the normal. The upslope during the isometric phase of left ventricular contraction was obtained by a fast activation of the left prosthetic ventricle during this period (60 to 70 msec.). Figure 4B illustrates the normal waveform of radial pressure about four hours before removal of the prosthesis.

At cardiac transplantation 64 hours later, plasma hemoglobin was 32 mg. per cent. Immunosuppressive drugs including azathioprine (Imuran®), prednisolone and antilymphocytic globulin were administered two hours after the operation in anticipation of the arrival of a suitable donor. During the three days after operation the patient received a total of 500 mg. of azathioprine. On April 6, 1969, the day preceding cardiac transplantation, leukopenia and moderate thrombocytopenia were evident, and the leukocyte count was 2,700/cu. mm. Urinary output decreased progressively during these three days despite intravenous administration of mannitol and fluids. Dialysis was not attempted because the patient did not have significant azotemia or acidosis. His temperature was normal, and no signs of pulmonary or surgical infection were noted.



**Figure 5.** Macroscopic photograph of prosthesis after removal showing both pumping chambers and all valves entirely free of thrombus.

On April 7, 1969, at 5:00 A.M., a 39 year old woman was admitted to the hospital with irreversible brain damage after a period of anoxic arrest 48 hours previously. After blood and tissue compatibility was established between donor and recipient, both patients were placed in adjoining operating rooms.

#### SECOND SURGICAL PROCEDURE

With the patient under general anesthesia, the sternotomy incision was reopened and the prosthesis exposed. The output of the right ventricle was determined by electromagnetic flowmeter as 5.21 L./min. *Cardiopulmonary bypass was instituted* by cannulating the inferior vena cava through the right common femoral vein and the superior vena cava through the cuff of right atrium. The patient was fully heparinized again. The right common femoral artery provided return of oxygenated blood. As the bypass was started, the external activator or energizing console was turned off. The prosthesis was removed from the pericardial cavity and replaced by the cardiac allograft by use of the technic described previously.<sup>2</sup>

Upon release of the clamp from the ascending aorta, coronary circulation was restored to the normothermic, unperfused allograft, and myocardial activity returned in ventricular fibrillation. Fibrillation was converted to sinus rhythm by direct current shock. With a slow infusion of a dilute solution of isoproterenol (Isuprel®), the allograft functioned well and maintained the systemic blood pressure at normal levels. The effect of heparin was counteracted with protamine sulfate. The thoracic incision was re-

paired, and the patient was kept in the same operating room for postoperative care.

#### POSTOPERATIVE COURSE

The patient regained consciousness within one hour of operation, and peripheral circulation was adequately maintained with a slow infusion of isoproterenol. Urinary output was scant, but blood chemistry determinations did not reveal serious evidence of azotemia or hyperkalemia. A roentgenogram of the chest taken several hours later showed a localized area of atelectasis or consolidation in the right lower pulmonary lobe. During the subsequent clinical course this area increased in size until, 32 hours later, the entire lower lung field on the right was consolidated, and cardiac action ceased.

#### PATHOLOGIC REPORTS

*Patient's Heart:* The heart without atria weighed 650 gm. and showed marked thinning of the apex of the left ventricle with focal calcification. The ventricular septum was densely fibrotic and almost devoid of myocardium. Fatty ingrowth was evident in these diseased areas as well as in the posterior myocardium. Both the right and left anterior descending coronary arteries were completely occluded by atherosclerotic debris. The left circumflex coronary artery was at least 50 per cent occluded, and all smaller vessels were partially occluded. Valves were intact and normal.

*Cardiac Prosthesis:* The interior surfaces of both the right and left pumping chambers were entirely free of thrombus as were the valves (Fig. 5). Sections of the walls of various chambers revealed deposition of

fibrin and coagulation. The examination of the autopsied patient revealed lower pulmonary consolidation, microscopic presence of a rejected microtubule, presence of the fibrin

O to the work co-w using et a parti cle 1 patie pum the c inflo



**Figure 6.** Microscopic photograph of fabric lining the body of the prosthetic pump showing a smooth internal lining with fibrin enmeshed in the fibers of Dacron.

fibrin with enmeshed erythrocytes between the fibers and on the surface of the material lining the prosthesis. The inner surface was smooth on microscopic examination (Fig. 6).

*Autopsy:* The right lung weighed 1,100 gm. compared to 580 gm. for the left. On cut section the right lower lobe exuded greenish purulent material from which pseudomonas was isolated. Necrotizing and confluent bronchopneumonia was seen in the microscopic sections of the lung. No unusual changes were present in the allograft except for moderate edema and stiffness, and there was no evidence of allograft rejection. The kidneys were grossly edematous, and microscopic examination showed scattered areas of tubular necrosis. A few scattered pigment casts were present, but no hemosiderin pigment was noted within the tubular epithelium. Many glomeruli contained fibrin within the glomerular tufts.

#### DISCUSSION

Outstanding contributions have been made to the field of total heart substitution by the work of Akutsu, Nosé and Kwan-Gett and their co-workers<sup>7-9</sup> in the experimental laboratory using a pulsatile flow mechanical device. Liotta et al.<sup>10</sup> recorded the first clinical attempt at partial functional replacement of the left ventricle using an implantable pump in a human patient. E. Stanley Crawford implanted this pump in his patient on July 19, 1963, inserting the device in parallel with the left ventricle. The inflow connector was inserted into the left

atrium and the outflow connector sutured to the descending thoracic aorta. DeBakey<sup>11</sup> also referred to the clinical use of this left ventricular bypass pump. The clinical employment of a device for circulatory assistance in series with the left ventricle was reported by Kantrowitz et al.<sup>12</sup>

The prosthesis used in this first clinical case of total cardiac replacement gave a commendable performance as a simple mechanical pump. When peripheral vascular resistance increased, the output of the prosthesis decreased as it had during previous in vitro testing. When the output of the prosthesis diminished as a result of a spontaneous increase in peripheral vascular resistance, Arfonad<sup>®</sup> was administered by intravenous infusion (Table 1). Cardiac output measured by Cardiogreen<sup>®</sup> dye-dilution technic increased from 1.95 to 2.94 L./min.—an increase of 50 per cent.<sup>3</sup> Although the numerical value of the cardiac output did not correspond with that determined at the second operation by electromagnetic flowmeter (5.2 L./min.), the comparative values are probably meaningful.

The success of an implantable cardiac substitute depends largely on finding a suitable inner lining material or blood-pump interface that is antithrombogenic and that causes minimal hemolysis. The lining used in this prosthesis was a reticular Dacron fabric. During function of the

prosthesis no thromboembolic complications were observed, and it was not necessary to use heparin or any other anticoagulant agents. The platelet count varied but remained in an adequate range, and no significant postoperative bleeding was detected. Plasma hemoglobin decreased from 300 mg. per cent at the end of the initial period of perfusion to 32 mg. per cent before removal of the prosthesis.<sup>3</sup> Since the plasma hemoglobin was maximal when cardiopulmonary bypass was completed after the first operation, the hemolysis may have been due to the bubble oxygenator. Another possibility, however, is that the hemolysis was related to the prosthesis and persisted until the inner surface of the pump was covered by a thin layer of fibrin, platelets and blood cells. Actually, the leukopenia noted may have been related to these factors, although the use of over 7 mg./kg. of body weight of azathioprine during the early stage of circulatory support probably produced the marrow depression later demonstrated by marrow biopsy.

Terminal renal failure was directly related to the tubular necrosis suspected clinically and proved at autopsy and probably resulted from the initial elevated plasma hemoglobin coupled with severe generalized vasoconstriction. The absence of hemorrhagic or necrotic foci in the brain or other vital organs was further evidence of the adequacy of the pump as a cardiac substitute.

#### REFERENCES

1. BARNARD, C. N. A human cardiac transplant: An interim report of a successful operation performed at Groote Schuur Hospital, Capetown. *South African M. J.*, 41:1271, 1967.
2. COOLEY, D. A., BLOODWELL, R. D., HALLMAN, G. L. and NORA, J. J. Transplantation of the human heart: Report of four cases, *J.A.M.A.*, 205:479, 1968.
3. COOLEY, D. A., LIOTTA, D., HALLMAN, G. L., BLOODWELL, R. D., LEACHMAN, R. D. and MILAM, J. D. First human implantation of cardiac prosthesis for staged total replacement of the heart. *Tr. Am. Soc. Artif. Int. Organs*, 15:252, 1969.
4. LIOTTA, D., TALIANI, T., GIFFONIELLO, A. H., DEHEZA, F. S., LIOTTA, D., LIZARRAGA, R., TOLOCKA, L., PANANO, J. and BIANCIOTTI, E. Artificial heart in the chest: Preliminary report. *Tr. Am. Soc. Artif. Int. Organs*, 7:318, 1961.
5. COOLEY, D. A., BEALL, A. C., JR. and GRONDIN, P. Open heart operations with disposable oxygenators, 5 per cent dextrose prime, and normothermia. *Surgery*, 52:713, 1962.
6. COOLEY, D. A., BLOODWELL, R. D., HALLMAN, G. L., LEACHMAN, R. D., NORA, J. J. and MILAM, J. D. Cardiac transplantation: General considerations and results. *Ann. Surg.*, 169:892, 1969.
7. AKUTSU, T., HOUSTON, C. S. and KOLFF, W. J. Artificial hearts inside the chest, using small electro-motors. *Tr. Am. Soc. Artif. Int. Organs*, 6: 299, 1960.
8. NOSÉ, Y., TOPAZ, S., SENGUPTA, A., TRETBAR, L. L. and KOLFF, W. J. Artificial hearts inside the pericardial sac in calves. *Tr. Am. Soc. Artif. Int. Organs*, 11:255, 1965.
9. KWAN-GETT, C. S., CROSBY, M. J., SCHOENBERG, A., JACOBSEN, S. C. and KOLFF, W. J. Control systems for artificial hearts. *Tr. Am. Soc. Artif. Int. Organs*, 14:284, 1968.
10. LIOTTA, D., HALL, C. W., HENLY, W. S., COOLEY, D. A., CRAWFORD, E. S. and DEBAKEY, M. E. Prolonged assisted circulation during and after cardiac or aortic surgery: Prolonged partial left ventricular bypass by means of intracorporeal circulation. *Am. J. Cardiol.*, 12:399, 1963.
11. DEBAKEY, M. E. Ricerche per un cuore artificiale. In: Scienze e Tecnica 69, Section II, Health: Social Aspects and Progress in Therapy, Part 9, p. 153. MACORINI, E., editorial director. Milan, Italy, 1968. Arnoldo Mondadori.
12. KANTROWITZ, A., AKUTSU, T., CHAPTAL, P. A., KRAKAUER, J. and JONES, R. T. A clinical experience with an implanted mechanical auxiliary ventricle. *J.A.M.A.*, 197:525, 1966.

E

IN  
suffi  
Mou  
Valv  
inter

Fi

tin  
be  
ho  
ver  
the  
org  
fur  
—  
reg

Se

the  
cer  
wh  
cat  
hea  
in  
clav  
pec  
car  
ma  
fullTh  
frequThe  
tha  
dise  
in t\*  
A