

Standard 5.5: Wide Local Excision for Primary Cutaneous Melanoma

Operation

Wide local excision for primary cutaneous melanoma

(excluding mucosal, ocular, and subungual melanomas)

Depth of excision

Invasive: skin + all underlying subcutaneous tissue down to the fascia
Melanoma in situ: skin + superficial subcutaneous fat

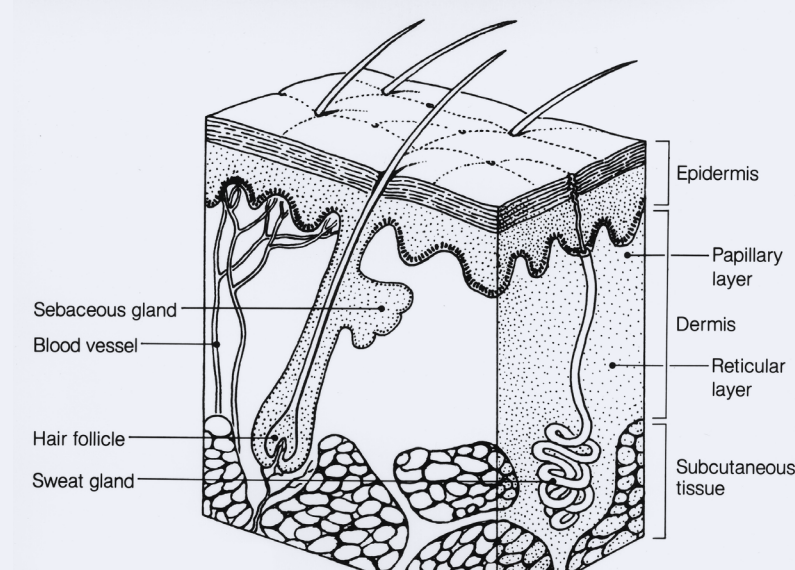
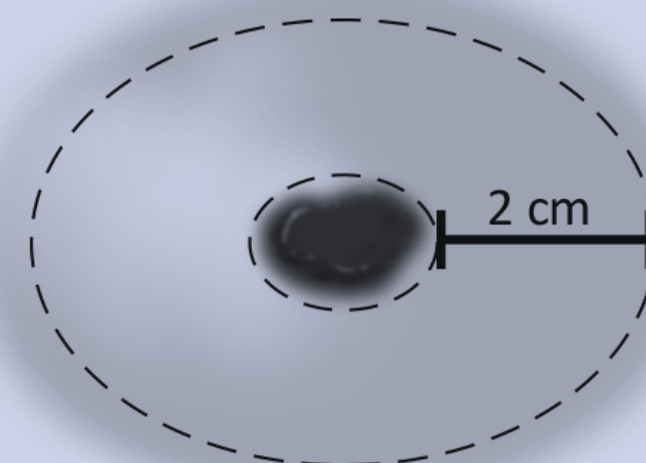


Image of skin layers from the National Cancer Institute. Used with permission.

Select **clinical margin width** based on original Breslow thickness



Breslow thickness	Margin
Melanoma in situ	>5 mm
Invasive <1 mm	1 cm
Invasive 1-2 mm	1-2 cm
Invasive >2 mm	2 cm

Documentation

Required elements/ responses in synoptic format



- Curative intent
- Original Breslow thickness of the lesion
- Clinical margin width (measured from edge of lesion or prior excision scar)
- Depth of excision

Timeline

2022

Document final plan for implementation

2023

Standard 5.5 takes full effect

2024

Site visits begin reviewing synoptic operative reports