

**ajcc**

**Cancer Staging  
Manual**

*Sixth Edition*

# AJCC CANCER STAGING MANUAL

Sixth Edition

Please visit [www.cancerstaging.net](http://www.cancerstaging.net) for related product information for the *AJCC Cancer Staging Manual*, including coding updates and important clarifications to the chapters on Purposes and Principles of Staging, Cancer of the Lip and Oral Cavity, Soft Tissue Sarcoma, and Retinoblastoma.

## EDITORS

FREDERICK L. GREENE, M.D.  
Chair, Department of General Surgery  
Carolinas Medical Center  
Charlotte, North Carolina

DAVID L. PAGE, M.D.  
Professor of Pathology and Epidemiology  
Vanderbilt University Medical Center  
Nashville, Tennessee

IRVIN D. FLEMING, M.D.  
Professor, Department of Surgery  
University of Tennessee Health Science Center  
Memphis, Tennessee

APRIL G. FRITZ, C.T.R., R.H.I.T.  
Division of Cancer Control and Population Sciences  
National Cancer Institute  
Bethesda, Maryland

CHARLES M. BALCH, M.D.  
Professor of Surgery and Oncology  
The Johns Hopkins School of Medicine  
Baltimore, Maryland

DANIEL G. HALLER, M.D.  
Professor of Medicine  
Associate Chief for Clinical Affairs  
University of Pennsylvania Health System  
Philadelphia, Pennsylvania

MONICA MORROW, M.D.  
Professor of Surgery and Director, Lynn Sage Breast Center  
Northwestern University  
School of Medicine  
Chicago, Illinois



# AJCC CANCER STAGING MANUAL

Sixth Edition

AMERICAN JOINT COMMITTEE ON CANCER

Executive Office  
633 North Saint Clair Street  
Chicago, Illinois 60611

FOUNDING ORGANIZATIONS

American Cancer Society  
American College of Physicians  
American College of Radiology  
American College of Surgeons  
College of American Pathologists  
National Cancer Institute

SPONSORING ORGANIZATIONS

American Cancer Society  
American College of Surgeons  
American Society of Clinical Oncology  
Centers for Disease Control and Prevention

LIAISON ORGANIZATIONS

American Urological Association  
Association of American Cancer Institutes  
National Cancer Registrars Association  
North American Association of Central Cancer Registries  
American Society of Colon and Rectal Surgeons  
Society of Gynecologic Oncologists  
Society of Urologic Oncology

*This manual was prepared and published through the support of the American Cancer Society, the American College of Surgeons, the American Society of Clinical Oncology, the Centers for Disease Control and Prevention, and the International Union Against Cancer.*

 Springer



CD-ROM  
Included

American Joint Committee on Cancer  
Executive Office  
633 North Saint Clair Street  
Chicago, IL 60611, USA

*Editors:*

Frederick L. Greene, M.D.	Charles M. Balch, M.D.
David L. Page, M.D.	Daniel G. Haller, M.D.
Irvin D. Fleming, M.D.	Monica Morrow, M.D.
April G. Fritz, C.T.R., R.H.I.T.	

*Cover illustration:* Joan Greenfield, Good Design Resource, 2001.

Library of Congress Cataloging-in-Publication Data  
AJCC cancer staging manual.—6th ed. / editors, Frederick L. Greene ... [et al].  
p. ; cm.

Includes bibliographical references and index.

ISBN 0-387-95271-3 (Softcover: alk. paper)

1. Tumors—Staging—Handbooks, manuals, etc. I. Title: Cancer Staging Manual.

II. Greene, Frederick L. III. American Joint Committee on Cancer. IV. American Cancer Society.

[DNLM: 1. Neoplasm Staging. 2. Neoplasms—classification. QZ 241 A312 2002]

RC258. M36 2002

616.99'4'0012-dc21

2001053058

Printed on acid-free paper.

First to Fifth Editions of the *AJCC Cancer Staging Manual*, published by Lippincott Raven Publishers, Philadelphia, PA.

Sixth Edition © 2002 American Joint Committee on Cancer. All rights reserved. The *AJCC Cancer Staging Manual* is the Official Publication of the American Joint Committee on Cancer.

This book consists of a printed book and a CD-ROM packaged with the book, both of which are protected by federal copyright law and international treaty. The book, except for the Staging Forms, may not be translated or copied in whole or in part without the written permission of the publisher (Springer-Verlag New York, Inc., 175 Fifth Avenue, New York, NY 10010, USA), or the copyright holder, except for brief excerpts in connection with reviews or scholarly analysis. For copyright information regarding the CD-ROM, please consult the printed information packaged with the CD-ROM in the back of this publication. Use in connection with any form of information storage and retrieval, electronic adaptation, computer software, or by similar or dissimilar methodology now known or hereafter developed is forbidden.

The Staging Forms may be reproduced or used for institutional or individual purposes.

Materials appearing in this book prepared by individuals as part of their official duties as U.S. Government employees are not covered by the above-mentioned copyright.

The use in this publication of trade names, trademarks, service marks, and similar terms, even if they are not identified as such, is not to be taken as an expression of opinion as to whether or not they are subject to proprietary rights.

While the advice and information in this book are believed to be true and accurate at the date of going to press, neither the authors nor the editors nor the publisher nor the AJCC can accept any legal responsibility for any errors or omissions that may be made. The publisher makes no warranty, express or implied, with respect to the material contained therein.

The following figures have been reproduced from the *TNM Atlas*, Fourth Edition, P. Hermanek, R. Hutter, L.H. Sobin, and C. Wittekind, Editors, © 1999 Springer-Verlag New York, Inc.: 15.1, 15.2, 16.1, 17.1, 18.1, 33.1, 33.2, 33.3, 33.4, 33.5, 35.1, 35.2, 35.3, 36.1, 36.2, 37.1, 37.2, 38.1, 39.1, and 39.2.

The Staging Form illustrations for the Head and Neck sites, the Gynecologic sites, the Colon and Rectum, Anal Canal and Liver chapters were prepared by Alice Y. Chen.

ISBN 0-387-95271-3

Printed on acid-free paper.

Printed in the United States of America

(IMP/EB)

9 8 7 6 5 4

springeronline.com



## SIXTH EDITION

Dedicated to Robert V.P. Hutter, M.D.

## FIFTH EDITION

Dedicated to Oliver Howard Beahrs, M.D.

## FOURTH EDITION

Dedicated to the memory of Harvey Baker, M.D.

## THIRD EDITION

Dedicated to the memory of W.A.D. Anderson, M.D.  
Marvin Pollard, M.D.  
Paul Sherlock, M.D.

## SECOND EDITION

Dedicated to the memory of Murray M. Copeland, M.D.

## Sixth Edition Dedication

The AJCC Cancer Staging Manual, Sixth Edition, is dedicated to Robert V.P. Hutter, M.D., noted pathologist and leader over many decades in the coordinated effort to achieve worldwide staging utilizing the TNM system. Bob Hutter was born in Yonkers, New York, and received his M.D. from the State University of New York Health Science Center at Syracuse. After completing his pathology residency at Yale University, Dr. Hutter worked as an American Cancer Society Clinical Fellow and as Chief Resident in Pathology at Memorial Hospital for Cancer and Allied Disease in New York. He remained on the faculty at Memorial Hospital from 1961 to 1965 and then joined the pathology faculty at Yale University for the next 5 years. Dr. Hutter served as Chief of the Pathology Services at the College of Medicine and Dentistry of New Jersey from 1970 to 1973. He became the Chairman of the Department of Pathology at Saint Barnabas Medical Center in 1974 and has continued his illustrious career at that institution until the present time.

Bob Hutter has received many awards for his work in the cancer field. He was recognized as Physician of the Year by the New Jersey Division of the American Cancer Society and received an honorary fellowship from the American College of Radiology. His work in organizations dedicated to cancer has been outstanding. Dr. Hutter served as National President of the American Cancer Society in 1981–1982 and received the St. George Medal for Outstanding Service to the American Cancer Society in 1990. The AJCC has benefited

for many years from Dr. Hutter's wisdom. As Chairman of the American Joint Committee on Cancer from 1985 to 1990, Dr. Hutter, in his usual quiet and efficient way, coordinated the effort with the UICC to make TNM staging a worldwide language. His Presidential Address to the combined meeting of the Society of Surgical Oncology and the British Association of Surgical Oncology in 1987 highlighted the significant achievements in the development of a common language of cancer staging. Dr. Hutter has continued to be a voice of reason and wisdom on the AJCC as well as the TNM Committee of the UICC. As the Editor-in-Chief of *Cancer* for 10 years, he has taken a leadership role in promoting the educational concepts of staging and in fostering the changing clinical relevance of staging through the promulgation of important studies in that leading peer-reviewed journal.

For all of these contributions and for the continued influence and leadership that Dr. Hutter brings to the treatment of patients with cancer worldwide, the editors of the Sixth Edition of the *AJCC Cancer Staging Manual* are proud and honored to dedicate this work to him.

Frederick L. Greene, M.D.  
David L. Page, M.D.  
Irvin D. Fleming, M.D.  
April G. Fritz, C.T.R., R.H.I.T.

Charles M. Balch, M.D.  
Daniel G. Haller, M.D.  
Monica Morrow, M.D.

*Editors*  
March 2002



## Preface

For more than four decades the American Joint Committee on Cancer (AJCC) has played a leadership role in the United States as the organization that provides oversight of cancer staging for most solid tumors seen in clinical practice. Since the creation of the first series of Cancer Staging Manuals in 1977, hundreds of committed clinicians and dedicated staff have joined and combined their efforts to establish a well-defined system of cancer staging that would reflect the concepts of diagnosis and pathological identification of cancer. The primary work of critically reviewing staging using the TNM system has been undertaken by task forces made up of experts in the clinical, statistical, and registration areas. These groups have met and reviewed end-results data in order to obtain information that would utilize new concepts that further elaborate upon the basic tenets of the TNM system. Colleagues representing the International Union Against Cancer (UICC) have worked diligently to ensure that the Sixth Edition of the *AJCC Cancer Staging Manual* reflects the uniformity and worldwide staging agreements realized in the late 1980s.

The Sixth Edition of the *AJCC Cancer Staging Manual* is built upon the work of countless individuals who have recognized the importance of having a well-defined and reproducible cancer staging system built on tumor, node, and metastatic findings. This system was developed in the 1940s by Pierre Denoix of France and was embraced by the UICC in the 1950s when a Committee on Clinical Stage Classification and Applied Statistics was developed to “pursue studies to extend the general technique of classification to cancer at all sites.” Since the mid-1980s, worldwide agreement for cancer staging has culminated in the simultaneous publication of the *TNM Classification of Malignant Tumours* by the UICC and of the *Cancer Staging Manual* by the AJCC. Although these two organizations have goals that extend beyond tumor classification, it is this common ground created by the support of TNM staging that has fostered an atmosphere of scholarly work and discussions related to the taxonomy of cancer.

Beginning in 2000, task force groups were formed and chaired by eminent clinicians in their respective fields. In addition, a group devoted to statistical issues was formed to

coordinate the work of individual statisticians on each task force. This group also formulated appropriate concepts to be utilized in evaluating data and scholarly submissions dealing with each cancer site. The work of our statisticians has been invaluable and, it is hoped, will be a paradigm for future editions.

A major change for the Sixth Edition has been the alliance with a new publisher. Our colleagues at Springer-Verlag, especially Laura Gillan, Jenny Wolkowicki, and Carol Wang have worked tirelessly along with the Editorial Board and AJCC staff to create a cancer staging manual that presents the state of the art in the staging of cancer. The newly revised format of the Staging Forms can be readily *printed* from the CD-ROM, thus making them easy to use and reader-friendly. It is our wish that the manual will serve as a benchmark for further publishing ventures that have been created through the Internet, CD-ROMs, and other exciting new methods of information transfer and dissemination.

The creation of this Sixth Edition could not have been possible without the dedication of the talented staff of the AJCC in Chicago. Special thanks go to past Executive Director, Monica Morrow, M.D., JoAnne Sylvester, Connie Blankenship, Lynda Douglas, Susan Burkhardt, and Kelly Poirier. The editors of the Sixth Edition salute all of our colleagues who have joined together to create in the Sixth Edition of the *AJCC Cancer Staging Manual*, a volume that will serve as a worthy addition to the important literature on cancer staging, developed during the last five decades. What started as an ambitious and daring undertaking in the earlier years, has now become an indispensable resource for many healthcare professionals. The clarity of vision expressed in the earlier editions is certainly carried through in the Sixth Edition of the *AJCC Cancer Staging Manual*.

Frederick L. Greene, M.D.  
David L. Page, M.D.  
Irvin D. Fleming, M.D.  
April G. Fritz, C.T.R., R.H.I.T.

Charles M. Balch, M.D.  
Daniel G. Haller, M.D.  
Monica Morrow, M.D.

*Editors*  
*March 2002*



# Brief Contents by Part

<b>Part I</b> .....	<b>1</b>
General Information on Cancer Staging and End-Results Reporting / 1	
<b>Part II</b> .....	<b>2</b>
Head and Neck Sites / 17	
<b>Part III</b> .....	<b>3</b>
Digestive System / 89	
<b>Part IV</b> .....	<b>4</b>
Thorax / 165	
<b>Part V</b> .....	<b>5</b>
Musculoskeletal Sites / 185	
<b>Part VI</b> .....	<b>6</b>
Skin / 201	
<b>Part VII</b> .....	<b>7</b>
Breast / 221	
<b>Part VIII</b> .....	<b>8</b>
Gynecologic Sites / 241	
<b>Part IX</b> .....	<b>9</b>
Genitourinary Sites / 301	
<b>Part X</b> .....	<b>10</b>
Ophthalmic Sites / 347	
<b>Part XI</b> .....	<b>11</b>
Central Nervous System / 385	
<b>Part XII</b> .....	<b>12</b>
Lymphoid Neoplasms / 391	
<b>Part XIII</b> .....	<b>13</b>
Personnel and Contributors / 407	





# Contents

Preface .....	vii	<b>Part IV .....</b>	<b>165</b>
Brief Contents by Part.....	ix	<b>Thorax</b>	
<b>Part I .....</b>	<b>1</b>	19. Lung .....	167
<b>General Information on Cancer Staging and End-Results Reporting</b>		20. Pleural Mesothelioma.....	179
1. Purposes and Principles of Staging.....	3	<b>Part V .....</b>	<b>185</b>
2. Cancer Survival Analysis.....	9	<b>Musculoskeletal Sites</b>	
<b>Part II .....</b>	<b>17</b>	21. Bone .....	187
<b>Head and Neck Sites</b>		22. Soft Tissue Sarcoma .....	193
<i>Introduction</i> .....	17	<b>Part VI .....</b>	<b>201</b>
3. Lip and Oral Cavity .....	23	<b>Skin</b>	
4. Pharynx ( <i>Including Base of Tongue, Soft Palate, and Uvula</i> ).....	33	23. Carcinoma of the Skin ( <i>Excluding Eyelid, Vulva, and Penis</i> ).....	203
5. Larynx.....	47	24. Melanoma of the Skin.....	209
6. Nasal Cavity and Paranasal Sinuses .....	59	<b>Part VII .....</b>	<b>221</b>
7. Major Salivary Glands ( <i>Parotid, Submandibular, and Sublingual</i> ).....	69	<b>Breast</b>	
8. Thyroid.....	77	25. Breast.....	223
<b>Part III .....</b>	<b>89</b>	<b>Part VIII .....</b>	<b>241</b>
<b>Digestive System</b>		<b>Gynecologic Sites</b>	
9. Esophagus .....	91	<i>Introduction</i> .....	241
10. Stomach.....	99	26. Vulva .....	243
11. Small Intestine.....	107	27. Vagina.....	251
12. Colon and Rectum.....	113	28. Cervix Uteri.....	259
13. Anal Canal .....	125	29. Corpus Uteri .....	267
14. Liver ( <i>Including Intrahepatic Bile Ducts</i> ).....	131	30. Ovary.....	275
15. Gallbladder.....	139	31. Fallopian Tube.....	285
16. Extrahepatic Bile Ducts .....	145	32. Gestational Trophoblastic Tumors .....	293
17. Ampulla of Vater .....	151		
18. Exocrine Pancreas .....	157		

**Part IX .....301**  
**Genitourinary Sites**

33. Penis ..... 303  
34. Prostate ..... 309  
35. Testis ..... 317  
36. Kidney ..... 323  
37. Renal Pelvis and Ureter ..... 329  
38. Urinary Bladder ..... 335  
39. Urethra ..... 341

**Part X .....347**  
**Ophthalmic Sites**

40. Carcinoma of the Eyelid ..... 349  
41. Carcinoma of the Conjunctiva ..... 355  
42. Malignant Melanoma of the Conjunctiva..... 361  
43. Malignant Melanoma of the Uvea ..... 365

44. Retinoblastoma ..... 371  
45. Carcinoma of the Lacrimal Gland ..... 377  
46. Sarcoma of the Orbit..... 381

**Part XI .....385**  
**Central Nervous System**

47. Brain and Spinal Cord..... 387

**Part XII .....391**  
**Lymphoid Neoplasms**

48. Lymphoid Neoplasms..... 393

**Part XIII .....407**  
**Personnel and Contributors**

**Index.....417**



# Introduction and Historical Overview

The Sixth Edition of the *AJCC Cancer Staging Manual* is a compendium of all currently available information on the staging of cancer for most clinically important anatomic sites. It has been developed by the American Joint Committee on Cancer (AJCC) in cooperation with the TNM Committee of the International Union Against Cancer (UICC). The two organizations have worked together at every level to create a staging schema that remains uniform throughout. The current climate that allows for a consistency of staging worldwide has been made possible by the mutual respect and diligence of those working in the staging area for both the AJCC and the UICC.

Classification and staging of cancer enable the physician and cancer registrar to stratify patients, which will lead to better treatment decisions and the development of a common language that will aid in the creation of clinical trials for the future testing of cancer treatment strategies. A common language of cancer staging is mandatory in order to realize the important contributions from many institutions throughout the world. This need for appropriate nomenclature was the driving force that led to clinical classification of cancer by the League of Nations Health Organization in 1929 and later by the UICC and its TNM Committee.

The AJCC was first organized on January 9, 1959, as the American Joint Committee for Cancer Staging and End-Results Reporting (AJC). The driving force behind the organization of this body was a desire to develop a system of clinical staging for cancer that was acceptable to the American medical profession. The founding organizations of the AJCC are the American College of Surgeons, the American College of Radiology, the College of American Pathologists, the American College of Physicians, the American Cancer Society, and the National Cancer Institute. The governance of the AJCC is represented by designees from the founding organizations. In addition, sponsoring organizations represented by the American Cancer Society, the American Society of Clinical Oncology, the Centers for Disease Control and Prevention and the American College of Surgeons has served effectively as the administrative sponsor of the AJCC, and the Medical Director of the Commission on Cancer functions as the Executive Director of the AJCC. Fostering the work of

the AJCC has been undertaken by subcommittees called task forces, which have been established along specific anatomic sites of cancer. In preparation for each new edition of the *Cancer Staging Manual*, the task forces are convened and serve as consensus panels to review scholarly material related to cancer staging and make recommendations to the AJCC regarding potential changes in the staging taxonomy.

During the last 45 years of activity related to the AJCC, a large group of consultants and liaison organization representatives have worked with the AJCC leadership. These representatives have been selected by the American Society of Clinical Oncology, the Centers for Disease Control and Prevention, the American Urological Association, the Association of American Cancer Institutes, the National Cancer Registrars Association, the Society of Gynecologic Oncologists, the Society of Urologic Oncology, the SEER Program of the NCI, the North American Association of Central Cancer Registries (NAACCR), and the American Society of Colon and Rectal Surgeons.

Chairing the AJCC have been Murray Copeland, M.D. (1959–1969), W.A.D. Anderson, M.D. (1969–1974), Oliver H. Beahrs, M.D. (1974–1979), David T. Carr, M.D. (1979–1982), Harvey W. Baker, M.D. (1982–1985), Robert V.P. Hutter, M.D. (1985–1990), Donald E. Henson, M.D. (1990–1995), Irvin D. Fleming, M.D. (1995–2000), and currently Frederick L. Greene, M.D.

The initial work on the clinical classification of cancer was instituted by the League of Nations Health Organization (1929), the International Commission on Stage Grouping and Presentation of Results (ICPR) of the International Congress of Radiology (1953), and the International Union Against Cancer (UICC). The latter organization became most active in the field through its Committee on Clinical Stage Classification and Applied Statistics (1954). This committee was later known as the UICC TNM Committee, which now includes the Chairman of the AJCC.

Since its inception, the AJCC has embraced the TNM system in order to describe the anatomic extent of cancer at the time of initial diagnosis and before the application of definitive treatment. In addition, a classification of the stages of cancer was utilized as a guide for treatment and prognosis

and for comparison of the end results of cancer management. In 1976 the AJCC sponsored a National Cancer Conference on Classification and Staging. The deliberation at this conference led directly to the development of the First Edition of the *Cancer Staging Manual*, which was published in 1977. With the publication of the First Edition, the AJCC broadened its scope by recognizing its leadership role in the staging of cancer for American physicians and registrars. The Second Edition of the manual (1983) updated the earlier edition and included additional sites. This edition also served to enhance conformity with the staging espoused by the TNM Committee of the UICC.

The expanding role of the American Joint Committee in a variety of cancer classifications suggested that the original name was no longer applicable. In June 1980 the new name, the American Joint Committee on Cancer, was selected. Since the early 1980s, the close collaboration of the AJCC and the UICC has resulted in uniform and identical definitions and stage groupings of cancers for all anatomic sites so that a universal system is now available. This worldwide sys-

tem was espoused by Robert V. P. Hutter, M.D., in his Presidential Address at the combined meeting of the Society of Surgical Oncology and the British Association of Surgical Oncology in London in 1987.

During the 1990s, the importance of TNM staging of cancer in the United States was heightened by the mandatory requirement that Commission on Cancer approved hospitals use the AJCC-TNM system as the major language for cancer reporting. This requirement has stimulated education of all physicians and registrars in utilization of the TNM system, and credit goes to the Approvals Program of the Commission on Cancer for this insightful recognition. The AJCC recognizes that with this Sixth Edition of the *Cancer Staging Manual*, a goal for the education of medical students, resident physicians, physicians in practice, and cancer registrars is paramount. As the 21st century unfolds, new methods of education will complement the Sixth Edition of the *AJCC Cancer Staging Manual* and will ensure that all those who care for cancer patients will be trained in the language of cancer staging.

AMERICAN JOINT COMMITTEE ON CANCER

AJCC  
CANCER STAGING  
MANUAL

Sixth Edition



**PART I**  
**General Information  
on Cancer Staging  
and End-Results  
Reporting**

# Purposes and Principles of Staging

## PHILOSOPHY OF CLASSIFICATION AND STAGING BY THE TNM SYSTEM

A clinically useful classification scheme for cancer must encompass the attributes of the tumor that define its behavior. The American Joint Committee on Cancer (AJCC) classification is based on the premise that cancers of the same anatomic site and histology share similar patterns of growth and similar outcomes.

As the size of the untreated primary cancer (T) increases, regional lymph node involvement (N) and/or distant metastasis (M) become more frequent. A simple classification scheme, which can be incorporated into a form for staging and can be universally applied, is the goal of the TNM system as proposed by the AJCC. This classification is identical to that of the *International Union Against Cancer* (UICC).

The three significant events in the life history of a cancer—local tumor growth (T), spread to regional lymph nodes (N), and metastasis (M)—are used as they appear (or do not appear) on clinical examination, before definitive therapy begins, to indicate the anatomic extent of the cancer. This shorthand method of indicating the extent of disease (TNM) at a particular designated time is an expression of the stage of the cancer at that time in its progression.

Spread to regional lymph nodes and/or distant metastasis occur before they are discernible by clinical examination. Thus, examination during the surgical procedure and histologic examination of the surgically removed tissues may identify significant additional indicators of the prognosis of the patient (T, N, and M) as different from what could be discerned clinically before therapy. Because this is the pathologic (pTNM) classification and stage grouping (based on examination of a surgically resected specimen with sufficient tissue to evaluate the highest T, N, or M classification), it is recorded in addition to the clinical classification. It does not replace the clinical classification. Both should be maintained in the patient's permanent medical record. The clinical stage is used as a guide to the selection of primary therapy. The pathologic stage can be used as a guide to the need for adjuvant therapy, to estimation of prognosis, and to reporting end results.

Therapeutic procedures, even if not curative, may alter the course and life history of a cancer patient. Although cancers that recur after therapy may be staged with the same criteria that are used in pretreatment clinical staging, the significance of these criteria may not be the same. Hence, the "restage" classification of recurrent cancer (rTNM) is considered separately for therapeutic guidance, estimation

of prognosis, and end-results reporting at that time in the patient's clinical course.

The significance of the criteria for defining anatomic extent of disease differs for tumors at different anatomic sites and of different histologic types. Therefore, the criteria for T, N, and M must be defined for tumors of each anatomic site to attain validity. With certain types of tumors, such as Hodgkin's disease and lymphomas, a different system for designating the extent of the disease and its prognosis, and for classifying its stage grouping, is necessary to achieve validity. In these exceptional circumstances, other symbols or descriptive criteria are used in place of T, N, and M.

The combination of the T, N, and M classifications into stage groupings is thus a method of designating the anatomic extent of a cancer and is related to the natural history of the particular type of cancer. It is intended to provide a means by which this information can readily be communicated to others, to assist in therapeutic decisions, and to help estimate prognosis. Ultimately, it provides a mechanism for comparing similar groups of patients when evaluating different potential therapies.

For most cancer sites, the staging recommendations in this manual are concerned only with the anatomic extent of disease, but in several instances, histologic grade (soft-tissue sarcoma) and age (thyroid carcinoma) are factors that significantly influence prognosis and must be considered. In the future, biologic markers or genetic mutations may have to be included along with those of anatomic extent in classifying cancer, but at present they are supplements to, and not necessarily components of, the TNM stage based on anatomic extent of the cancer.

In addition to anatomic extent, the histologic type and histologic grade of the tumor may be important prognostic determinants in the classification for staging. These factors are also important variables affecting choices of treatment. For sarcomas, the tumor grade may prove to be the most important variable.

*Philosophy of changes:* The introduction of new types of therapeutic interventions or new technologies may require modification of the classification and staging systems. These dynamic processes may alter treatment and outcomes. It is essential to recognize the kinetics of change of staging systems. However, changes in the staging system make it difficult to compare outcomes of current therapy with those of past treatment. Because of this, changes to the staging system must be undertaken with caution. In this edition, only factors validated in multiple large studies have been incorporated into the staging system.

## NOMENCLATURE OF THE MORPHOLOGY OF CANCER

Cancer therapy decisions are made after an assessment of the patient and the tumor, using many methods that often include sophisticated technical procedures. For most types of cancer, the anatomic extent to which the disease has spread is probably the most important factor determining prognosis and must be given prime consideration in evaluating and comparing different therapeutic regimens.

Staging classifications are based on documentation of the anatomic extent of disease, and their design requires a thorough knowledge of the natural history of each type of cancer. Such knowledge has been and continues to be derived primarily from morphologic studies, which also provide us with the definitions and classifications of tumor types.

No acceptable staging system has yet been developed for primary tumors of the central nervous system. Pediatric tumors are not included in this manual.

An accurate histologic diagnosis, therefore, is an essential element in a meaningful evaluation of the tumor. In certain types of cancer, biochemical, molecular, genetic, or immunologic measurements of normal or abnormal cellular function have become important elements in classifying tumors precisely. Increasingly, definitions and classifications should include function as a component of the pathologist's anatomic diagnosis. One may also anticipate that special techniques such as immunohistochemistry, cytogenetics, and molecular markers will be used more routinely for characterizing tumors and their behavior.

The most comprehensive and best-known English-language compendium of the macroscopic and microscopic characteristics of tumors and their associated behavior is the *Atlas of Tumor Pathology* series, published in many volumes by the Armed Forces Institute of Pathology in Washington, DC. These are revised periodically and are used as a basic reference by pathologists throughout the world.

## RELATED CLASSIFICATIONS

Since 1958 the World Health Organization (WHO) has had a program aimed at providing internationally acceptable criteria for the histologic classification of tumors of various anatomic sites. This has resulted in the *International Histological Classification of Tumours*, which contains, in an illustrated 25-volume series, definitions, descriptions, and multiple illustrations of tumor types and proposed nomenclature.

The WHO *International Classification of Diseases for Oncology* (ICD-O), Third Edition, is a numerical coding system for neoplasms by topography and morphology. The coded morphology nomenclature is identical to the morphology field for neoplasms in the *Systematized Nomenclature of Medicine* (SNOMED) published by the College of American Pathologists.

In the interest of promoting national and international collaboration in cancer research, and specifically to facilitate

appropriate comparison of data among different clinical investigations, use of the *International Histological Classification of Tumours* for classification and definition of tumor types, and use of the ICD-O codes for storage and retrieval of data, are recommended.

## BIBLIOGRAPHY

- Atlas of tumor pathology, 3rd series. Washington, DC: Armed Forces Institute of Pathology, 1991–2002
- International Union Against Cancer (UICC): prognostic factors in cancer, 2nd ed. Gospodarowicz MK, Henson DE, Hutter RVP, O'Sullivan B, Sobin LH, Wittekind Ch (Eds.). New York: Wiley-Liss, 2001
- International Union Against Cancer (UICC) TNM supplement: a commentary on uniform use, 2nd ed. Wittekind Ch, Henson DE, Hutter RVP, Sobin LH (Eds.). New York: Wiley-Liss, 2001
- World Health Organization: ICD-O International classification of diseases for oncology, 3rd ed. Geneva: WHO, 2000
- World Health Organization: International histological classification of tumours, 2nd ed. Berlin-Heidelberg-New York: Springer-Verlag, 1988–1997

## GENERAL RULES FOR STAGING OF CANCER

The practice of dividing cancer cases into groups according to stage arose from the observation that survival rates were higher for cases in which the disease was localized than for those in which the disease had extended beyond the organ or site of origin. These groups were often referred to as "early cases" and "late cases," implying some regular progression with time. Actually, the stage of disease at the time of diagnosis may be a reflection not only of the rate of growth and extension of the neoplasm, but also of the type of tumor and of the tumor-host relationship.

The staging of cancer is used to analyze and compare groups of patients. It is preferable to reach agreement on the recording of accurate information about the anatomic extent of the disease for each site, because the precise clinical description and histopathologic classification of malignant neoplasms may serve a number of related objectives, such as (1) selection of primary and adjuvant therapy, (2) estimation of prognosis, (3) assistance in evaluation of the results of treatment, (4) facilitation of the exchange of information among treatment centers, and (5) contribution to the continuing investigation of human cancers.

The principal purpose served by international agreement on the classification of cancer cases by anatomic extent of disease, however, is to provide a method of conveying clinical experience to others without ambiguity.

There are many classification schemes: the clinical and pathologic anatomic extent of disease; the reported duration of symptoms or signs; the sex and age of the patient; and the histologic type and grade. All of these represent variables that are known to affect or can predict the outcome of the patient. Classification by anatomic extent of disease as determined



clinically and histopathologically (when possible) is the classification to which the attention of the AJCC and the UICC is primarily directed.

The clinician's immediate task is to select the most effective course of treatment and estimate the prognosis. This decision and this judgment require, among other things, an objective assessment of the anatomic extent of the disease.

To meet these stated objectives, a system of classification is needed that (1) has basic principles applicable to all anatomic sites regardless of treatment, and (2) allows the clinical appraisal to be supplemented by later information derived from surgery, histopathology, and other staging studies. The TNM system fulfills these requirements.

### GENERAL RULES OF THE TNM SYSTEM

The TNM system is an expression of the anatomic extent of disease and is based on the assessment of three components:

- T The extent of the primary tumor
- N The absence or presence and extent of regional lymph node metastasis
- M The absence or presence of distant metastasis

The use of numerical subsets of the TNM components indicates the progressive extent of the malignant disease.

- T0, T1, T2, T3, T4
- N0, N1, N2, N3
- M0, M1

In effect, the system is a shorthand notation for describing the clinical and pathologic anatomic extent of a particular malignant tumor. The following general rules apply to all sites.

1. All cases should use the following time guidelines for evaluating stage: through the first course of surgery or 4 months, whichever is longer.
2. All cases should be confirmed microscopically for TNM classification (including clinical classification). Rare cases that do not have biopsy or cytology of the tumor can be staged but should be analyzed separately and should not be included in survival analyses.
3. Four classifications are described for each site:
  - **Clinical classification**, designated cTNM or TNM
  - **Pathologic classification**, designated pTNM
  - **Retreatment classification**, designated rTNM
  - **Autopsy classification**, designated aTNM

**Clinical classification** is based on evidence acquired before primary treatment. Clinical assessment uses information available prior to first definitive treatment, including but not limited to physical examination, imaging, endoscopy, biopsy, and surgical exploration. Clinical stage is assigned prior to any cancer-directed treatment and is not changed on the ba-

sis of subsequent information. Clinical staging ends if a decision is made not to treat the patient. The clinical stage is essential to selecting and evaluating primary therapy.

**Pathologic classification** uses the evidence acquired before treatment, supplemented or modified by the additional evidence acquired during and from surgery, particularly from pathologic examination. The pathologic stage provides additional precise data used for estimating prognosis and calculating end results.

- The pathologic assessment of the primary tumor (pT) entails resection of the primary tumor sufficient to evaluate the highest pT category and, with several partial removals, may necessitate an effort at reasonable reconstruction to approximate the native size prior to manipulation.
- The complete pathologic assessment of the regional lymph nodes (pN) ideally entails removal of a sufficient number of lymph nodes to evaluate the highest pN category.

*Exception:* Sentinel node assessment may be appropriate for some sites and is clarified in chapter guidelines for those sites.\*

\**Note:* The sentinel lymph node is the first lymph node to receive lymphatic drainage from a primary tumor. If it contains metastatic tumor, this indicates that other lymph nodes may contain tumor. If it does not contain metastatic tumor, other lymph nodes are not likely to contain tumor. Occasionally there is more than one sentinel lymph node.

- If pathologic assessment of lymph nodes reveals negative nodes but the number of examined lymph nodes is less than the suggested number for lymph node dissection, classify the N category as pN0.
- Isolated tumor cells (ITC) are single tumor cells or small clusters of cells not more than 0.2 mm in greatest dimension that are usually detected by immunohistochemistry or molecular methods. Cases with ITC in lymph nodes or at distant sites should be classified as N0 or M0, respectively. The same applies to cases with findings suggestive of tumor cells or their components by nonmorphologic techniques such as flow cytometry or DNA analysis. These cases should be analyzed separately and have special recording rules in the specific organ site.
- The pathologic assessment of metastases may be either clinical or pathologic when the T and/or N categories meet the criteria for pathologic staging (pT, pN, cM, or pM).

Pathologic classification of the extent of the primary tumor (T) and lymph nodes (N) is essential. Pathologic staging depends on the proven anatomic extent of disease, whether or not the primary lesion has been completely removed. If a

biopsied primary tumor technically cannot be removed, or when it is unreasonable to remove it, and if the highest T and N categories or the M1 category of the tumor can be confirmed microscopically, the criteria for pathologic classification and staging have been satisfied without total removal of the primary cancer.

**Retreatment classification** is assigned when further treatment (such as chemotherapy) is planned for a cancer that recurs after a disease-free interval. All information available at the time of retreatment should be used in determining the stage of the recurrent tumor (rTNM). Biopsy confirmation of the recurrent cancer is useful if clinically feasible, but with pathologic proof of the primary site, clinical evidence of distant metastases (usually by radiographic or related methodologies) may be used.

**Autopsy classification** occurs when classification of a cancer by postmortem examination is done after the death of a patient (cancer was not evident prior to death). The classification of the stage is identified as aTNM and includes all pathologic information obtained at the time of death.

4. **Stage grouping.** After the assignment of cT, cN, and cM and/or pT, pN, and pM categories, these may be grouped into stages. Both TNM classifications and stage groupings, once established, remain in the medical record. If there is doubt concerning the T, N, or M classification to which a particular case should be assigned, then the lower (less advanced) category should be assigned. The same principle applies to the stage grouping. Carcinoma *in situ* (CIS) is an exception to the stage grouping guidelines. By definition, CIS has not involved any structures in the primary organ that would allow tumor cells to spread to regional nodes or distant sites. Therefore, pTis, cN0, cM0, clinical stage group 0 is appropriate.
5. **Multiple tumors.** In the case of multiple, simultaneous tumors in one organ, the tumor with the highest T category is the one selected for classification and staging, and the multiplicity or the number of tumors is indicated in parentheses: for example, T2(m) or T2(5). For simultaneous bilateral cancers in paired organs, the tumors are classified separately as independent tumors in different organs. In the case of tumors of the thyroid, liver, and ovary, multiplicity is a criterion of T classification.
6. **Subsets of TNM.** Definitions of TNM categories and stage grouping may be telescoped (expanded as subsets of existing classifications) for research purposes as long as the original definitions are not changed. For instance, any of the published T, N, or M classifications can be divided into subgroups for testing and, if validated, may be submitted to the American Joint Committee on Cancer or the TNM Process Subcommittee of the UICC to be evaluated for inclusion in the classification system.

7. **Unknown primary.** In the case of a primary of unknown origin, staging can only be based on clinical suspicion of the primary origin (e.g., T0 N1 M0).

## ANATOMIC REGIONS AND SITES

The sites in this classification are listed by code number of the *International Classification of Diseases for Oncology*, Third Edition (ICD-O Third Edition, World Health Organization, 2000). Most chapters are constructed according to the following outline:

Introduction

Anatomy

Primary site

Regional lymph nodes

Metastatic sites

Rules for classification

Clinical (TNM or cTNM)

Pathologic (pTNM)

Definitions of TNM for each specific anatomic site

T: Primary tumor size/extent

N: Regional lymph node involvement: number/extent

M: Distant metastasis absent/present

Stage grouping

Histopathologic type

Histologic grade

## DEFINITIONS OF TNM

### Primary Tumor (T)

TX	Primary tumor cannot be assessed
T0	No evidence of primary tumor
Tis	Carcinoma <i>in situ</i>
T1, T2, T3, T4	Increasing size and/or local extent of the primary tumor

### Regional Lymph Nodes (N)

NX	Regional lymph nodes cannot be assessed
N0	No regional lymph node metastasis
N1, N2, N3	Increasing involvement of regional lymph nodes

*Note:* Direct extension of the primary tumor into a lymph node(s) is classified as a lymph node metastasis.

*Note:* Metastasis in any lymph node other than regional is classified as a distant metastasis.

### Distant Metastasis (M)

MX	Distant metastasis cannot be assessed
M0	No distant metastasis
M1	Distant metastasis

*Note:* For pathologic stage grouping, if sufficient tissue to evaluate the highest T and N categories has been removed

for pathologic examination, M1 may be either clinical (cM1) or pathologic (pM1). If only a metastasis has had microscopic confirmation, the classification is pathologic (pM1) and the stage is pathologic.

The category M1 may be further specified according to the following notation:

Pulmonary	PUL
Osseous	OSS
Hepatic	HEP
Brain	BRA
Lymph nodes	LYM
Bone marrow	MAR
Pleura	PLE
Peritoneum	PER
Adrenals	ADR
Skin	SKI
Other	OTH

**Subdivisions of TNM.** Subdivisions of some main categories are available for those who need greater specificity (e.g., T1a, 1b or N2a, 2b as with breast and prostate).

## HISTOPATHOLOGIC TYPE

The histopathologic type is a *qualitative* assessment whereby a tumor is categorized (typed) according to the normal tissue type or cell type it most closely resembles (e.g., hepatocellular or cholangiocarcinoma, osteosarcoma, squamous cell carcinoma). In general, the *World Health Organization International Histological Classification of Tumours* published in numerous anatomic site-specific editions, may be used for histopathologic typing. A list of applicable ICD-0-3 histopathologic codes, including numerical codes and alpha names, is presented at the end of each chapter following the bibliography. If a specific histology is not listed, the case cannot be staged using the AJCC classification in that chapter.

## HISTOLOGIC GRADE (G)

The histologic grade is a qualitative assessment of the differentiation of the tumor expressed as the extent to which a tumor resembles the normal tissue at that site. Grade is expressed in numerical grades of differentiation from most differentiated (Grade 1) to least differentiated (Grade 4), e.g., squamous cell carcinoma, moderately differentiated, Grade 2. The term *grade* is also used when other predictive, tissue-based parameters are used for prediction, particularly nuclear grade and mitotic count.

GX	Grade cannot be assessed
G1	Well differentiated
G2	Moderately differentiated
G3	Poorly differentiated
G4	Undifferentiated

Other grading systems are in development with more precise guidelines adding features of nuclear grade and mitotic activity to the evaluation of tissue differentiation. If there is evidence of more than one grade or of differentiation of the tumor, the least differentiated is recorded as the histopathologic grade, using only G2 through G4. For example, a colonic adenocarcinoma that is partially well differentiated and partially moderately differentiated is coded as grade 2 (G2). The growing edge of a tumor is not generally assessed in grading because it may appear to be a high grade—except in breast, where that is the best reflection of prognosis.

For some anatomic sites, Grade 3 and Grade 4 are combined into a single grade—for example, poorly differentiated to undifferentiated (G3–4). The combination is valid for carcinomas of the uterine corpus, ovary, prostate, urinary bladder, kidney, renal pelvis, ureter, urethra, and breast. Only three grades are used for melanoma of the conjunctiva and uvea. Grading does not apply to carcinomas of the thyroid, eyelids, and retinoblastoma or to malignant testicular tumors and melanoma of the skin.

The use of G4 is reserved for those tumors that show no specific differentiation that would identify the cancer as arising from its site of origin. In some sites, the WHO histologic classification includes undifferentiated carcinomas—for example, in the stomach or gallbladder. In these cases, the tumor is graded as undifferentiated (G4).

Some histologic tumor types are by definition listed as G4 for staging purposes and are not to be assigned a grade of undifferentiated in ICD-O-3 coding for cancer registry purposes. These include

- Small cell carcinoma, any site
- Large cell carcinoma of lung
- Ewing's sarcoma of bone and soft tissue
- Rhabdomyosarcoma of soft tissue

Traditionally, and as discussed above, histologic stratification of solid tumors has been dominated by concerns of differentiation. Other systems have validated more complex stratifications, using other data and demonstrating different patient outcomes for three tiers supported by histologic schemes of evaluation that include relatively valid and validated criteria. In this edition, the grading systems proposed for prostate and breast cancers are in the latter group. Although manifestly different, they have been multiply validated. One uses patterns of differentiation, cellularity, and invasiveness (prostate); the other uses nuclear grading (shape and size of nuclei) and formal counts of mitotic figures as a reflection of the proliferation rate. It is clear and relevant that these systems have taken advantage of the very different natural histories of cancers in these two organs.

## DESCRIPTORS

For identification of special cases of TNM or pTNM classifications, the m suffix and “y,” “r,” and “a” prefixes are used.

Although they do not affect the stage grouping, they indicate cases that require separate analysis.

**m Suffix.** Indicates the presence of multiple primary tumors in a single site and is recorded in parentheses: pT(m)NM.

**y Prefix.** Indicates those cases in which classification is performed during or following initial multimodality therapy. The cTNM or pTNM category is identified by a “y” prefix. The ycTNM or ypTNM categorizes the extent of tumor actually present at the time of that examination. The “y” categorization is not an estimate of the extent of tumor prior to multimodality therapy.

**r Prefix.** Indicates a recurrent tumor when staged after a disease-free interval, and is identified by the “r” prefix: rTNM. (See reclassification, r above as rTNM).

**a Prefix.** Designates the stage determined at autopsy: aTNM.

## OTHER DESCRIPTORS

### *Lymphatic Vessel Invasion (L)*

- LX Lymphatic vessel invasion cannot be assessed
- L0 No lymphatic vessel invasion
- L1 Lymphatic vessel invasion

### *Venous Invasion (V)*

- VX Venous invasion cannot be assessed
- V0 No venous invasion
- V1 Microscopic venous invasion
- V2 Macroscopic venous invasion

### *Residual Tumor (R)*

The absence or presence of residual tumor after treatment is described by the symbol R.

TNM and pTNM describe the anatomic extent of cancer in general without consideration of treatment. TNM and pTNM can be supplemented by the R classification, which deals with the tumor status after treatment. It reflects the effects of therapy, influences further therapeutic procedures, and is a strong predictor of prognosis.

The R categories are

- RX Presence of residual tumor cannot be assessed
- R0 No residual tumor
- R1 Microscopic residual tumor
- R2 Macroscopic residual tumor

## STAGE GROUPING

Classification by the TNM system achieves reasonably precise description and recording of the anatomic extent of disease. A tumor with 4 categories of T, 3 categories of N, and 2 categories of M has 24 TNM combinations. For purposes of tabulation and analysis, except in very large series, it is necessary to condense these combinations into a convenient number of TNM stage groupings.

The grouping adopted ensures, as far as possible, that each stage group is relatively homogeneous with respect to survival and that the survival rates of these stage groupings for each cancer site are distinct. Carcinoma *in situ* is categorized Stage 0; for most sites, a case with distant metastasis is categorized Stage IV. Stages I, II, and III indicate relatively greater anatomic extent of cancer within the range from Stage 0 to Stage IV.

**Cancer Staging Data Form.** Each site chapter includes staging forms to be used to record the TNM classification and the stage of the cancer. The specific anatomic site of the cancer is recorded, as well as the histologic type and grade. The appropriate staging basis or classification must be recorded, such as at the time of primary therapy or at the time of recurrence. If a cancer is staged at several points, a separate form is used for each or if all are recorded in a single form, the staging basis for each, is clearly identified.

The T, N, and M classifications can be checked opposite the appropriate definitions of the extent of the primary tumor, the regional lymph nodes, and distant metastasis. The lesion(s) can be marked on a diagram, and finally, the stage grouping can be checked. In some instances, information regarding other characteristics of the tumor (not included in the stage) might be requested. These data may be pertinent in deciding management of the patient.

The cancer staging form is a specific additional document in the patient record indicating anatomic extent of disease. It is not a substitute for history, treatment, or follow-up records. The data forms in this manual may be duplicated for individual or institutional use without permission from the AJCC or the publisher.

# Cancer Survival Analysis

Analyses of cancer survival data and related outcomes are quantitative tools commonly used to assess cancer treatment programs and to monitor the progress of regional and national cancer control programs. In this chapter the most common survival analysis methodology will be illustrated, basic terminology will be defined, and the essential elements of data collection and reporting will be described. Although the underlying principles are applicable to both, the focus of this discussion will be on the use of survival analysis to describe data typically available in cancer registries rather than to analyze research data obtained from clinical trials or laboratory experimentation. Discussion of statistical principles and methodology will be limited. Persons interested in statistical underpinnings or research applications are referred to textbooks that explore these topics at length (Cox and Oakes, 1984; Fleming and Harrington, 1991; Kalbfleisch and Prentice, 1980; Kleinbaum, 1996; Lee, 1992).

## BASIC CONCEPTS

A *survival rate* is a statistical index that summarizes the probable frequency of specific outcomes for a group of patients at a particular point in time. A *survival curve* is a summary display of the pattern of survival rates over time. The basic concept is simple. For example, for a certain category of patient, one might ask what proportion are likely to be alive at the end of a specified interval, such as 5 years. The greater the proportion surviving, the more effective the program. Survival analysis, however, is somewhat more complicated than it first might appear. If one were to measure the length of time between diagnosis and death or record the vital status when last observed for every patient in a selected patient group, one might be tempted to describe the survival of the group as the proportion alive at the end of the period under investigation. This simple measure will be informative, however, only if all of the patients were observed for the same length of time.

In most real situations, it is not the case that all members of the group are observed for the same amount of time. Patients diagnosed near the end of the study period are more likely to be alive at last contact and will have been followed for less time than those diagnosed earlier. Even though it was not possible to follow these persons as long as the others, their survival might eventually have proved to be just as long or longer. Another difficulty is that it usually is not possible to know the outcome status of all of the persons who were in the group at the beginning. People move or change names and are lost to follow-up. Some of these persons may have

died and others could be still living. Thus, if a survival rate is to describe the outcomes for an entire group accurately, there must be some means to deal with the fact that different persons in the group are observed for different lengths of time and that for others, their vital status is not known at the time of analysis. In the language of survival analysis, subjects who are observed until they reach the endpoint of interest (e.g., death) are called *uncensored* cases, and those who survive beyond the end of the follow-up or who are lost to follow-up at some point are termed *censored* cases.

Two basic survival procedures that enable one to determine overall group survival, taking into account both censored and uncensored observations, are the life table method (Berkson and Gage, 1950) and the Kaplan-Meier method (Kaplan and Meier, 1958). The life table method was the first method generally used to describe cancer survival results, and it came to be known as the actuarial method because of its similarity to the work done by actuaries in the insurance industry. The specific method of computation, i.e., *life table* or Kaplan-Meier, should always be indicated to avoid any confusion associated with the use of less precise terminology. Rates computed by different methods are not directly comparable, and when the survival experiences of different patient groups are compared, the different rates must be computed by the same method.

The illustrations in this chapter are based on data obtained from the public-use files of the National Cancer Institute Surveillance, Epidemiology, and End Results (SEER) program. The cases selected are a 1% random sample of the total number for the selected sites and years of diagnosis. Follow-up of these patients continued through the end of 1999. Thus, for the earliest patients, there can be as much as 16 years of follow-up, but for those diagnosed at the end of the study period, there can be as little as 1 year of follow-up. These data are used both because they are realistic in terms of the actual survival rates they yield and because they encompass a number of cases that might be seen in a single large tumor registry over a comparable number of years. They are intended only to illustrate the methodology. SEER results from 1973 to 1997 are more fully described elsewhere (Ries et al., 2000) and these illustrations should not be regarded as an adequate description of the total or current United States patterns of breast or lung cancer survival.

## THE LIFE TABLE METHOD

The life table method involves dividing the total period over which a group is observed into fixed intervals, usually

months or years. For each interval, the proportion surviving to the end of the interval is calculated on the basis of the number known to have experienced the endpoint event (e.g., death) during the interval and the number estimated to have been at risk at the start of the interval. For each succeeding interval, a cumulative survival rate may be calculated. The cumulative survival rate is the probability of surviving the most recent interval multiplied by the probabilities of surviving all of the prior intervals. Thus, if the percent of the patients surviving the first interval is 90% and is the same for the second and third intervals, the cumulative survival percentage is 72.9% ( $.9 \times .9 \times .9 = .729$ ).

Results from the life table method for calculating survival for the breast cancer illustration are shown in Figure 2.1. Two thousand eight hundred nineteen (2,819) patients diagnosed between 1983 and 1998 were followed through 1999. Following the life table calculation method for each year after diagnosis, the 1-year survival rate is 95.6%. The 5-year cumulative survival rate is 76.8%. At 10 years, the cumulative survival is 61.0%.

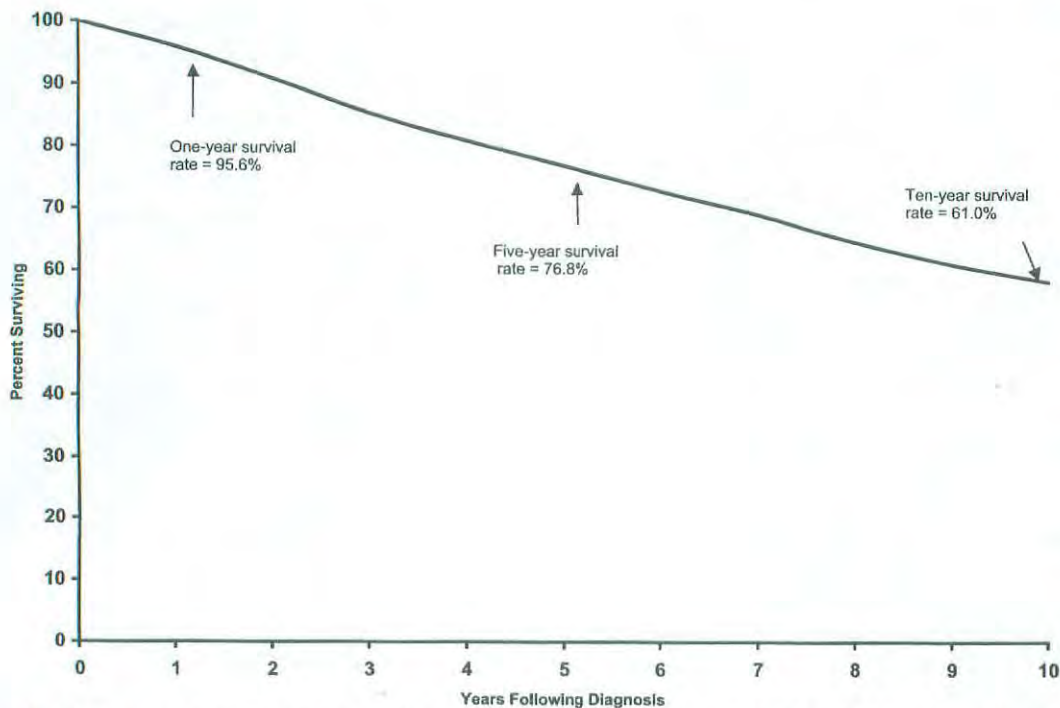
The lung cancer data show a much different survival pattern (Fig. 2.2). At 1 year following diagnosis, the survival rate is only 41.8%. By 5 years it has fallen to 12.0%, and only 6.8% of lung cancer patients are estimated to have survived for 10 years following diagnosis. For lung cancer patients the *median survival time* is 10.0 months. Median survival time is the amount of time required to pass so that half the patients have experienced the endpoint event and half the patients remain event-free. If the cumulative survival does not fall below 50% it is not possible to estimate median survival from the data, as is the case in the breast cancer data.

In the case of breast cancer, the 10-year survival rate is important because such a large proportion of patients live more than 5 years past their diagnosis. The 10-year time frame for lung cancer is less meaningful because such a large proportion of this patient group dies well before that much time passes.

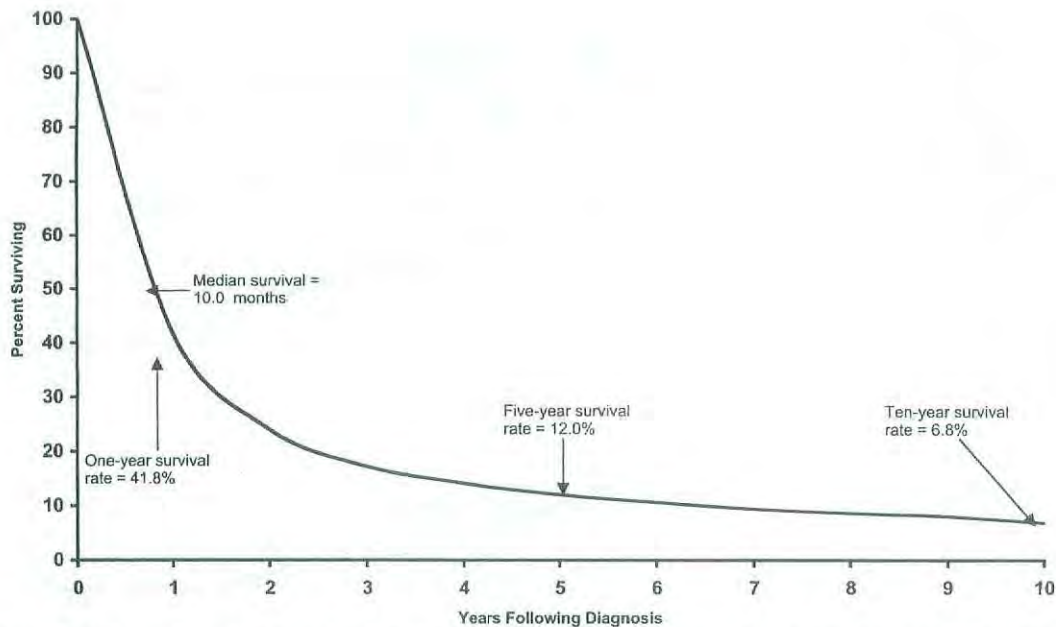
An important assumption of all actuarial survival methods is that censored cases do not differ from the entire collection of uncensored cases in any systematic manner that would affect their survival. For example, if the more recently diagnosed cases in Figure 2.1, i.e., those who were most likely not to have died yet, tended to be detected with earlier-stage disease than the uncensored cases; or if they were treated differently, the assumption about comparability of censored and uncensored cases would not be met, and the result for the group as a whole would be inaccurate. Thus it is important, when patients are included in a life table analysis, that one be reasonably confident that differences in the amount of information available about survival are not related to differences that might affect survival.

## THE KAPLAN-MEIER METHOD

These same data can be analyzed using the Kaplan-Meier method (Kaplan and Meier, 1958). It is similar to the life table method but provides for calculating the proportion surviving to each point in time that a death occurs, rather than at fixed intervals. The principal difference evident in a survival curve is that the stepwise changes in the cumulative



**FIG 2.1.** Survival of 2,819 breast cancer patients from the Surveillance, Epidemiology, and End Results Program of the National Cancer Institute, 1983–1998. Calculated by the life table method.



**FIG 2.2.** Survival of 2,347 lung cancer patients from the Surveillance, Epidemiology, and End Results Program of the National Cancer Institute, 1983–1998. Calculated by the life table method.

survival rate appear to occur independently of the intervals on the Years Following Diagnosis axis.

### PATIENT-, DISEASE-, AND TREATMENT-SPECIFIC SURVIVAL

Although overall group survival is informative, comparisons of the overall survival between two groups often are confounded by differences in the patients, their tumors, or the treatments they received. For example, it would be misleading to compare the overall survival depicted in Figure 2.1 with the overall survival of other breast cancer patients who tend to be diagnosed with more advanced disease, whose survival would be presumed to be poorer. The simplest approach to accounting for possible differences between groups is to provide survival results that are specific to the categories of patient, disease, or treatment that may affect results. In most cancer applications the most important variable by which survival results should be subdivided is the stage of disease. Figure 2.3 shows the *stage-specific* 5-year survival curves of the same breast cancer patients described earlier. These data show that breast cancer patient survival differs markedly according to the stage of the tumor at the time of diagnosis.

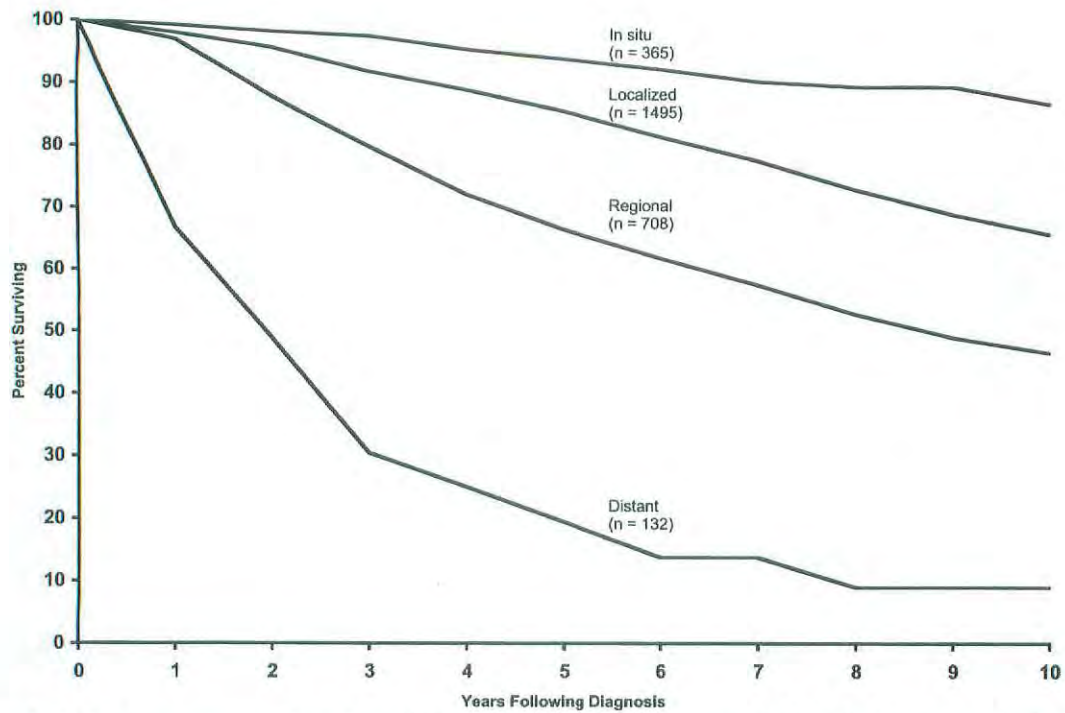
Almost any variable can be used to subclassify survival rates, but some are more meaningful than others. For example, it would be possible to provide season-of-diagnosis-specific (i.e., spring, summer, winter, fall) survival rates, but the season of diagnosis probably has no biologic association with the length of a breast cancer patient’s survival. On the other hand, the race-specific and age-specific survival rates shown in Figures 2.4 and 2.5 suggest that both of these vari-

ables are related to breast cancer survival. Whites have the highest survival rates and African-Americans the lowest. In the case of age, these data suggest that only the oldest patients experience poor survival and that it would be helpful to consider the effects of other causes of death that affect older persons using adjustments to be described.

Although the factors that affect survival may be unique to each type of cancer, it has become conventional that a basic description of survival for a specific cancer should include stage, age, and race-specific survival results. Treatment is a factor by which survival is commonly subdivided but it must be kept in mind that selection of treatment is usually related to some other factors which exert influence on survival. For example, in cancer care the choice of treatment is often dependent on the stage of disease at diagnosis.

### ADJUSTED SURVIVAL RATE

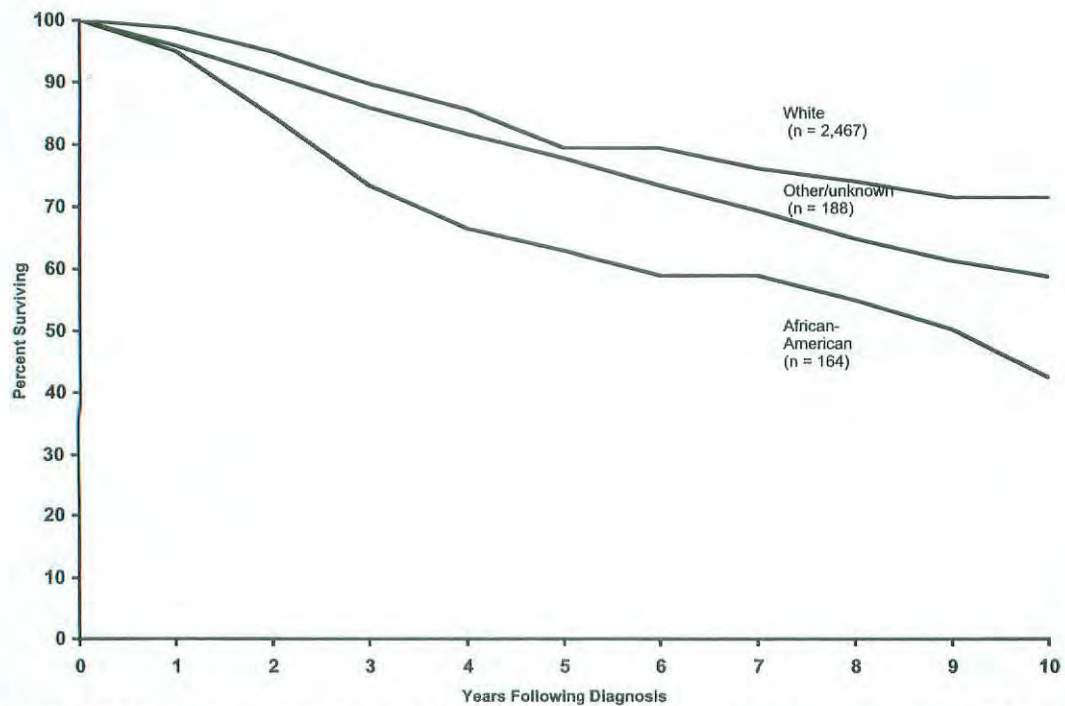
The survival rates depicted in the illustrations account for all deaths, regardless of cause. This is known as *observed survival rate*. Although observed survival is a true reflection of total mortality in the patient group, we frequently are interested in describing mortality attributable only to the disease under investigation. The *adjusted survival rate* is the proportion of the initial patient group that escaped death due to a specific cause (e.g., cancer) if no other cause of death was operating. Whenever reliable information on cause of death is available, an adjustment can be made for deaths due to causes other than the disease under study. This is accomplished by treating patients who died without the disease of interest as censored observations.



**FIG 2.3.** Survival of 2,819 breast cancer patients from the Surveillance, Epidemiology, and End Results Program of the National Cancer Institute, 1983–1998. Calculated by the life table method and stratified by historic stage of disease. *Note:* Excludes 119 patients with unknown stage of disease. SEER uses extent of disease (EOD) staging.

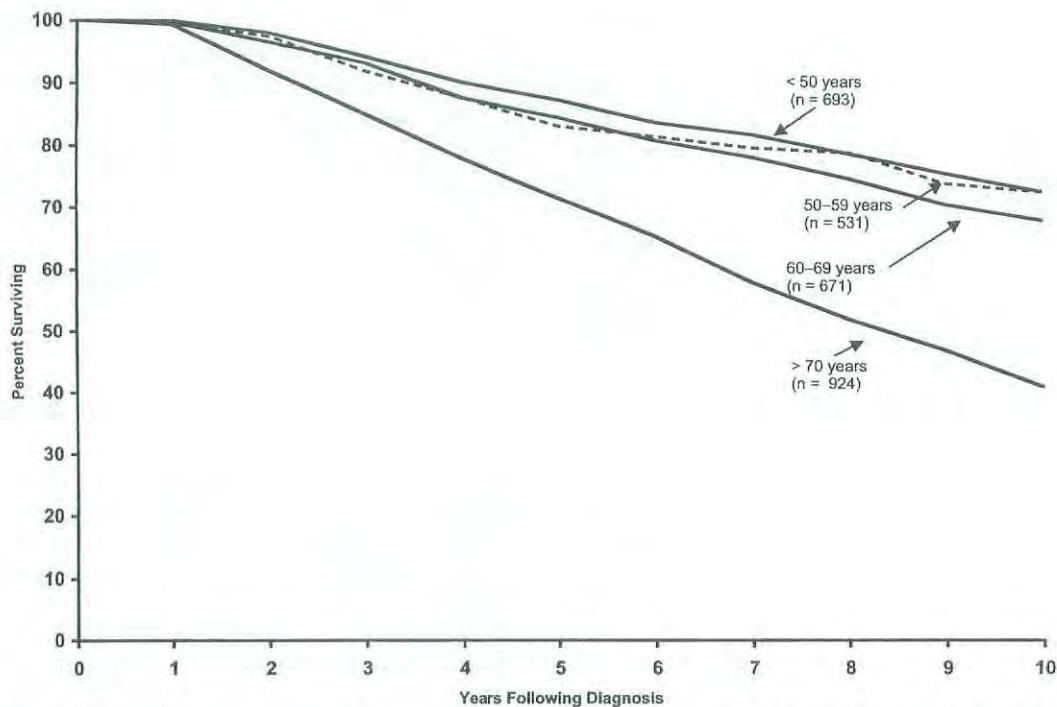
If adjusted survival rates were calculated for lung cancer, the pattern of survival would show little difference between observed and adjusted rates, because lung cancer usually is the cause of death for patients with the diagnosis. For diseases

with more favorable survival patterns, such as breast cancer, patients live long enough to be at risk of other causes of death, and in these instances, adjusted survival rates will tend to be higher than observed survival rates and to give a clearer



**FIG 2.4.** Survival of 2,819 breast cancer patients from the Surveillance, Epidemiology, and End Results Program of the National Cancer Institute, 1983–1998. Calculated by the life table method and stratified by race.





**FIG 2.5.** Survival of 2,819 breast cancer patients from the Surveillance, Epidemiology, and End Results Program of the National Cancer Institute, 1983–1998. Calculated by the life table method and stratified by age at diagnosis.

picture of the specific effects of the diagnosis under investigation. Adjusted rates can be calculated for either life table or Kaplan-Meier results.

tive survival rates may be derived from life table or Kaplan-Meier results.

### RELATIVE SURVIVAL

Information on cause of death is sometimes unavailable or unreliable. Under such circumstances, it is not possible to compute an adjusted survival rate. However, it is possible to adjust partially for differences in the risk of dying from causes other than the disease under study. This can be done by means of the *relative survival rate*, which is the ratio of the observed survival rate to the expected rate for a group of people in the general population similar to the patient group with respect to race, sex, and age. The relative survival rate is calculated using a procedure described by Ederer, Axtell, and Cutler (1961).

The relative survival rate represents the likelihood that a patient will not die from causes associated specifically with their cancer at some specified time after diagnosis. It is always larger than the observed survival rate for the same group of patients. If the group is sufficiently large and the patients are roughly representative of the population of the United States (taking race, sex, and age into account), the relative survival rate provides a useful estimate of the probability of escaping death from the specific cancer under study. However, if reliable information on cause of death is available, it is preferable to use the adjusted rate. This is particularly true when the series is small or when the patients are largely drawn from a particular socioeconomic segment of the population. Rela-

### REGRESSION METHODS

Examining survival within specific patient, disease, or treatment categories is the simplest way of studying multiple factors possibly associated with survival. This approach, however, is limited to factors into which patients may be broadly grouped. This approach does not lend itself to studying the effects of measures that vary on an interval scale. There are many examples of interval variables in cancer, such as number of positive nodes, cell counts, and laboratory marker values. If the patient population were to be divided up into each interval value, too few subjects would be in each analysis to be meaningful. In addition, when more than one factor is considered, the number of curves that result provide so many comparisons that the effects of the factors defy interpretation.

Conventional multiple regression analysis investigates the joint effects of multiple variables on a single outcome, but it is incapable of dealing with censored observations. For this reason, other statistical methods have had to be developed to assess the relationship of survival time to a number of variables simultaneously. The most commonly used is the Cox proportional hazards regression model (Cox, 1972). This model provides a method for estimating the influence of multiple covariates on the survival distribution from data that include censored observations. Covariates are the multiple factors to be studied in association with survival. In the Cox proportional hazards regression model, the covariates

may be categorical variables such as race, interval measures such as age, or laboratory test results.

Specifics of these methods are beyond the scope of this chapter. Fortunately, many readily accessible computer packages for statistical analysis now permit the methods to be applied quite easily by the knowledgeable analyst. Although much useful information can be derived from multivariate survival models, they generally do require additional assumptions about the shape of the survival curve and the nature of the effects of the covariates. One must always examine the appropriateness of the model that is used relative to the assumptions required.

## STANDARD ERROR OF A SURVIVAL RATE

Survival rates that describe the experience of the specific group of patients are frequently used to generalize to larger populations. The existence of true population values is postulated, and these values are estimated from the group under study, which is only a sample of the larger population. If a survival rate were calculated from a second sample taken from the same population, it is unlikely that the results would be exactly the same. The difference between the two results is called the sampling variation (chance variation or sampling error). The *standard error* is a measure of the extent to which sampling variation influences the computed survival rate. In repeated observations under the same conditions, the true or population survival rate will lie within the range of two standard errors on either side of the computed rate about 95 times in 100. This range is called the *95% confidence interval*.

## COMPARISON OF SURVIVAL BETWEEN PATIENT GROUPS

In comparing survival rates of two patient groups, the statistical significance of the observed difference is of interest. The essential question is "What is the probability that the observed difference may have occurred by chance?" The standard error of the survival rate provides a simple means for answering this question. If the 95% confidence intervals of two survival rates do not overlap, the observed difference would customarily be considered statistically significant—that is, unlikely to be due to chance.

It is possible that the differences between two groups at each comparable time of follow-up do not differ significantly but that when the survival curves are considered in their entirety, the individual insignificant differences combine to yield a significantly different pattern of survival. The most common statistical test that examines the whole pattern of differences between survival curves is the *log rank test*. This test equally weights the effects of differences occurring throughout the follow-up and is the appropriate choice for most situations. Other tests weight the differences according to the numbers of persons at risk at different points and can yield different results depending on whether deaths tend more to occur early or later in the follow-up.

Care must be exercised in the interpretation of tests of statistical significance. For example, if differences exist in the patient and disease characteristics of two treatment groups, a statistically significant difference in survival results may primarily reflect differences between the two patient series, rather than differences in efficacy of the treatment regimens. The more definitive approach to therapy evaluation requires a randomized clinical trial that helps to ensure comparability of the patient characteristics and the disease characteristics of the two treatment groups.

## DEFINITION OF STUDY STARTING POINT

The starting time for determining survival of patients depends on the purpose of the study. For example, the starting time for studying the natural history of a particular cancer might be defined in reference to the appearance of the first symptom. Various reference dates are commonly used as starting times for evaluating the effects of therapy. These include (1) date of diagnosis, (2) date of first visit to physician or clinic, (3) date of hospital admission, and (4) date of treatment initiation. If the time to recurrence of a tumor after apparent complete remission is being studied, the starting time is the date of apparent complete remission. The specific reference date used should be clearly specified in every report.

The date of initiation of therapy should be used as the starting time for evaluating therapy. For untreated patients, the most comparable date is the time at which it was decided that no tumor-directed treatment would be given. For both treated and untreated patients, the above times from which survival rates are calculated will usually coincide with the date of the initial staging of cancer.

## VITAL STATUS

At any given time, the vital status of each patient is defined as alive, dead, or unknown (i.e., lost to follow-up). The end-point of each patient's participation in the study is (1) a specified "terminal event" such as death, (2) survival to the completion of the study, or (3) loss to follow-up. In each case, the observed follow-up time is the time from the starting point to the terminal event, to the end of the study, or to the date of last observation. This observed follow-up may be further described in terms of patient status at the end-point, such as

- Alive; tumor-free; no recurrence
- Alive; tumor-free; after recurrence
- Alive with persistent, recurrent, or metastatic disease
- Alive with primary tumor
- Dead; tumor-free
- Dead; with cancer (primary, recurrent, or metastatic disease)

Dead; postoperative  
Unknown; lost to follow-up

Completeness of the follow-up is crucial in any study of survival, because even a small number of patients lost to follow-up may lead to inaccurate or biased results. The maximum possible effect of bias from patients lost to follow-up may be ascertained by calculating a maximum survival rate, assuming that all lost patients lived to the end of the study. A minimum survival rate may be calculated by assuming that all patients lost to follow-up died at the time they were lost.

## TIME INTERVALS

The total survival time is often divided into intervals in units of weeks, months, or years. The survival curve for these intervals provides a description of the population under study with respect to the dynamics of survival over a specified time. The time interval used should be selected with regard to the natural history of the disease under consideration. In diseases with a long natural history, the duration of study could be 5 to 20 years, and survival intervals of 6 to 12 months will provide a meaningful description of the survival dynamics. If the population being studied has a very poor prognosis (e.g., patients with carcinoma of the esophagus or pancreas), the total duration of study may be 2 to 3 years, and the survival intervals may be described in terms of 1 to 3 months. In interpreting survival rates, one must also take into account the number of individuals entering a survival interval.

## SUMMARY

This chapter has reviewed the rudiments of survival analysis as it is often applied to cancer registry data. Complex analysis of data and exploration of research hypotheses demand

greater knowledge and expertise than could be conveyed herein. Survival analysis is now performed automatically in many different registry data management and statistical analysis programs available for use on personal computers. Persons with access to these programs are encouraged to explore the different analysis features available to demonstrate for themselves the insight on cancer registry data that survival analysis can provide.

## BIBLIOGRAPHY

- American Joint Committee on Cancer: AJCC Cancer Staging Manual, 5th ed. Fleming ID, Cooper JS, Henson DE et al (Eds.). Philadelphia: Lippincott-Raven, 1997
- Berkson J, Gage RP: Calculation of survival rates for cancer. *Proc Staff Meet Mayo Clin* 25:270-286, 1950
- Cox DR: Regression models and life tables. *J R Stat Soc B* 34:187-220, 1972
- Cox DR, Oakes D: Analysis of survival data. London: Chapman and Hall, 1984
- Ederer F, Axtell LM, Cutler SJ: The relative survival rate: a statistical methodology. *Natl Cancer Inst Monogr* 6:101-121, 1961
- Fleming TR, Harrington DP: Counting processes and survival analysis. New York: John Wiley, 1991
- Kalbfleisch JD, Prentice RL: The statistical analysis of failure time data. New York: John Wiley, 321, 1980
- Kaplan EL, Meier P: Nonparametric estimation from incomplete observations. *J Am Stat Assn* 53:457-481, 1958
- Kleinbaurn DG: Survival analysis: a self learning text. New York: Springer-Verlag, 1996
- Lee ET: Statistical methods for survival data analysis. New York: John Wiley, 1992
- Mantel N: Evaluation of survival data and two new rank order statistics arising in its consideration. *Cancer Chemother Rep* 50:163-170, 1966
- Ries LAG, Eisner MP, Kosary CL, et al (Eds.): SEER cancer statistics review, 1973-1997: tables and graphs, National Cancer Institute. Bethesda, MD: National Institutes of Health, NIH Pub. No. 00-2789, 2000



## PART II

# Head and Neck Sites

### SUMMARY OF CHANGES

- Across the board for all head and neck sites, a uniform description of advanced tumors has been recommended whereby T4 lesions are divided into T4a (resectable) and T4b (unresectable). This will allow assignment of patients with advanced stage disease to three categories: Stage IVA, advanced resectable disease; Stage IVB, advanced unresectable disease; and Stage IVC, advanced distant metastatic disease.
- In general, every effort has been made to bring the stage groupings to a relatively uniform combination of T, N, and M categories for all sites, including paranasal sinuses, salivary tumors, and thyroid tumors.
- No changes have been made in the N staging for any sites except that a descriptor has been added for nodal metastasis in the upper neck or in the lower neck, designated by (U) and (L), respectively. This descriptor will not influence nodal staging.

### INTRODUCTION

Cancers of the head and neck may arise from any of the lining membranes of the upper aerodigestive tract. The T classifications indicating the extent of the primary tumor are generally similar but differ in specific details for each site because of anatomic considerations. The N classification for cervical lymph node metastasis is uniform for all mucosal sites except nasopharynx. The N classification for thyroid and nasopharynx are unique to those sites and are based on tumor behavior and prognosis. The staging systems presented in this section are all clinical staging, based on the best possible estimate of the extent of disease before first treatment. Imaging techniques (computed tomography [CT], magnetic resonance imaging [MRI], and ultrasonography) may be applied and, in more advanced tumor stages, have added to the accuracy of primary (T) and nodal (N) staging, especially in the nasopharyngeal, paranasal sinuses, and regional lymph nodal areas. Appropriate imaging studies should be obtained whenever the clinical findings are uncertain. Similarly, endoscopic evaluation of the primary tumor, when appropriate, is desirable for detailed assessment of the primary tumor for accurate T staging. Fine-needle aspiration biopsy (FNAB) may

confirm the presence of tumor and its histopathologic nature, but it cannot rule out the presence of tumor.

Any diagnostic information that contributes to the overall accuracy of the pretreatment assessment should be considered in clinical staging and treatment planning. When surgical treatment is carried out, cancer of the head and neck can be staged—(pathologic stage [pTNM]) using all information available from clinical assessment, as well as from the pathologic study of the resected specimen. The pathologic stage does not replace the clinical stage, which should be reported as well.

In reviewing the staging systems, several changes in the T classifications as well as stage groupings are made to reflect current practices of treatment, clinical relevance, and contemporary data. Uniform T staging for oral cavity, oropharynx, salivary, and thyroid cancers greatly simplifies the system and will improve compliance by clinicians. T4 tumors are subdivided into advanced resectable (T4a) and advanced unresectable (T4b) categories. Regrouping of Stage IV disease for all sites into advanced resectable (Stage IVA), advanced unresectable (Stage IVB), and distant metastatic (Stage IVC) also simplifies advanced-disease staging.

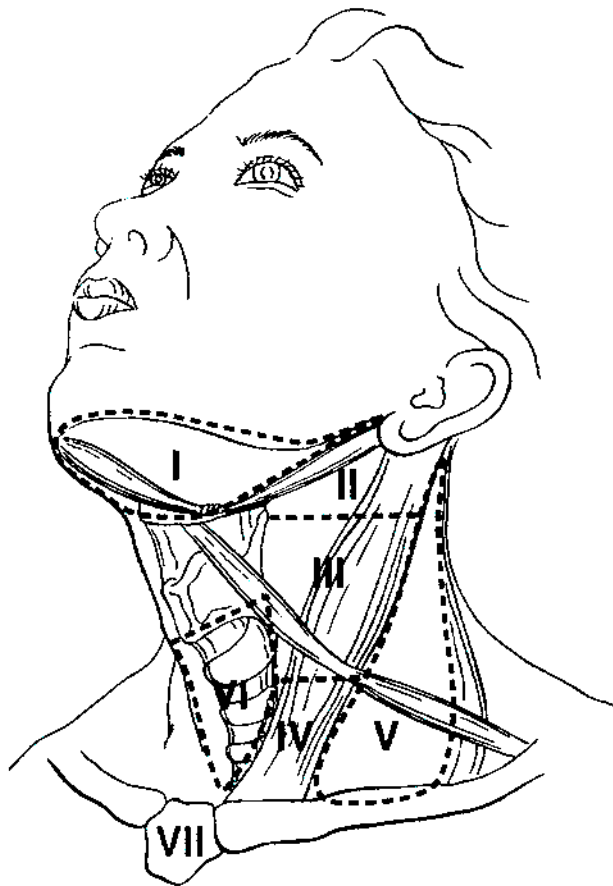
This section presents the staging classification for six major head and neck sites: the oral cavity, the pharynx (nasopharynx, oropharynx, and hypopharynx), the larynx, the paranasal sinuses, the salivary glands, and the thyroid gland.

**Regional Lymph Nodes.** The status of the regional lymph nodes in head and neck cancer is of such prognostic importance that the cervical nodes must be assessed for each patient and tumor. The lymph nodes may be subdivided into specific anatomic subsites and grouped into seven levels for ease of description.

Level I:	Submental Submandibular
Level II:	Upper jugular
Level III:	Mid-jugular
Level IV:	Lower jugular
Level V:	Posterior triangle (spinal accessory and transverse cervical) (upper, middle, and lower, corresponding to the levels that define upper, middle, and lower jugular nodes)
Level VI:	Prelaryngeal (Delphian) Pretracheal Paratracheal
Level VII:	Upper mediastinal
Other groups:	Sub-occipital Retropharyngeal Parapharyngeal Buccinator (facial) Preauricular Periparotid and intraparotid

The location of the lymph node levels conforms to the following clinical descriptions, which also correlate with surgical landmarks at the time of surgical neck exploration (Fig. 2.1).

Level I:	Contains the submental and submandibular triangles bounded by the anterior and posterior bellies of the digastric muscle, and the hyoid bone inferiorly, and the body of the mandible superiorly.
Level II:	Contains the upper jugular lymph nodes and extends from the level of the skull base superiorly to the hyoid bone inferiorly.
Level III:	Contains the middle jugular lymph nodes from the hyoid bone superiorly to the level of the lower border of the cricoid cartilage inferiorly.



**FIG 2.1.** Schematic diagram indicating the location of the lymph node levels in the neck as described in the text.

- Level IV: Contains the lower jugular lymph nodes from the level of the cricoid cartilage superiorly to the clavicle inferiorly.
- Level V: Contains the lymph nodes in the posterior triangle bounded by the anterior border of the trapezius muscle posteriorly, the posterior border of the sternocleidomastoid muscle anteriorly, and the clavicle inferiorly. For descriptive purposes, Level V may be further subdivided into upper, middle, and lower levels corresponding to the superior and inferior planes that define Levels II, III, and IV.
- Level VI: Contains the lymph nodes of the anterior central compartment from the hyoid bone superiorly to the suprasternal notch inferiorly. On each side, the lateral boundary is formed by the medial border of the carotid sheath.
- Level VII: Contains the lymph nodes inferior to the suprasternal notch in the superior mediastinum.

The pattern of the lymphatic drainage varies for different anatomic sites. However, the location of the lymph node metastases has prognostic significance in patients with squamous cell carcinoma of the head and neck. Survival is significantly worse when metastases involve lymph nodes beyond the first echelon of lymphatic drainage and, particularly, lymph nodes in the lower regions of the neck, i.e., Level IV and Level V (supraclavicular region). Consequently, it is recommended that each N staging category be recorded to show, in addition to the established parameters, whether the nodes involved are located in the upper (U) or lower (L) regions of the neck, depending on their location above or below the lower border of the cricoid cartilage.

The natural history and response to treatment of cervical nodal metastases from nasopharynx primary sites are different, in terms of their impact on prognosis, so they justify a different N classification scheme. Regional node metastases from well-differentiated thyroid cancer do not significantly affect the ultimate prognosis and therefore also justify a unique staging system for thyroid cancers.

Histopathologic examination is necessary to exclude the presence of tumor in lymph nodes. No imaging study (as yet) can identify microscopic tumor foci in regional nodes or distinguish between small reactive nodes and small malignant nodes.

When enlarged lymph nodes are detected, the actual size of the nodal mass(es) should be measured. It is recognized that most masses over 3 cm in diameter are not single nodes but are confluent nodes or tumor in soft tissues of the neck. Imaging studies showing amorphous spiculated margins of involved nodes or involvement of internodal fat resulting in loss of normal oval to round nodal shape strongly suggest extracapsular (extranodal) tumor spread. Pathologic examination is necessary for documentation of tumor extent in terms of the location or level of the lymph node(s) involved, the number of nodes that contain metastases, and the presence or absence of extracapsular spread of tumor.

**Metastatic Sites.** The most common sites of distant spread are in the lungs and bones; hepatic and brain metastases occur less often. Mediastinal lymph node metastases are considered distant metastases.

#### **Regional Lymph Nodes (N)**

- NX Regional lymph nodes cannot be assessed
- N0 No regional lymph node metastasis
- \*N1 Metastasis in a single ipsilateral lymph node, 3 cm or less in greatest dimension
- \*N2 Metastasis in a single ipsilateral lymph node, more than 3 cm but not more than 6 cm in greatest dimension; or in multiple ipsilateral lymph nodes, none more than 6 cm in greatest dimension; or in bilateral or contralateral lymph nodes, none more than 6 cm in greatest dimension
- \*N2a Metastasis in single ipsilateral lymph node more than 3 cm but not more than 6 cm in greatest dimension
- \*N2b Metastasis in multiple ipsilateral lymph nodes, none more than 6 cm in greatest dimension
- \*N2c Metastasis in bilateral or contralateral lymph nodes, none more than 6 cm in greatest dimension
- \*N3 Metastasis in a lymph node more than 6 cm in greatest dimension

\*Note: A designation of "U" or "L" may be used to indicate metastasis above the lower border of the cricoid (U) or below the lower border of the cricoid (L).

#### **Distant Metastasis (M)**

- MX Distant metastasis cannot be assessed
- M0 No distant metastasis
- M1 Distant metastasis

## **OUTCOME RESULTS**

The survival curves shown for each anatomic site were constructed using head and neck cancer cases extracted from the National Cancer Data Base (NCDB) Call 9 data set, which represents patients diagnosed between 1985 and 1996. Survival analyses were performed on 1985–1991 cases that, as a result of the

methodology of data collection, have at least 5 years of follow-up. The survival methods, performed using SPSS software, included observed survival (death from all causes) and relative survival (representing death from the cancer derived from observed survival rates adjusted for expected deaths based on age, race, and gender).

Anatomic sites and histologic types were coded on the NCDB according to the second edition of the *International Classification of Diseases for Oncology* (ICD-O-2). The subsites to be included in each analysis were chosen on the basis of those listed in the fourth edition of the *AJCC's Manual for Staging of Cancer*. Survival analyses for the lip, oral cavity, oropharynx, nasopharynx, hypopharynx, and the larynx's subsites included squamous cell carcinomas only (M8050, 8051–8082). Survival analyses for the maxillary sinus and major salivary glands included all histologic types. Survival analyses for the thyroid gland included papillary adenocarcinoma (M8050, 8260, 8340, 8503–8604), follicular adenocarcinoma (M8330–8332), medullary carcinoma (M8510–8512), and anaplastic carcinoma (M8021).

Only cases that were staged according to the third or fourth editions of the *AJCC's Manual for Staging of Cancer* were included. The survival analyses for the different sites were stratified by AJCC “combined” stage (representing pathologic stage, when available, and only clinical stage when pathological stage was not available). The 95% confidence intervals are provided for each year-5 survival rate, so that significance differences between the year-5 survival rates of the different stages can be determined.

## BIBLIOGRAPHY

- Beahrs O, Henson DE, Hutter RVP, Kennedy BJ (Eds.): *American Joint Committee on Cancer: Manual for Staging of Cancer*, 4th ed. Philadelphia: JB Lippincott, 1992
- Cerezo L, Millan I, Torre A, Aragon G, Otero J.: Prognostic factors for survival and tumor control in cervical lymph node metastases from head and neck cancer: a multivariate study of 492 cases. *Cancer* 69:1224–1234, 1992
- Cooper JS, Farnan NC, Asbell SO, et al: Recursive partitioning analysis of 2105 patients treated in Radiation Therapy Oncology Group studies of head and neck cancer. *Cancer* 77:1905–1911, 1996
- Deleviannis FW, Thomas DB, Vaughan TL, et al: Alcoholism: independent predictor of survival in patients with head and neck cancer. *J Natl Cancer Inst* 88:542–549, 1996
- Faye-Lund H, Abdelnoor M: Prognostic factors of survival in a cohort of head and neck cancer patients in Oslo. *Eur J Cancer B Oral Oncol* 2:83–90, 1996
- Grandi C, Alloisio M, Moglia D, et al: Prognostic significance of lymphatic spread in head and neck carcinomas: therapeutic implications. *Head Neck Surg* 8:67–73, 1985
- Harnsberger HR: Squamous cell carcinoma: nodal staging. In *Handbook of head and neck imaging*, 2nd ed. St. Louis: Mosby, 283–298, 1995
- Hillsamer PJ, Schuller DE, McGhee RB, et al: Improving diagnostic accuracy of cervical metastases with CT and MRI imaging. *Arch Otolaryngo Head Neck Surg*, 116:2297–1301, 1990
- Jones AS, Roland NJ, Field JK, Phillips DE: The level of cervical lymph node metastases: their prognostic relevance and relationship with head and neck squamous carcinoma primary sites. *Clin Otolaryngol* 19:63–69, 1994
- Kalnins IK, Leonard AG, Sako K et al: Correlation between prognosis and degree of lymph node involvement in carcinoma of the oral cavity. *Am J Surg* 34:450–454, 1977
- Kowalski LP, Bagietto R, Lara JR, et al: Prognostic significance of the distribution of neck node metastasis from oral carcinoma. *Head Neck* 22:207–214, 2000
- Mancuso AA, Harnsberger HR, Muraki AS, et al: Computed tomography of cervical and retropharyngeal lymph nodes: normal anatomy, variants of normal, and application in staging head and neck cancer. II. Pathology. *Radiology* 148:715–723, 1983



- Medina JE: A rational classification of neck dissections. *Otolaryngol Head Neck Surg* 100:169–176, 1989
- Percy C, Van Holten V, Muir C (Eds.): *International classification of disease for oncology*, 2nd ed. Geneva: World Health Organization, 1990
- Piccirillo JF: Inclusion of comorbidity in a staging system for head and neck cancer. *Oncology* 9:831–836, 1995
- Richard JM, Sancho-Garnier H, Michaeu C, et al: Prognostic factors in cervical lymph node metastasis in upper respiratory and digestive tract carcinomas: study of 1713 cases during a 15-year period. *Laryngoscope* 97:97–101, 1987
- Robbins KT: Neck dissection: classification and incisions. In Shockley WW, Pillsbury HC (Eds.): *The neck: diagnosis and surgery*. St. Louis: Mosby, 381–391, 1994
- Singh B, Alfonso A, Sabin S, et al: Outcome differences in younger and older patients with laryngeal cancer: a retrospective case-control study. *Am J Otolaryngol*, 21:92–97, 2000
- Singh B, Bhaya M, Zimble M, et al: Impact of comorbidity on outcome of young patients with head and neck squamous cell carcinoma. *Head Neck* 20:1–7, 1998
- Som PM: Detection of metastasis in cervical lymph nodes: CT and MR criteria and differential diagnosis. *Am J Radiol* 158:961–969, 1992
- Stell PM, Morton RP, Singh SD: Cervical lymph node metastases: the significance of the level of the lymph node. *Clin Oncol* 9:101–107, 1983
- Stevens MH, Harnsberger HR, Mancuso AA: Computed tomography of cervical lymph nodes: staging and management of head and neck cancer. *Arch Otolaryngol* 111(11):735–739, 1985
- Strong EW, Kasdorf H, Henk JM: Squamous cell carcinoma of the head and neck. In Hermanek P, Gospodarowicz MK, Henson DE, et al (Eds.): *Prognostic factors in cancer, UICC Geneva*. Berlin-New York: Springer-Verlag, 23–27, 1995
- Yousem DM, Som PM, Hackney DB, et al: Central nodal necrosis and extracapsular neoplastic spread in cervical lymph nodes: MR imaging versus CT. *Radiology* 182:753–759, 1992

## Lip and Oral Cavity

(Nonepithelial tumors such as those of lymphoid tissue, soft tissue, bone, and cartilage are not included.)

C00.0 External upper lip	C02.2 Ventral surface of tongue, NOS	C04.9 Floor of mouth, NOS
C00.1 External lower lip	C02.3 Anterior two-thirds of tongue, NOS	C05.0 Hard palate
C00.2 External lip, NOS	C02.8 Overlapping lesion of tongue	C05.8 Overlapping lesion of palate
C00.3 Mucosa of upper lip	C02.9 Tongue, NOS	C05.9 Palate, NOS
C00.4 Mucosa of lower lip	C03.0 Upper gum	C06.0 Cheek mucosa
C00.5 Mucosa of lip, NOS	C03.1 Lower gum	C06.1 Vestibule of mouth
C00.6 Commissure of lip	C03.9 Gum, NOS	C06.2 Retromolar area
C00.8 Overlapping lesion of lip	C04.0 Anterior floor of mouth	C06.8 Overlapping lesion of other and unspecified parts of mouth
C00.9 Lip, NOS	C04.1 Lateral floor of mouth	C06.9 Mouth, NOS
C02.0 Dorsal surface of tongue, NOS	C04.8 Overlapping lesion of floor of mouth	
C02.1 Border of tongue		

### SUMMARY OF CHANGES

- T4 lesions have been divided into T4a (resectable) and T4b (unresectable), leading to the division of Stage IV into Stage IVA, Stage IVB, and Stage IVC.

### ANATOMY

**Primary Site.** The oral cavity extends from the skin-*vermilion* junction of the lips to the junction of the hard and soft palate above and to the line of *circumvallate papillae* below and is divided into the following specific areas:

**Mucosal Lip.** The lip begins at the junction of the *vermilion border* with the skin and includes only the *vermilion surface* or that portion of the lip that comes into contact with the opposing lip. It is well defined into an upper and lower lip joined at the *commissures* of the mouth.

**Buccal Mucosa.** This includes all the membrane lining of the inner surface of the cheeks and lips from the line of contact of the opposing lips to the line of attachment of mucosa of the *alveolar ridge* (upper and lower) and *pterygo-mandibular raphe*.

**Lower Alveolar Ridge.** This refers to the mucosa overlying the *alveolar process* of the mandible which extends from the line of attachment of mucosa in the *buccal gutter* to the line of free mucosa of the floor of the mouth. Posteriorly it extends to the *ascending ramus* of the mandible.

**Upper Alveolar Ridge.** This refers to the mucosa overlying the *alveolar process* of the maxilla which extends from the line of attachment of mucosa in the upper gingival buccal

*gutter* to the junction of the hard palate. Its posterior margin is the upper end of the *pterygopalatine arch*.

**Retromolar Gingiva (Retromolar Trigone).** This is the attached mucosa overlying the *ascending ramus* of the mandible from the level of the posterior surface of the last molar tooth to the apex superiorly, adjacent to the *tuberosity* of the maxilla.

**Floor of the Mouth.** This is a *semilunar space* over the *myelohyoid* and *hyoglossus* muscles, extending from the inner surface of the lower *alveolar ridge* to the undersurface of the tongue. Its posterior boundary is the base of the anterior pillar of the tonsil. It is divided into two sides by the *frenulum* of the tongue and contains the ostia of the *submaxillary* and *sublingual salivary glands*.

**Hard Palate.** This is the *semilunar area* between the upper *alveolar ridge* and the mucous membrane covering the *palatine process* of the maxillary palatine bones. It extends from the inner surface of the superior *alveolar ridge* to the posterior edge of the palatine bone.

**Anterior Two-Thirds of the Tongue (Oral Tongue).** This is the freely mobile portion of the tongue that extends anteriorly from the line of *circumvallate papillae* to the undersurface of the tongue at the junction of the floor of the mouth. It is composed of four areas: the tip, the lateral borders, the

dorsum, and the undersurface (nonvillous ventral surface of the tongue). The undersurface of the tongue is considered a separate category by the World Health Organization (WHO).

**Regional Lymph Nodes.** Mucosal cancer of the oral cavity may spread to regional lymph node(s). Tumors of each anatomic site have their own predictable patterns of regional spread. The risk of regional metastasis is generally related to the T category and, probably more important, to the depth of infiltration of the primary tumor. Cancer of the lip carries a low metastatic risk and initially involves adjacent submental and submandibular nodes, then jugular nodes. Cancers of the hard palate and alveolar ridge likewise have a low metastatic potential and involve buccinator, submandibular, jugular, and occasionally retropharyngeal nodes. Other oral cancers will spread primarily to submandibular and jugular nodes and uncommonly to posterior triangle/supraclavicular nodes. Cancer of the anterior oral tongue may spread directly to lower jugular nodes. The closer to the midline the primary, the greater the risk of bilateral cervical nodal spread. Any previous treatment to the neck, surgical and/or radiation, may alter normal lymphatic drainage patterns, resulting in unusual distribution of regional spread of disease to the cervical lymph nodes. In general, cervical lymph node involvement from oral cavity primary sites is predictable and orderly, spreading from the primary to upper, then middle, and subsequently lower cervical nodes. However, disease in the anterior oral cavity may also spread directly to the mid-cervical lymph nodes. The risk of distant metastasis is more dependent on the N than on the T status of the head and neck cancer. Midline nodes are considered ipsilateral. In addition to the components to describe the N category, regional lymph nodes should also be described according to the level of the neck that is involved. It is recognized that the level of involved nodes in the neck is prognostically significant (lower is worse), as is the presence of extracapsular extension of metastatic tumor from individual nodes. Imaging studies showing amorphous spiculated margins of involved nodes or involvement of internodal fat resulting in loss of normal oval-to-round nodal shape strongly suggest extracapsular (extranodal) tumor spread; however, pathologic examination is necessary for documentation of the extent of such disease. No imaging study (as yet) can identify microscopic foci of cancer in regional nodes or distinguish between small reactive nodes and small malignant nodes (unless central radiographic inhomogeneity is present). For pN, a selective neck dissection will ordinarily include six or more lymph nodes, and a radical or modified radical neck dissection will ordinarily include ten or more lymph nodes. Negative pathologic examination of a lesser number of nodes still mandates a pN0 designation.

**Metastatic Sites.** The lungs are the commonest site of distant metastases; skeletal and hepatic metastases occur less often. Mediastinal lymph node metastases are considered distant metastases.

## RULES FOR CLASSIFICATION

**Clinical Staging.** The assessment of the primary tumor is based on inspection and palpation of the oral cavity and neck. Additional studies may include CT or MRI. When imaging is utilized, one study will generally suffice to evaluate primary and nodal tumor extent. Clinical assessment of the extent of mucosal involvement is more accurate than radiographic assessment. The radiographic estimate of deep tissue extent and of regional lymph node involvement is usually more accurate than clinical assessment. MRI is generally more revealing of extent of soft tissue, perivascular, and perineural spread, skull base involvement, and intracranial tumor extension. On the other hand, high-resolution CT with contrast will often provide similar information if carefully done, will provide better images of bone and larynx detail, and is minimally affected by motion. CT or MR imaging may be more useful in evaluation of advanced tumors for assessment of bone invasion (mandible or maxilla) and deep tissue invasion (deep extrinsic tongue muscles, midline tongue, soft tissues of neck). Clinical examination supplemented with dental films or panoramic X-rays may be helpful in determining cortical bone involvement. If CT or MR imaging is undertaken for primary tumor evaluation, radiologic assessment of nodal involvement should be done simultaneously. For lesions of an advanced extent, appropriate screening for distant metastases should be considered. Ultrasonography may be helpful in assessment of major vascular invasion as an adjunctive test. The tumor must be confirmed histologically. All clinical, imaging, and pathologic data available prior to first definitive treatment may be used for clinical staging.

**Pathologic Staging.** Complete resection of the primary site and/or regional nodal dissections, followed by pathologic examination of the resected specimen(s), allows the use of this designation for pT and/or pN, respectively. Specimens that are resected after radiation or chemotherapy need to be identified and considered in context. pT is derived from the actual measurement of the unfixed tumor in the surgical specimen. It should be noted, however, that up to 30% shrinkage of soft tissues may occur in the resected specimen. Pathologic staging represents additional and important information and should be included as such in staging, but it does not supplant clinical staging as the primary staging scheme.

## DEFINITION OF TNM

### Primary Tumor (T)

TX	Primary tumor cannot be assessed
T0	No evidence of primary tumor
Tis	Carcinoma <i>in situ</i>
T1	Tumor 2 cm or less in greatest dimension
T2	Tumor more than 2 cm but not more than 4 cm in greatest dimension
T3	Tumor more than 4 cm in greatest dimension

- T4 (lip) Tumor invades through cortical bone, inferior alveolar nerve, floor of mouth, or skin of face, i.e., chin or nose
- T4a (oral cavity) Tumor invades adjacent structures (e.g., through cortical bone, into deep [extrinsic] muscle of tongue [genioglossus, hyoglossus, palatoglossus, and styloglossus], maxillary sinus, skin of face)
- T4b Tumor invades masticator space, pterygoid plates, or skull base and/or encases internal carotid artery

*Note:* Superficial erosion alone of bone/tooth socket by gingival primary is not sufficient to classify a tumor as T4.

**Regional Lymph Nodes (N)**

- NX Regional lymph nodes cannot be assessed
- N0 No regional lymph node metastasis
- N1 Metastasis in a single ipsilateral lymph node, 3 cm or less in greatest dimension
- N2 Metastasis in a single ipsilateral lymph node, more than 3 cm but not more than 6 cm in greatest dimension; or in multiple ipsilateral lymph nodes, none more than 6 cm in greatest dimension; or in bilateral or contralateral lymph nodes, none more than 6 cm in greatest dimension
- N2a Metastasis in single ipsilateral lymph node more than 3 cm but not more than 6 cm in greatest dimension
- N2b Metastasis in multiple ipsilateral lymph nodes, none more than 6 cm in greatest dimension
- N2c Metastasis in bilateral or contralateral lymph nodes, none more than 6 cm in greatest dimension
- N3 Metastasis in a lymph node more than 6 cm in greatest dimension

**Distant Metastasis (M)**

- MX Distant metastasis cannot be assessed
- M0 No distant metastasis
- M1 Distant metastasis

**STAGE GROUPING**

Stage 0	Tis	N0	M0
Stage I	T1	N0	M0
Stage II	T2	N0	M0
Stage III	T3	N0	M0
	T1	N1	M0
	T2	N1	M0
	T3	N1	M0
Stage IVA	T4a	N0	M0
	T4a	N1	M0
	T1	N2	M0
	T2	N2	M0
	T3	N2	M0
Stage IVB	Any T	N3	M0
	T4b	Any N	M0
Stage IVC	Any T	Any N	M1

**HISTOPATHOLOGIC TYPE**

The predominant cancer is squamous cell carcinoma. The staging guidelines are applicable to all forms of carcinoma. Nonepithelial tumors such as those of lymphoid tissue, soft tissue, and bone and cartilage (i.e., lymphoma, melanoma, and sarcoma) are not included. Histologic confirmation of diagnosis is required. Histopathologic grading of squamous carcinoma is recommended; the grade is subjective and uses a descriptive as well as numerical form, i.e., well, moderately well, and poorly differentiated, depending on the degree of closeness to, or deviation from, squamous epithelium in mucosal sites. Also recommended is a quantitative evaluation of depth of invasion of the primary tumor and the presence or absence of vascular invasion and perineural invasion.

**CHARACTERISTICS OF TUMOR (SEE FIG. 3.1A, B, C)**

**Endophytic.** The measurement using an ocular micrometer is taken perpendicular from the surface of the invasive squamous cell carcinoma (A) to the deepest area of involvement (B) and recorded in millimeters. The measurement should not be done on tangential sections or in lesions without a clearly recognizable surface component.

**Exophytic.** The measurement that is better characterized as tumor thickness rather than depth of invasion, is taken from the surface (A) to the deepest area (B).

**Ulcerated.** The measurement is taken from the ulcer base (A) to the deepest area (B), as well as from the surface of the most lateral extent of the invasive carcinoma (C) to the deepest area (D).

Depth of tumor invasion (mm) should be recorded. Depth is *not* used for T staging.

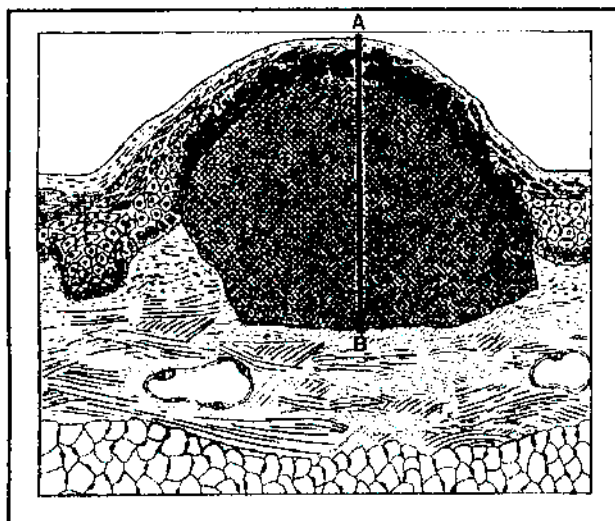
Although the grade of the tumor does not enter into staging of the tumor, it should be recorded. The pathologic description of any lymphadenectomy specimen should describe the size, number, and position of involved lymph node(s) and the presence or absence of extracapsular extension.

**HISTOLOGIC GRADE (G)**

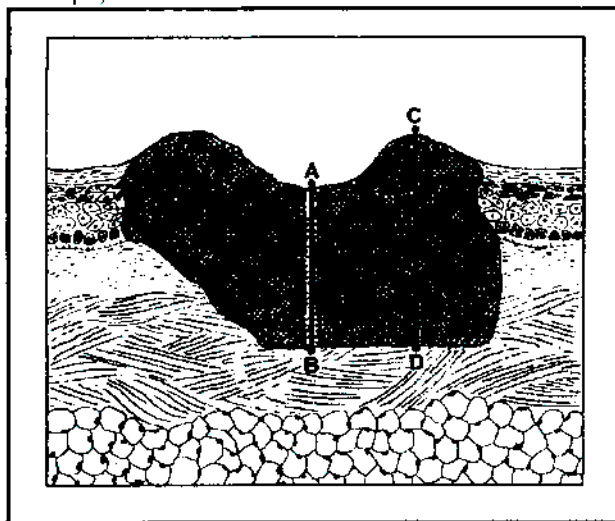
- GX Grade cannot be assessed
- G1 Well differentiated
- G2 Moderately differentiated
- G3 Poorly differentiated

**PROGNOSTIC FACTORS**


In addition to the importance of the TNM factors outlined previously, the overall health of these patients clearly influences outcome. Comorbidity can be classified by more general measures, such as the Karnofsky Performance Status (KPS), or by more specific measures, such as the Kaplan-Feinstein Index. The KPS provides a uniform, objective



A. Exophytic



B. Ulcerated



C. Endophytic

**FIG. 3.1.** Characteristics of lip and oral cavity tumors. A: Exophytic; B: Ulcerated; C: Endophytic.

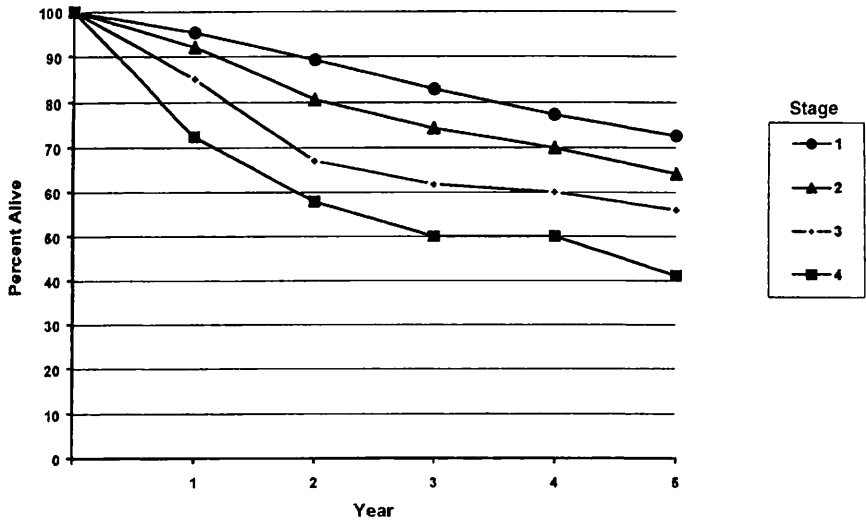
assessment of an individual's functional status. The scale, in 10-point increments from 0 (dead) to 100 (normal, no complaints, no evidence of disease), was devised in 1948 by David A. Karnofsky. The KPS is a reliable, independent predictor of survival outcome for patients with solid tumors, so it is a required baseline assessment in clinical protocols in head and neck and other cancers. The AJCC strongly recommends recording of KPS along with standard staging information.

**Karnofsky Scale: Criteria of Performance Status (PS)**

- 100 Normal; no complaints; no evidence of disease
- 90 Able to carry on normal activity; minor signs or symptoms of disease
- 80 Able to carry on normal activity with effort; some signs or symptoms of disease
- 70 Cares for self; unable to carry on normal activity or do active work
- 60 Requires occasional assistance but is able to care for most of own needs
- 50 Requires considerable assistance and frequent medical care
- 40 Disabled; requires special care and assistance

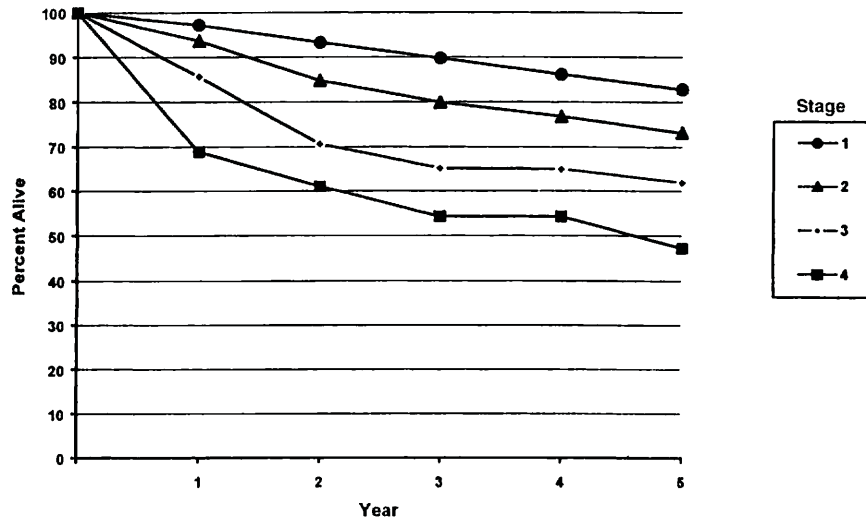
Diagnosis and treatment of depression may also aid in symptom control and improved quality of life. Continued exposure to carcinogens, such as alcohol and tobacco smoke, probably affects patients' outcomes adversely.

Figures 3.2A, 3.2B, 3.3A, and 3.3B show observed and relative survival rates for patients with squamous cell carcinoma of the lip and squamous cell carcinoma of the oral cavity for the years 1985–1991, classified by the AJCC staging classification.



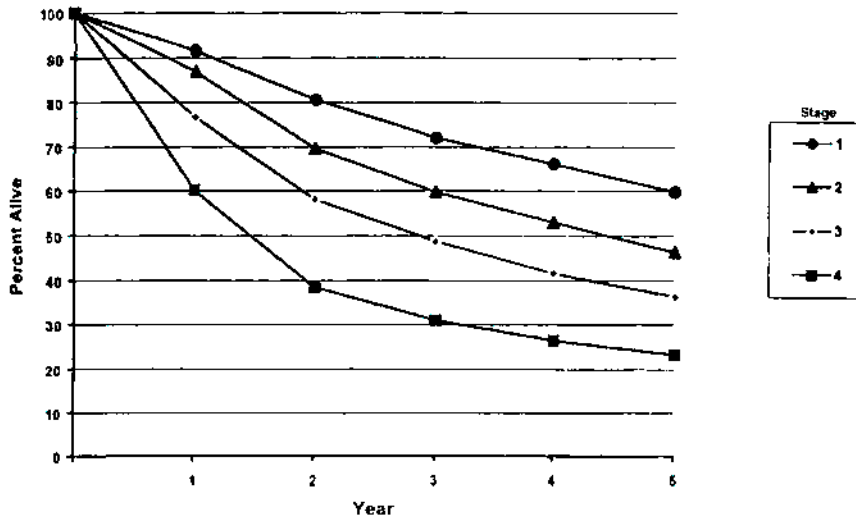
OBSERVED SURVIVAL BY STAGE	1	2	3	4	5	95% Cis*	CASES
1	95.2	89.2	82.9	77.3	72.6	70.1 – 75.0	1543
2	82.0	80.6	71.3	69.9	64.1	57.6 – 70.6	248
3	85.0	67.0	61.8	60.0	56.0	43.3 – 68.6	69
4	72.4	57.9	50.0	50.0	41.1	27.8 – 54.5	65

**FIG. 3.2A.** Five-year, observed survival by “combined” AJCC stage for squamous cell carcinoma of the lip, 1985–1991. (\*95% confidence intervals correspond to year-5 survival rates.)



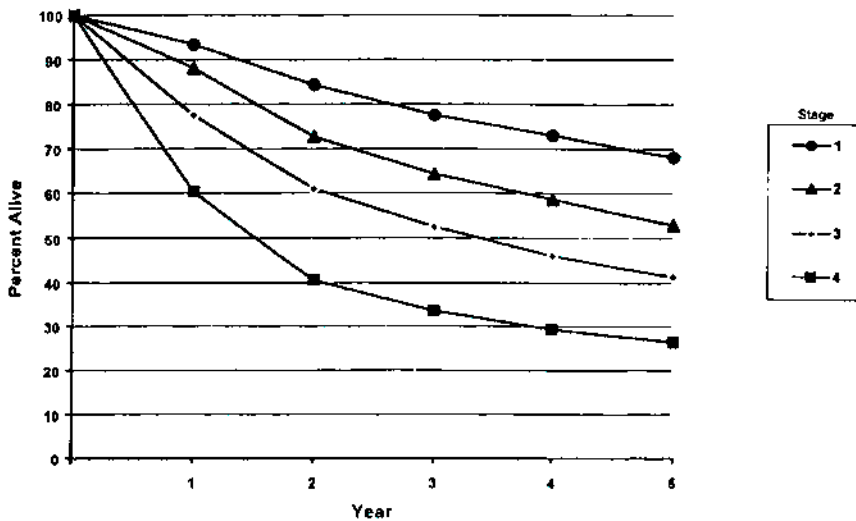
RELATIVE SURVIVAL BY STAGE	1	2	3	4	5	95% Cis*	CASES
1	97.2	93.2	89.7	86.1	82.8	80.1 – 85.6	1552
2	93.6	84.7	79.9	76.8	73.1	65.6 – 80.5	252
3	85.6	70.6	65.1	64.9	61.9	47.2 – 76.7	69
4	68.9	61.0	54.3	54.3	47.2	31.8 – 62.6	66

**FIG. 3.2B.** Five-year, relative survival by “combined” AJCC stage for squamous cell carcinoma of the lip, 1985–1991. (\*95% confidence intervals correspond to year-5 survival rates.)



OBSERVED SURVIVAL BY STAGE	1	2	3	4	5	95% CIs*	CASES
1	91.6	80.6	72.0	66.1	59.8	57.7 – 61.8	2511
2	87.0	69.6	59.7	53.0	46.3	43.8 – 48.7	1839
3	76.7	58.1	48.7	41.6	36.3	33.6 – 38.9	1431
4	60.2	38.4	30.9	26.5	23.3	21.5 – 25.0	2433

**FIG. 3.3A.** Five-year, observed survival by "combined" AJCC stage for squamous cell carcinoma of the oral cavity, 1985–1991. (\*95% confidence intervals correspond to year-5 survival rates.)



RELATIVE SURVIVAL BY STAGE	1	2	3	4	5	95% CIs*	CASES
1	93.3	84.4	77.5	73.0	68.1	65.7 – 70.4	2528
2	88.1	72.7	64.2	58.6	52.9	50.2 – 55.7	1858
3	77.5	60.9	52.5	46.0	41.3	38.3 – 44.4	1445
4	60.3	40.6	33.5	29.3	26.5	24.5 – 28.6	2459

**FIG. 3.3B.** Five-year, relative survival by "combined" AJCC stage for squamous cell carcinoma of the oral cavity, 1985–1991. (\*95% confidence intervals correspond to year-5 survival rates.)

## BIBLIOGRAPHY

- Byers RM, Weber RS, Andrews T, et al: Frequency and therapeutic implications of "skip metastases" in the neck from squamous carcinoma of the oral tongue. *Head Neck* 19:14-19, 1997
- Cooper JS, Farnan NC, Asbell SO, et al: Recursive partitioning analysis of 2105 patients treated in Radiation Therapy Oncology Group studies of head and neck cancer. *Cancer* 77:1905-1911, 1996
- Cruse CW, Radocha RF: Squamous carcinoma of the lip. *Plast Reconstr Surg* 80:787-791, 1987
- de Leeuw JRI, de Graeff A, Ros WJG, et al: Prediction of depressive symptomatology after treatment of head and neck cancer: the influence of pretreatment physical and depressive symptoms, coping, and social support. *Head and Neck* 22:799-807, 2000
- Deleyiannis FW, Thomas DB, Vaughan TL, et al: Alcoholism: independent predictor of survival in patients with head and neck cancer. *J Natl Cancer Inst* 88:542-549, 1996
- Evans JF, Shah JP: Epidermoid carcinoma of the palate. *Am J Surg* 142:451-455, 1981
- Faye-Lund H, Abdelnoor M: Prognostic factors of survival in a cohort of head and neck cancer patients in Oslo. *Eur J Cancer B Oral Oncol* 2:83-90, 1996
- Franceschi D, Gupta R, Spiro RH, et al: Improved survival in the treatment of squamous carcinoma of the oral tongue. *Am J Surg* 166:360-365, 1992
- Kaplan MH, Feinstein AR: The importance of classifying initial co-morbidity in evaluating the outcome of diabetes mellitus. *J Chron Dis* 27:387-404, 1974
- Karnofsky DA, Abelman WH, Craver LF, Burchenal JH: The use of the nitrogen mustards in the palliative treatment of carcinoma. *Cancer* 1:634-656, 1948
- Krishnan-Nair M, Sankaranarayanan N, Padmanabhan T: Evaluation of the role of radiotherapy in the management of carcinoma of the buccal mucosa. *Cancer* 61:1326-1331, 1988
- McDaniel JS, Dominique L, Musselman L, et al: Depression in patients with cancer. *Psychiatry* 52:89-99, 1995
- Petrovich Z, Krusk H, Tobochnik N, et al: Carcinoma of the lip. *Arch Otolaryngol* 105:187-191, 1979
- Piccirillo JF: Inclusion of comorbidity in a staging system for head and neck cancer. *Oncology* 9:831-836, 1995
- Rodgers LW, Stringer SP, Mendenhall WH, et al: Management of squamous carcinoma of the floor of the mouth. *Head Neck* 15:16-19, 1993
- Shaha AR, Spiro RH, Shah JP, et al: Squamous carcinoma of the floor of the mouth. *Am J Surg* 148:455-459, 1984
- Soo KC, Spiro RH, King W, et al: Squamous carcinoma of the gums. *Am J Surg* 156:281-285, 1988
- Spiro RH, Spiro JD, Strong EW: Surgical approaches to squamous carcinoma confined to the tongue and floor of the mouth. *Head Neck* 9:27-31, 1986
- Totsuka Y, Usui Y, Tei K, et al: Mandibular involvement by squamous cell carcinoma of the lower alveolus: analysis and comparative study of the histologic and radiologic features. *Head Neck* 13:40-50, 1991
- Urist M, O'Brien CJ, Soong SJ, et al: Squamous cell carcinoma of the buccal mucosa: analysis of prognostic factors. *Am J Surg* 154:411-414, 1987
- Wendt CD, Peters LJ, Delclos L, et al: Primary radiotherapy in the treatment of Stage I and II oral tongue cancer: importance of the proportion of therapy delivered with interstitial therapy. *Int J Radiation Oncology Biol Phys* 18:1287-1292, 1990

## HISTOLOGIES—LIP AND ORAL CAVITY

- 8010/2 Carcinoma *in situ*, NOS
- 8010/3 Carcinoma, NOS
- 8012/3 Large cell carcinoma, NOS
- 8013/3 Large cell neuroendocrine carcinoma
- 8020/3 Carcinoma, undifferentiated, NOS
- 8021/3 Carcinoma, anaplastic, NOS
- 8030/3 Giant cell and spindle cell carcinoma
- 8031/3 Giant cell carcinoma
- 8032/3 Spindle cell carcinoma, NOS
- 8033/3 Pseudosarcomatous carcinoma
- 8041/3 Small cell carcinoma, NOS
- 8042/3 Oat cell carcinoma
- 8043/3 Small cell carcinoma, fusiform cell
- 8044/3 Small cell carcinoma, intermediate cell
- 8045/3 Combined small cell carcinoma
- 8051/3 Verrucous carcinoma, NOS
- 8052/2 Papillary squamous cell carcinoma, non-invasive
- 8052/3 Papillary squamous cell carcinoma
- 8070/2 Squamous cell carcinoma *in situ*, NOS
- 8070/3 Squamous cell carcinoma, NOS
- 8071/3 Squamous cell carcinoma, keratinizing, NOS
- 8072/3 Squamous cell carcinoma, large cell
- 8073/3 Squamous cell carcinoma, small cell, non-keratinizing
- 8074/3 Squamous cell carcinoma, spindle cell
- 8075/3 Squamous cell carcinoma, adenoid
- 8076/2 Squamous cell carcinoma *in situ* with questionable stromal invasion
- 8076/3 Squamous cell carcinoma, microinvasive
- 8082/3 Lymphoepithelial carcinoma
- 8083/3 Basaloid squamous cell carcinoma
- 8084/3 Squamous cell carcinoma, clear cell type
- 8090/3 Basal cell carcinoma, NOS
- 8091/3 Multifocal superficial basal cell carcinoma
- 8092/3 Infiltrating basal cell carcinoma, NOS
- 8093/3 Basal cell carcinoma, fibroepithelial
- 8094/3 Basosquamous carcinoma
- 8097/3 Basal cell carcinoma, nodular
- 8098/3 Adenoid basal carcinoma
- 8123/3 Basaloid carcinoma
- 8140/2 Adenocarcinoma *in situ*, NOS
- 8140/3 Adenocarcinoma, NOS
- 8144/3 Adenocarcinoma, intestinal type
- 8145/3 Carcinoma, diffuse type
- 8147/3 Basal cell adenocarcinoma
- 8200/3 Adenoid cystic carcinoma
- 8246/3 Neuroendocrine carcinoma, NOS
- 8310/3 Clear cell adenocarcinoma, NOS
- 8430/3 Mucoepidermoid carcinoma
- 8440/3 Cystadenocarcinoma, NOS
- 8480/3 Mucinous adenocarcinoma
- 8481/3 Mucin-producing adenocarcinoma
- 8510/3 Medullary carcinoma, NOS
- 8525/3 Polymorphous low-grade adenocarcinoma
- 8550/3 Acinar cell carcinoma
- 8560/3 Adenosquamous carcinoma
- 8562/3 Epithelial-myoepithelial carcinoma
- 8574/3 Adenocarcinoma with neuroendocrine differentiation
- 8940/3 Mixed tumor, malignant, NOS
- 8941/3 Carcinoma in pleomorphic adenoma



## LIP AND ORAL CAVITY

**Hospital Name/Address**

---



---



---



---

**Patient Name/Information**

---



---



---



---

Type of Specimen \_\_\_\_\_

Histopathologic Type \_\_\_\_\_

Tumor Size \_\_\_\_\_

Laterality:     Bilateral     Left     Right

### DEFINITIONS

<i>Clinical</i>	<i>Pathologic</i>	<b>Primary Tumor (T)</b>	
<input type="checkbox"/>	<input type="checkbox"/>	TX	Primary tumor cannot be assessed
<input type="checkbox"/>	<input type="checkbox"/>	T0	No evidence of primary tumor
<input type="checkbox"/>	<input type="checkbox"/>	Tis	Carcinoma <i>in situ</i>
<input type="checkbox"/>	<input type="checkbox"/>	T1	Tumor 2 cm or less in greatest dimension
<input type="checkbox"/>	<input type="checkbox"/>	T2	Tumor more than 2 cm but not more than 4 cm in greatest dimension
<input type="checkbox"/>	<input type="checkbox"/>	T3	Tumor more than 4 cm in greatest dimension
<input type="checkbox"/>	<input type="checkbox"/>	T4	(Lip) Tumor invades through cortical bone, inferior alveolar nerve, floor of mouth, or skin of face, i.e., chin or nose <sup>(1)</sup>
<input type="checkbox"/>	<input type="checkbox"/>	T4a	(Oral Cavity) Tumor invades through cortical bone, into deep [extrinsic] muscle of tongue (genioglossus, hyoglossus, palatoglossus, and styloglossus), maxillary sinus, or skin of face
<input type="checkbox"/>	<input type="checkbox"/>	T4b	Tumor involves masticator space, pterygoid plates, or skull base and/or encases internal carotid artery

**Notes**

1. Superficial erosion alone of bone/tooth socket by gingival primary is not sufficient to classify as T4.

<i>Clinical</i>	<i>Pathologic</i>	<b>Regional Lymph Nodes (N)</b>	
<input type="checkbox"/>	<input type="checkbox"/>	NX	Regional lymph nodes cannot be assessed
<input type="checkbox"/>	<input type="checkbox"/>	N0	No regional lymph node metastasis
<input type="checkbox"/>	<input type="checkbox"/>	N1	Metastasis in a single ipsilateral lymph node, 3 cm or less in greatest dimension
<input type="checkbox"/>	<input type="checkbox"/>	N2	Metastasis in a single ipsilateral lymph node, more than 3 cm but not more than 6 cm in greatest dimension; or in multiple ipsilateral lymph nodes, none more than 6 cm in greatest dimension; or in bilateral or contralateral lymph nodes, none more than 6 cm in greatest dimension
<input type="checkbox"/>	<input type="checkbox"/>	N2a	Metastasis in single ipsilateral lymph node more than 3 cm but not more than 6 cm in greatest dimension
<input type="checkbox"/>	<input type="checkbox"/>	N2b	Metastasis in multiple ipsilateral lymph nodes, none more than 6 cm in greatest dimension
<input type="checkbox"/>	<input type="checkbox"/>	N2c	Metastasis in bilateral or contralateral lymph nodes, none more than 6 cm in greatest dimension
<input type="checkbox"/>	<input type="checkbox"/>	N3	Metastasis in a lymph node more than 6 cm in greatest dimension

<i>Clinical</i>	<i>Pathologic</i>	<b>Distant Metastasis (M)</b>	
<input type="checkbox"/>	<input type="checkbox"/>	MX	Distant metastasis cannot be assessed
<input type="checkbox"/>	<input type="checkbox"/>	M0	No distant metastasis
<input type="checkbox"/>	<input type="checkbox"/>	M1	Distant metastasis
		Biopsy of metastatic site performed..... <input type="checkbox"/> Y ..... <input type="checkbox"/> N	
		Source of pathologic metastatic specimen _____	

<i>Clinical</i>	<i>Pathologic</i>	<b>Stage Grouping</b>			
<input type="checkbox"/>	<input type="checkbox"/>	0	Tis	N0	M0
<input type="checkbox"/>	<input type="checkbox"/>	I	T1	N0	M0
<input type="checkbox"/>	<input type="checkbox"/>	II	T2	N0	M0
		III	T3	N0	M0
			T1	N1	M0
			T2	N1	M0
			T3	N1	M0
<input type="checkbox"/>	<input type="checkbox"/>	IVA	T4a	N0	M0
			T4a	N1	M0
			T1	N2	M0
			T2	N2	M0
		IVB	T3	N2	M0
			T4a	N2	M0
<input type="checkbox"/>	<input type="checkbox"/>		Any T	N3	M0
			T4b	Any N	M0
<input type="checkbox"/>	<input type="checkbox"/>	IVC	Any T	Any N	M1

(continued on reverse side)

**Histologic Grade (G)**

- GX Grade cannot be assessed
- G1 Well differentiated
- G2 Moderately differentiated
- G3 Poorly differentiated

**Residual Tumor (R)**

- RX Presence of residual tumor cannot be assessed
- R0 No residual tumor
- R1 Microscopic residual tumor
- R2 Macroscopic residual tumor

**Additional Descriptors**

For identification of special cases of TNM or pTNM classifications, the "m" suffix and "y," "r," and "a" prefixes are used. Although they do not affect the stage grouping, they indicate cases needing separate analysis.

- m suffix** indicates the presence of multiple primary tumors in a single site and is recorded in parentheses: pT(m)NM.
- y prefix** indicates those cases in which classification is performed during or following initial multimodality therapy. The cTNM or pTNM category is identified by a "y" prefix. The ycTNM or ypTNM categorizes the extent of tumor actually present at the time of that examination. The "y" categorization is not an estimate of tumor prior to multimodality therapy.
- r prefix** indicates a recurrent tumor when staged after a disease-free interval, and is identified by the "r" prefix: rTNM.
- a prefix** designates the stage determined at autopsy: aTNM.

**Prognostic Indicators (if applicable)**

**Notes**

**Additional Descriptors**

**Lymphatic Vessel Invasion (L)**  
LX Lymphatic vessel invasion cannot be assessed

L0 No lymphatic vessel invasion

L1 Lymphatic vessel invasion

**Venous Invasion (V)**

VX Venous invasion cannot be assessed

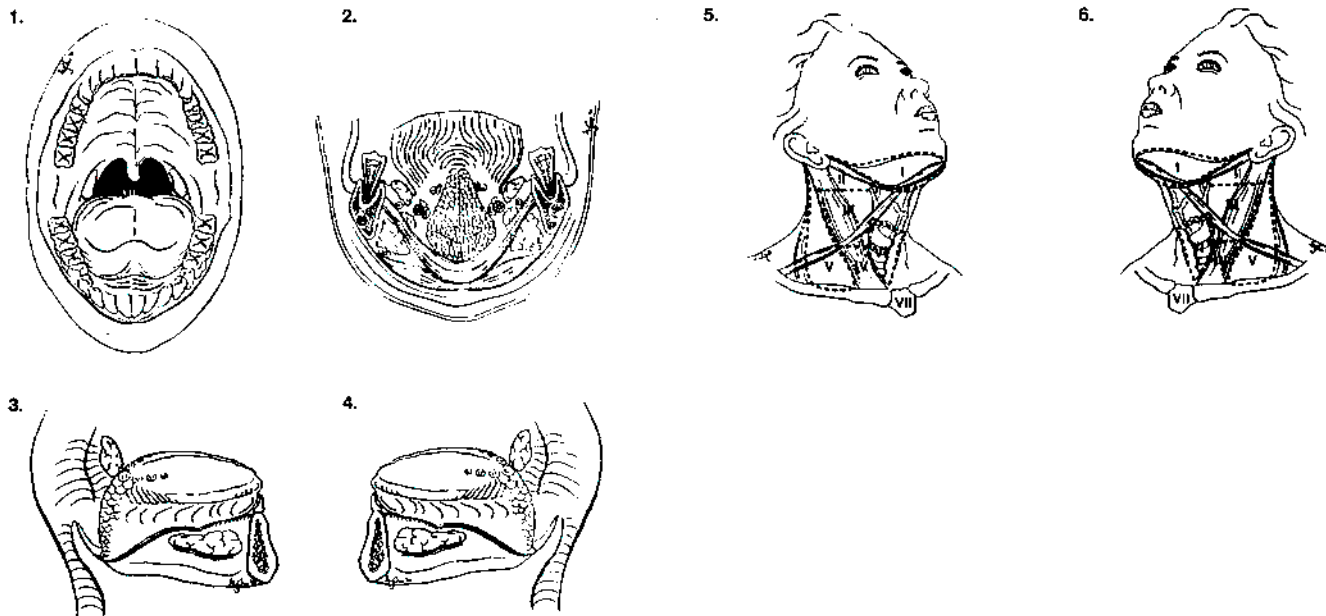
V0 No venous invasion

V1 Microscopic venous invasion

V2 Macroscopic venous invasion

**ILLUSTRATION**

Indicate on diagram primary tumor and regional nodes involved.



Physician's Signature \_\_\_\_\_ Date \_\_\_\_\_

## Pharynx (Including Base of Tongue, Soft Palate, and Uvula)

(Nonepithelial tumors such as those of lymphoid tissue, soft tissue, bone, and cartilage are not included.)

C01.9 Base of tongue, NOS	C10.8 Overlapping lesion	C13.1 Hypopharyngeal aspect of aryepiglottic fold
C02.4 Lingual tonsil	C10.9 Oropharynx, NOS	C13.2 Posterior wall of hypopharynx
C05.1 Soft palate, NOS	C11.0 Superior wall of nasopharynx	C13.8 Overlapping lesion
C05.2 Uvula	C11.1 Posterior wall of nasopharynx	C13.9 Hypopharynx, NOS
C09.0 Tonsillar fossa	C11.2 Lateral wall of nasopharynx	C14.0 Pharynx, NOS
C09.1 Tonsillar pillar	C11.3 Anterior wall of nasopharynx	C14.2 Waldeyer's ring
C09.8 Overlapping lesion	C11.8 Overlapping lesion	C14.8 Overlapping lesion of lip, oral cavity and pharynx
C09.9 Tonsil, NOS	C11.9 Nasopharynx, NOS	
C10.0 Vallecula	C12.9 Pyramidal sinus	
C10.2 Lateral wall of oropharynx	C13.0 Postcricoid region	
C10.4 Branchial cleft		

### SUMMARY OF CHANGES

- For oropharynx and hypopharynx only, T4 lesions have been divided into T4a (resectable) and T4b (unresectable), leading to the division of Stage IV into Stage IVA, Stage IVB, and Stage IVC.

### ANATOMY

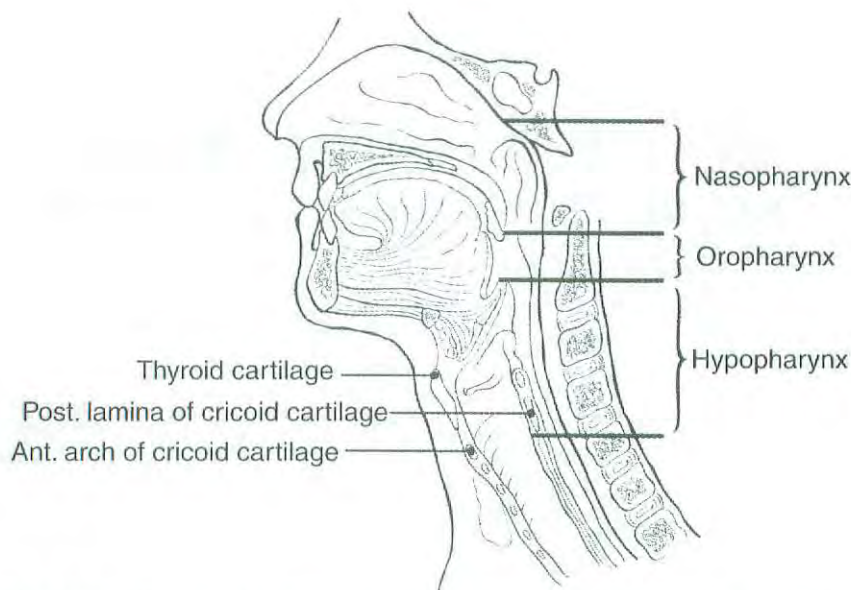
**Primary Sites and Subsites.** The pharynx (including base of tongue, soft palate, and uvula) is divided into three regions: nasopharynx, oropharynx and hypopharynx (Fig. 4.1). Each region is further subdivided into specific sites as summarized in the following:

**Nasopharynx.** The nasopharynx begins anteriorly at the posterior choana and extends along the plane of the airway to the level of the free border of the soft palate. It includes the vault, the lateral walls (including the fossae of Rosenmuller and the mucosa covering the torus tubaris forming the eustachian tube orifice), and the posterior wall. The floor is the superior surface of the soft palate. The posterior margins of the choanal orifices and of the nasal septum are included in the nasal fossa.

**Parapharyngeal** involvement denotes posterolateral infiltration of tumor beyond the pharyngobasilar fascia. Involvement of the masticator space denotes extension of tumor beyond the anterior surface of the lateral pterygoid muscle, or lateral extension beyond the posterolateral wall of the maxillary antrum, and the pterygomaxillary fissure.

**Oropharynx.** The oropharynx is the portion of the continuity of the pharynx extending from the plane of the superior surface of the soft palate to the superior surface of the hyoid bone (or floor of the vallecula). It includes the base of the tongue, the inferior (anterior) surface of the soft palate and the uvula, the anterior and posterior tonsillar pillars, the glossotonsillar sulci, the pharyngeal tonsils, and the lateral and posterior pharyngeal walls.

**Hypopharynx.** The hypopharynx is that portion of the pharynx extending from the plane of the superior border of the hyoid bone (or floor of the vallecula) to the plane corresponding to the lower border of the cricoid cartilage. It includes the pyriform sinuses (right and left), the lateral and posterior hypopharyngeal walls, and the postcricoid region. The postcricoid area extends from the level of the arytenoid cartilages and connecting folds to the inferior border of the cricoid cartilage. It connects the two pyriform sinuses, thus forming the anterior wall of the hypopharynx. The pyriform sinus extends from the pharyngoepiglottic fold to the upper end of the esophagus at the lower border of the cricoid cartilage and is bounded laterally by the lateral pharyngeal wall and medially by the lateral surface of the aryepiglottic fold



**FIG. 4.1.** Sagittal view of the face and neck depicting the subdivisions of the pharynx as described in the text.

and the arytenoid and cricoid cartilages. The posterior pharyngeal wall extends from the level of the superior surface of the **hyoid bone** (or floor of the vallecula) to the inferior border of the cricoid cartilage and from the apex of one pyriform sinus to the other.

**Regional Lymph Nodes.** The risk of regional nodal spread from cancers of the pharynx is high. Primary nasopharyngeal tumors commonly spread to retropharyngeal, upper jugular, and spinal accessory nodes, often bilaterally. Oropharyngeal cancers involve upper and mid-jugular lymph nodes and (less commonly) submental/submandibular nodes. Hypopharyngeal cancers spread to adjacent parapharyngeal, paratracheal, and mid- and lower jugular nodes. Bilateral lymphatic drainage is common.

In clinical evaluation, the maximum size of the nodal mass should be measured. Most masses over 3 cm in diameter are not single nodes but, rather, are confluent nodes or tumor in soft tissues of the neck. There are three categories of clinically involved nodes for the nasopharynx, oropharynx, and hypopharynx: N1, N2, and N3. The use of subgroups a, b, and c is not required but is recommended. Midline nodes are considered ipsilateral nodes. In addition to the components to describe the N category, regional lymph nodes should also be described according to the level of the neck that is involved. The level of involved nodes in the neck is prognostically significant (lower is worse), as is the presence of extracapsular extension of metastatic tumor from individual nodes. Imaging studies showing amorphous spiculated margins of involved nodes or involvement of internodal fat resulting in loss of normal oval-to-round nodal shape strongly suggest extracapsular (extranodal) tumor spread; however, pathologic examination is necessary for documentation of such disease extent. No imaging study (as

yet) can identify microscopic foci in regional nodes or distinguish between small reactive nodes and small malignant nodes (unless central radiographic inhomogeneity is present).

For pN, a selective neck dissection will ordinarily include 6 or more lymph nodes, and a radical or modified radical neck dissection will ordinarily include 10 or more lymph nodes. Negative pathologic examination of a lesser number of nodes still mandates a pN0 designation.

**Metastatic Sites.** The lungs are the commonest site of distant metastases; skeletal or hepatic metastases occur less often. Mediastinal lymph node metastases are considered distant metastases.

## RULES FOR CLASSIFICATION

**Clinical Staging.** Clinical staging is generally employed for squamous cell carcinomas of the pharynx. Assessment is based primarily on inspection and on indirect and direct endoscopy. Palpation of sites (when feasible) and of neck nodes is essential. Neurologic evaluation of all cranial nerves is required. Imaging studies are essential in clinical staging of pharynx tumors. Cross-sectional imaging in nasopharyngeal cancer is mandatory to complete the staging process. Magnetic resonance imaging (MRI) often is the study of choice because of its multiplanar capability, superior soft tissue contrast, and sensitivity for skull base and intracranial tumor spread. Computed tomography (CT) imaging with axial and coronal thin section technique with contrast is an alternative. Radiologic nodal staging should be done to assess adequately the retropharyngeal and cervical nodal status.

Cross-sectional imaging in oropharyngeal carcinoma is recommended when the deep tissue extent of the primary tumor is in question. CT or MRI may be employed. Cross-sectional imaging of hypopharyngeal carcinoma is recommended when the extent of the primary tumor is in doubt, particularly its deep extent in relationship to adjacent structures (i.e., larynx, thyroid, cervical vertebrae, and carotid sheath). CT is preferred currently because it entails less motion artifact than MRI. Radiologic nodal staging should be done simultaneously. Complete endoscopy, usually under general anesthesia, is performed after completion of other staging studies, to assess the surface extent of the tumor accurately and to assess deep involvement by palpation for muscle invasion and to facilitate biopsy. A careful search for other primary tumors of the upper aerodigestive tract is indicated because of the incidence of multiple independent primary tumors occurring simultaneously.

**Pathologic Staging.** Pathologic staging requires the use of all information obtained in clinical staging and in histologic study of the surgically resected specimen. The surgeon's evaluation of gross unresected residual tumor must also be included. The pathologic description of any lymphadenectomy specimen should describe the size, number, and level of any involved nodes and the presence or absence of extracapsular extension.

**DEFINITION OF TNM**

**Primary Tumor (T)**

- TX Primary tumor cannot be assessed
- T0 No evidence of primary tumor
- Tis Carcinoma *in situ*

**Nasopharynx**

- T1 Tumor confined to the nasopharynx
- T2 Tumor extends to soft tissues
  - T2a Tumor extends to the oropharynx and/or nasal cavity without parapharyngeal extension\*
  - T2b Any tumor with parapharyngeal extension\*
- T3 Tumor involves bony structures and/or paranasal sinuses
- T4 Tumor with intracranial extension and/or involvement of cranial nerves, infratemporal fossa, hypopharynx, orbit, or masticator space

\*Note: Parapharyngeal extension denotes posterolateral infiltration of tumor beyond the pharyngobasilar fascia.

**Oropharynx**

- T1 Tumor 2 cm or less in greatest dimension
- T2 Tumor more than 2 cm but not more than 4 cm in greatest dimension
- T3 Tumor more than 4 cm in greatest dimension

- T4a Tumor invades the larynx, deep/extrinsic muscle of tongue, medial pterygoid, hard palate, or mandible
- T4b Tumor invades lateral pterygoid muscle, pterygoid plates, lateral nasopharynx, or skull base or encases carotid artery

**Hypopharynx**

- T1 Tumor limited to one subsite of hypopharynx and 2 cm or less in greatest dimension
- T2 Tumor invades more than one subsite of hypopharynx or an adjacent site, or measures more than 2 cm but not more than 4 cm in greatest diameter without fixation of hemilarynx
- T3 Tumor more than 4 cm in greatest dimension or with fixation of hemilarynx
- T4a Tumor invades thyroid/cricoid cartilage, hyoid bone, thyroid gland, esophagus, or central compartment soft tissue\*
- T4b Tumor invades prevertebral fascia, encases carotid artery, or involves mediastinal structures

\*Note: Central compartment soft tissue includes prelaryngeal strap muscles and subcutaneous fat.

**Regional Lymph Nodes (N)**

**Nasopharynx**

The distribution and the prognostic impact of regional lymph node spread from nasopharynx cancer, particularly of the undifferentiated type, are different from those of other head and neck mucosal cancers and justify the use of a different N classification scheme.

- NX Regional lymph nodes cannot be assessed
- N0 No regional lymph node metastasis
- N1 Unilateral metastasis in lymph node(s), 6 cm or less in greatest dimension, above the supraclavicular fossa\*
- N2 Bilateral metastasis in lymph node(s), 6 cm or less in greatest dimension, above the supraclavicular fossa\*
- N3 Metastasis in a lymph node(s)\* >6 cm and/or to supraclavicular fossa
  - N3a Greater than 6 cm in dimension
  - N3b Extension to the supraclavicular fossa\*\*

\*Note: Midline nodes are considered ipsilateral nodes.

\*\*Supraclavicular zone or fossa is relevant to the staging of nasopharyngeal carcinoma and is the triangular region originally described by Ho. It is defined by three points: (1) the superior margin of the sternal end of the clavicle, (2) the superior margin of the lateral end of the clavicle, (3) the point where the neck meets the shoulder (see Fig. 4.2). Note that this would include caudal portions of Levels IV and V. All cases with lymph nodes (whole or part) in the fossa are considered N3b.

*Oropharynx and Hypopharynx*

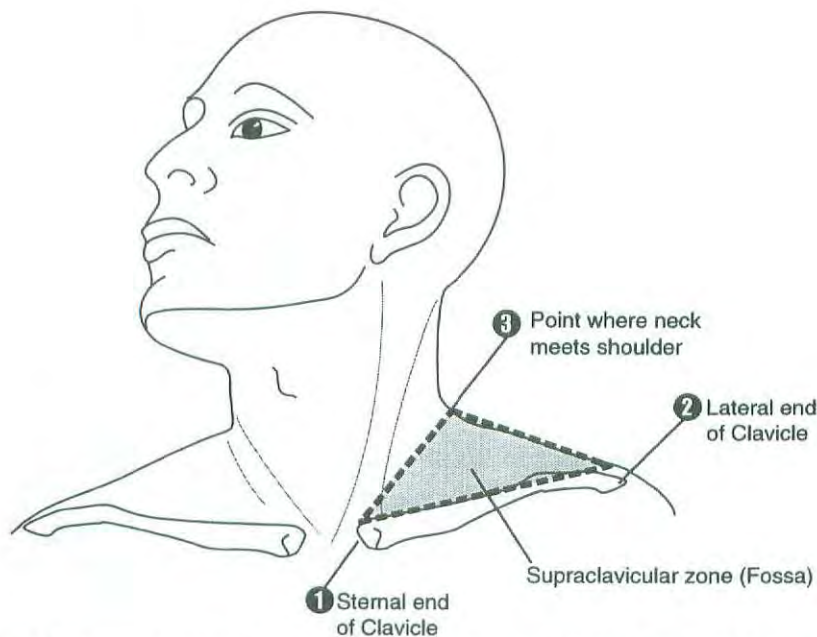
- NX Regional lymph nodes cannot be assessed
- N0 No regional lymph node metastasis
- N1 Metastasis in a single ipsilateral lymph node, 3 cm or less in greatest dimension
- N2 Metastasis in a single ipsilateral lymph node, more than 3 cm but not more than 6 cm in greatest dimension, or in multiple ipsilateral lymph nodes, none more than 6 cm in greatest dimension, or in bilateral or contralateral lymph nodes, none more than 6 cm in greatest dimension
- N2a Metastasis in a single ipsilateral lymph node more than 3 cm but not more than 6 cm in greatest dimension
- N2b Metastasis in multiple ipsilateral lymph nodes, none more than 6 cm in greatest dimension
- N2c Metastasis in bilateral or contralateral lymph nodes, none more than 6 cm in greatest dimension
- N3 Metastasis in a lymph node more than 6 cm in greatest dimension

**STAGE GROUPING: NASOPHARYNX**

Stage 0	Tis	N0	M0
Stage I	T1	N0	M0
Stage IIA	T2a	N0	M0
Stage IIB	T1	N1	M0
	T2	N1	M0
	T2a	N1	M0
	T2b	N0	M0
Stage III	T2b	N1	M0
	T1	N2	M0
	T2a	N2	M0
	T2b	N2	M0
Stage IVA	T3	N0	M0
	T3	N1	M0
	T3	N2	M0
	T4	N0	M0
Stage IVB	T4	N1	M0
	T4	N2	M0
	T4	N2	M0
Stage IVB	Any T	N3	M0
Stage IVC	Any T	Any N	M1

**Distant Metastasis (M)**

- MX Distant metastasis cannot be assessed
- M0 No distant metastasis
- M1 Distant metastasis



**FIG. 4.2.** Shaded triangular area corresponds to the supraclavicular fossa used in staging carcinoma of the nasopharynx.

### STAGE GROUPING: OROPHARYNX, HYPOPHARYNX

Stage 0	Tis	N0	M0
Stage I	T1	N0	M0
Stage II	T2	N0	M0
Stage III	T3	N0	M0
	T1	N1	M0
	T2	N1	M0
Stage IVA	T3	N1	M0
	T4a	N0	M0
	T4a	N1	M0
	T1	N2	M0
	T2	N2	M0
Stage IVB	T3	N2	M0
	T4a	N2	M0
	T4b	Any N	M0
Stage IVC	Any T	N3	M0
	Any T	Any N	M1

### PROGNOSTIC FACTORS

In addition to the importance of the TNM factors outlined previously, the overall health of these patients clearly influences outcome. Comorbidity can be classified by more general measures, such as the Karnofsky performance score, or by more specific measures, such as the Kaplan-Feinstein Index. Continued exposure to carcinogens, such as alcohol and tobacco smoke, probably affects patients' outcomes adversely.

Figures 4.3A, 4.3B, 4.4A, 4.4B, 4.5A, and 4.5B show observed and relative survival rates for patients with squamous cell carcinoma of the Oropharynx (4.3A,B), squamous cell carcinoma of the nasopharynx (4.4A,B), and squamous cell carcinoma of the hypopharynx (4.5A,B) for the years 1985–1991, classified by the AJCC staging classification.

### HISTOPATHOLOGIC TYPE

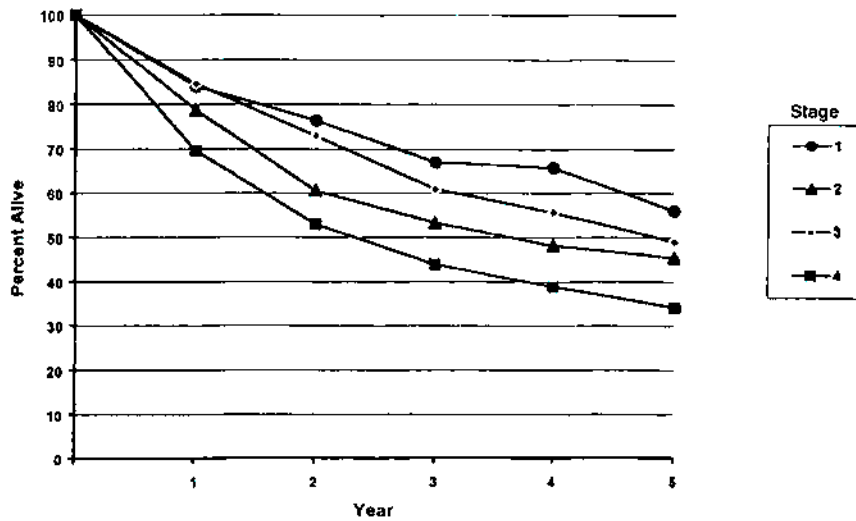
The predominant cancer type is squamous cell carcinoma for all pharyngeal sites. Non-epithelial tumors such as those of lymphoid tissue, soft tissue, bone, and cartilage are not included in this system. For nasopharyngeal carcinomas, it is recommended that the World Health Organization (WHO) classification be used (Table 4.1). Histologic diagnosis is necessary to use this classification.

### HISTOLOGIC GRADE (G): OROPHARYNX, HYPOPHARYNX

- GX Grade cannot be assessed
- G1 Well differentiated
- G2 Moderately differentiated
- G3 Poorly differentiated

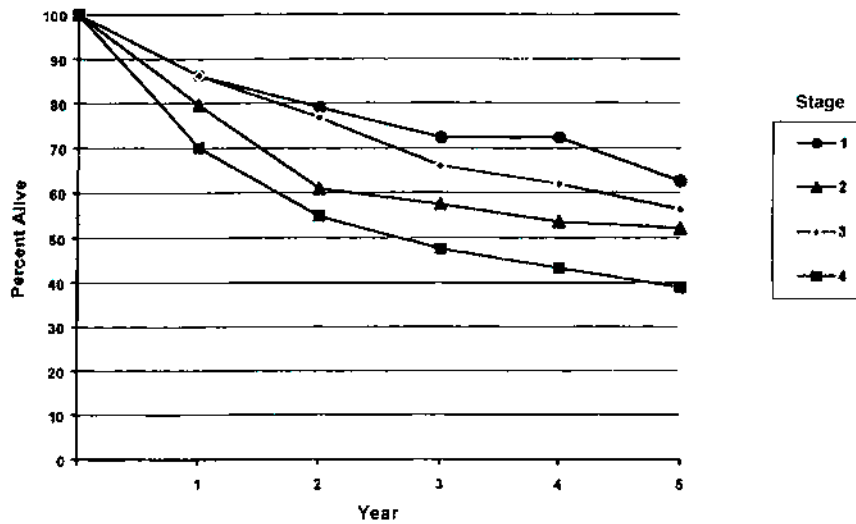
**TABLE 4.1.** Classification of Nasopharyngeal Carcinoma

<i>WHO Classification</i>	<i>Former Terminology</i>
Type 1. Squamous cell carcinoma	Squamous cell carcinoma
Type 2. Nonkeratinizing carcinoma	Transitional cell carcinoma
Without lymphoid stroma	Intermediate cell carcinoma
With lymphoid stroma	Lymphoepithelial carcinoma (Regaud)
Type 3. Undifferentiated carcinoma	Anaplastic carcinoma,
Without lymphoid stroma	Clear cell carcinoma
With lymphoid stroma	Lymphoepithelial carcinoma (Schminke)



OBSERVED SURVIVAL BY STAGE	1	2	3	4	5	95% Cis*	CASES
1	84.1	76.4	66.9	65.7	56.0	45.6 - 66.3	104
2	78.7	60.5	53.2	48.1	45.4	34.8 - 56.0	96
3	84.6	72.9	60.9	55.6	49.0	41.8 - 56.0	205
4	69.6	52.9	43.9	38.8	34.1	30.2 - 37.9	665

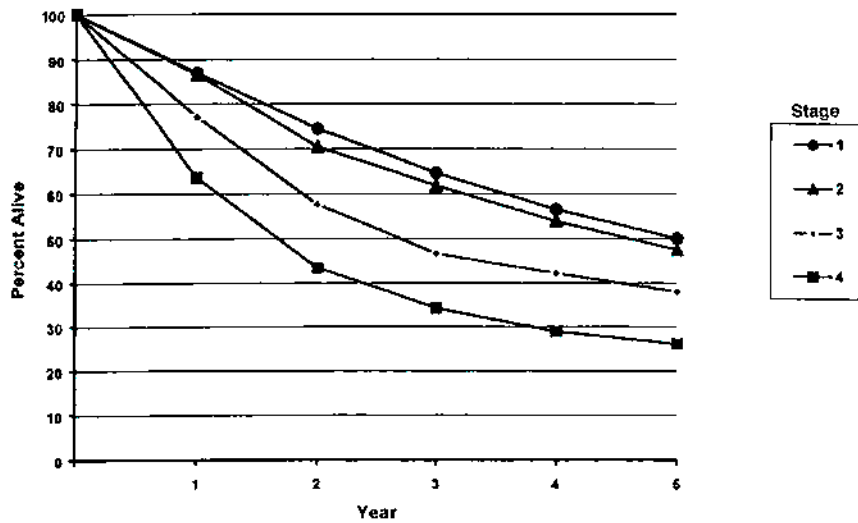
FIG. 4.3A. Five-year, observed survival by "combined" AJCC stage for squamous cell carcinoma of the nasopharynx, 1985-1991. (\*95% confidence intervals correspond to year-5 survival rates.)



RELATIVE SURVIVAL BY STAGE	1	2	3	4	5	95% Cis*	CASES
1	86.2	79.0	72.3	72.3	62.5	50.5 - 74.5	104
2	79.6	60.9	57.4	53.6	52.1	39.9 - 64.3	96
3	86.2	76.7	65.9	61.9	56.3	48.1 - 64.4	205
4	70.1	54.8	47.6	43.3	38.9	34.6 - 43.3	669

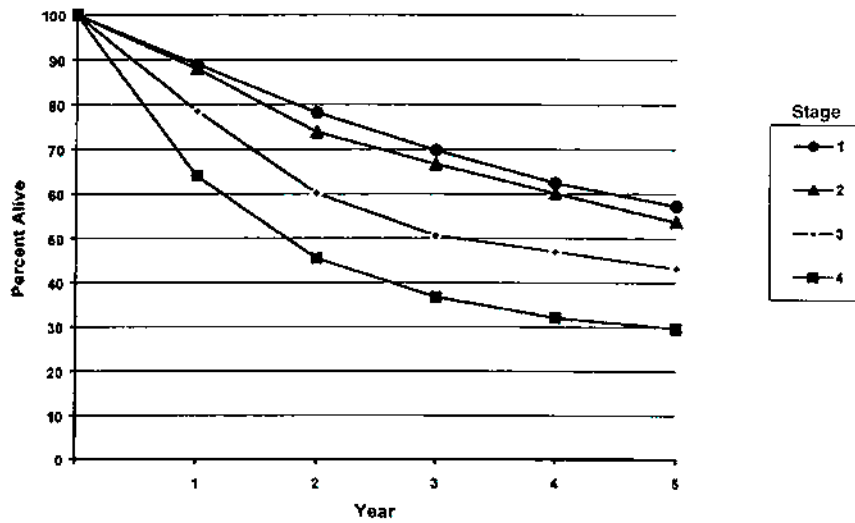
FIG. 4.3B. Five-year, relative survival by "combined" AJCC stage for squamous cell carcinoma of the nasopharynx, 1985-1991. (\*95% confidence intervals correspond to year-5 survival rates.)





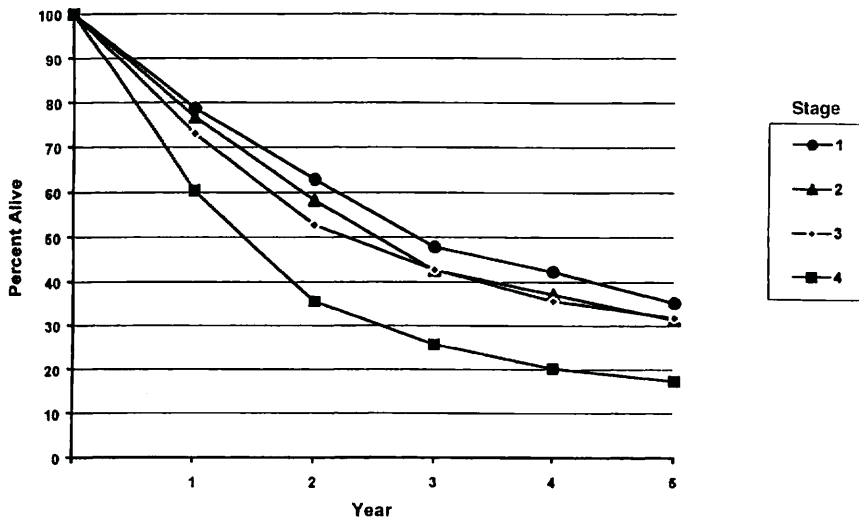
OBSERVED SURVIVAL BY STAGE	1	2	3	4	5	95% CIs*	CASES
1	87.0	74.4	64.6	56.5	50.0	46.7 - 53.4	980
2	86.6	70.4	61.8	53.9	47.5	44.3 - 50.6	1107
3	77.1	57.6	46.7	42.2	37.9	35.3 - 40.4	1529
4	63.6	43.5	34.2	28.9	26.1	24.5 - 27.6	3419

FIG. 4.4A. Five-year, observed survival by "combined" AJCC stage for squamous cell carcinoma of the oropharynx, 1985-1991. (\*95% confidence intervals correspond to year-5 survival rates.)



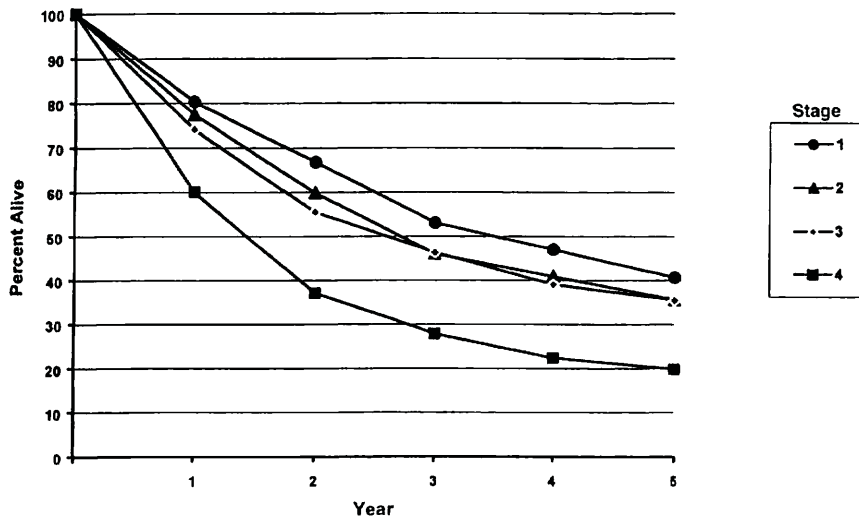
RELATIVE SURVIVAL BY STAGE	1	2	3	4	5	95% CIs*	CASES
1	88.9	78.1	69.8	62.4	57.3	53.5 - 61.2	986
2	87.9	73.8	66.6	60.1	53.7	50.1 - 57.3	1118
3	78.5	60.1	50.6	47.0	43.2	40.3 - 46.2	1541
4	64.0	45.5	38.7	32.0	29.6	27.8 - 31.3	3451

FIG. 4.4B. Five-year, relative survival by "combined" AJCC stage for squamous cell carcinoma of the oropharynx, 1985-1991. (\*95% confidence intervals correspond to year-5 survival rates.)



OBSERVED SURVIVAL BY STAGE	1	2	3	4	5	95% CIs*	CASES
1	78.7	62.8	47.8	42.3	35.2	29.4 – 41.0	299
2	76.7	58.2	42.6	37.1	31.3	26.1 – 36.6	345
3	73.0	52.7	42.7	35.6	31.8	27.9 – 35.6	617
4	60.4	35.5	25.7	20.2	17.4	15.5 – 19.2	1671

FIG. 4.5A. Five-year, observed survival by “combined” AJCC stage for squamous cell carcinoma of the hypopharynx, 1985–1991. (\*95% confidence intervals correspond to year-5 survival rates.)



RELATIVE SURVIVAL BY STAGE	1	2	3	4	5	95% CIs*	CASES
1	80.3	66.7	53.0	47.0	40.7	31.4 – 47.4	304
2	77.5	59.8	46.0	40.9	35.6	29.6 – 41.6	350
3	74.1	55.5	46.3	39.0	35.5	31.1 – 39.8	620
4	60.1	37.1	27.9	22.4	19.9	17.7 – 22.0	1688

FIG. 4.5B. Five-year, relative survival by “combined” AJCC stage for squamous cell carcinoma of the hypopharynx, 1985–1991. (\*95% confidence intervals correspond to year-5 survival rates.)

## BIBLIOGRAPHY

- Boyd TS, Harari PM, Tannehill SP, Voytovich MC, Hartig GK, Ford CN, Foote RL, Campbell BH, Schultz CJ: Planned post-radiotherapy neck dissection in patients with advanced head and neck cancer. *Head Neck* 29:132-137, 1998
- Chong V, Mukherji S, Ng S-H, et al: Nasopharyngeal carcinoma; review of how imaging affects staging. *J Computer Assisted Tomography* 23:984-993, 1999
- Chua D, Sham J, Kwong D, et al: Prognostic value of paranasopharyngeal extension of nasopharyngeal carcinoma. A significant factor in local control and distant metastasis. *Cancer* 78:202-210, 1996
- Colangelo LA, Logemann JA, Pauloski BR, Pelzer JR, Rademaker AW: T stage and functional outcome in oral and oropharyngeal cancer patients. *Head Neck* 18:259-268, 1996
- Cooper J, Cohen R, Stevens R: A comparison of staging systems for nasopharyngeal carcinoma. *Cancer* 83:213-219, 1998
- Deleyiannis FW, Weymuller EA Jr, Coltrera MD: Quality of life of disease-free survivors of advanced (Stage III or IV) oropharyngeal cancer. *Head Neck* 19:466-473, 1997
- Forastiere AA, Trotti A: Radiotherapy and concurrent chemotherapy: a strategy that improves locoregional control and survival in oropharyngeal cancer. *J Nat Cancer Inst* 91:2065-2066, 1999
- Garden AS, Morrison WH, Clayman GL, Ang KK, Peters LJ: Early squamous cell carcinoma of the hypopharynx: outcomes of treatment with radiation alone to the primary disease. *Head Neck* 18:317-22, 1996
- Gwozdz JT, Morrison WH, Garden AS, Weber RS, Peters LJ, Ang KK: Concomitant boost radiotherapy for squamous carcinoma of the tonsillar fossa. *Int J Rad Onc Biol Phys* 39:127-135, 1997
- Harrison LB, Lee HJ, Pfister DG, Kraus DH, White C, Raben A, Zelefsky MJ, Strong EW, Shah JP: Long-term results of primary radiotherapy with/without neck dissection for squamous cell cancer of the base of the tongue. *Head Neck* 20:668-673, 1998
- Ho J: Stage classification of nasopharyngeal carcinoma, etiology and control. IARC Scientific Publications 20:99-113, 1978
- Hoffman HT, Karnell LH, Shah JP, Ariyan S, Brown GS, Fee WE, Glass AG, Goepfert H, Ossoff RH, Fremgen AM: Hypopharyngeal cancer patient care evaluation. *Laryngoscope* 107:1005-1017, 1997
- Hoffman HT, Karnell LH, Funk GF, Robinson RA, Menck HR: The National Cancer Data Base report on cancer of the head and neck. *Arch Otolaryngol-Head Neck Surg* 951-962, 1998
- Iro H, Waldfahrer F: Evaluation of the newly updated TNM classification of head and neck carcinoma with data from 3,247 patients. *Cancer* 83:2201-2207, 1998
- Kraus DH, Zelefsky MJ, Brock HA, Huo J, Harrison LB, Shah JP: Combined surgery and radiation therapy for squamous cell carcinoma of the hypopharynx. *Otolaryngol-HN Surg* 116, 637-641, 1997
- Lee A, Foo W, Law S, et al: N-staging of nasopharyngeal carcinoma: Discrepancy between UICC/AJCC and Ho systems. *Clinical Oncology* 17:377-381, 1995
- Lefebvre JL, Buisset E, Coche-Dequeant B, Van JT, Prevost B, Hecquet B, Damaillé A: Epilarynx: pharynx or larynx? *Head Neck* 17:377-381, 1995
- Lefebvre JL, Chevalier D, Luboinski B, Kirkpatrick A, Collette L, Sahnoud T: Larynx preservation in pyriform sinus cancer: preliminary results of a European Organization for Research Treatment of Cancer phase III trial. EORTC Head and Neck Cancer Cooperative Group. *J Nat Cancer Inst* 88:890-899, 1996
- Mendenhall WM, Amdur RJ, Stringer SP, Villaret DB, Cassisi NJ: Stratification of stage IV squamous cell carcinoma of the oropharynx. *Head Neck* 22:626-628, 2000
- Pauloski BR, Logemann JA, Colangelo LA, Rademaker AW, McConnel FM, Heiser MA, Carndinale S, Shedd D, Stein D, Beery Q, Myers E, Lewin J, Haxer M, Esclamado R: Surgical variables affecting speech in treated patients with oral and oropharyngeal cancer. *Laryngoscope* 108:908-916, 1998
- Perez CA, Patel MM, Chao KS, Simpson JR, Sessions D, Spector GJ, Haughey B, Lockett MA: Carcinoma of the tonsillar fossa: prognostic factors and long-term therapy outcome. *Int J Rad Onc Biol Phys* 42:1077-1084, 1998
- Prehn RB, Pasic TR, Harari PM, Brown WD, Ford CN: Influence of computed tomography on pretherapeutic tumor staging of head and neck cancer patients. *Otolaryngol-Head Neck Surg* 199:628-633, 1998
- Pugliano FA, Piccirillo JF, Zequeira MR, Emami B, Perez CA, Simpson JR, Frederickson JM: Clinical-severity staging system for oropharyngeal cancer: five-year survival rates. *Arch Otolaryngol-Head Neck Surg* 123:1118-1124, 1997
- Righi PD, Kelley DJ, Ernst R, Deutsch MD, Gaskill-Shipley M, Wilson KM, Gluckman JL: Evaluation of prevertebral muscle invasion by squamous cell carcinoma. Can computed tomography replace open neck exploration? *Arch Otolaryngol-Head Neck Surg* 122:660-663, 1996
- Teresi L, Lufkin R, Vinuela F, et al: MR imaging of the nasopharynx and floor of the middle cranial fossa. Part II. Malignant Tumors. *Radiol* 164:817-821, 1987
- Thabet HM, Sessions DG, Gado MY, Gnepp DA, Harvey JE, Talaat M: Comparison of clinical evaluation and computed tomographic diagnostic accuracy for tumor of the larynx and hypopharynx. *Laryngoscope* 106:589-594, 1996
- Veneroni S, Silvestrini R, Costa A, Salvatori P, Faranda A, Monlinari R: Biological indicators of survival in patients treated by surgery for squamous cell carcinoma of the oral cavity and oropharynx. *Oral Oncol* 33:408-413, 1997
- Wang MB, Kuber MM, Lee SP, Julliard GF, Abemayor E: Tonsillar carcinoma: analysis of treatment results. *J Otolaryngol* 27:263-269, 1998
- Wahlberg PC, Andersson KE, Björklund AT, Moller TR: Carcinoma of the hypopharynx: analysis of incidence and survival in Sweden over a 30-year period. *Head Neck* 20:714-719, 1998
- Weber RS, Gidley P, Morrison WH, Peters LJ, Hankins PD, Wolf P, Guillaumondegui OM: Treatment selection for carcinoma of the base of the tongue. *Am J Surg* 60:415-419, 1990
- Zelefsky MJ, Kraus DH, Pfister DG, Raben A, Shah JP, Strong EW, Spiro RH, Bosl GJ, Harrison LB: Combined chemotherapy and radiotherapy versus surgical and postoperative radiotherapy for advanced hypopharyngeal cancer. *Head Neck* 18:405-411, 1996

## HISTOLOGIES—PHARYNX

8010/2	Carcinoma <i>in situ</i> , NOS	8082/3	Lymphoepithelial carcinoma
8010/3	Carcinoma, NOS	8083/3	Basaloid squamous cell carcinoma
8012/3	Large cell carcinoma, NOS	8084/3	Squamous cell carcinoma, clear cell type
8013/3	Large cell neuroendocrine carcinoma	8090/3	Basal cell carcinoma, NOS
8020/3	Carcinoma, undifferentiated, NOS	8091/3	Multifocal superficial basal cell carcinoma
8021/3	Carcinoma, anaplastic, NOS	8092/3	Infiltrating basal cell carcinoma, NOS
8030/3	Giant cell and spindle cell carcinoma	8093/3	Basal cell carcinoma, fibroepithelial
8031/3	Giant cell carcinoma	8094/3	Basosquamous carcinoma
8032/3	Spindle cell carcinoma, NOS	8097/3	Basal cell carcinoma, nodular
8033/3	Pseudosarcomatous carcinoma	8098/3	Adenoid basal carcinoma
8041/3	Small cell carcinoma, NOS	8123/3	Basaloid carcinoma
8042/3	Oat cell carcinoma	8140/2	Adenocarcinoma <i>in situ</i> , NOS
8043/3	Small cell carcinoma, fusiform cell	8140/3	Adenocarcinoma, NOS
8044/3	Small cell carcinoma, intermediate cell	8144/3	Adenocarcinoma, intestinal type
8045/3	Combined small cell carcinoma	8145/3	Carcinoma, diffuse type
8051/3	Verrucous carcinoma, NOS	8147/3	Basal cell adenocarcinoma
8052/2	Papillary squamous cell carcinoma, non-invasive	8200/3	Adenoid cystic carcinoma
8052/3	Papillary squamous cell carcinoma	8246/3	Neuroendocrine carcinoma, NOS
8070/2	Squamous cell carcinoma <i>in situ</i> , NOS	8310/3	Clear cell adenocarcinoma, NOS
8070/3	Squamous cell carcinoma, NOS	8430/3	Mucoepidermoid carcinoma
8071/3	Squamous cell carcinoma, keratinizing, NOS	8440/3	Cystadenocarcinoma, NOS
8072/3	Squamous cell carcinoma, large cell	8480/3	Mucinous adenocarcinoma
8073/3	Squamous cell carcinoma, small cell, non-keratinizing	8481/3	Mucin-producing adenocarcinoma
8074/3	Squamous cell carcinoma, spindle cell	8510/3	Medullary carcinoma, NOS
8075/3	Squamous cell carcinoma, adenoid	8525/3	Polymorphous low-grade adenocarcinoma
8076/2	Squamous cell carcinoma <i>in situ</i> with questionable stromal invasion	8550/3	Acinar cell carcinoma
8076/3	Squamous cell carcinoma, microinvasive	8560/3	Adenosquamous carcinoma
		8562/3	Epithelial-myoepithelial carcinoma
		8574/3	Adenocarcinoma with neuroendocrine differentiation
		8940/3	Mixed tumor, malignant, NOS
		8941/3	Carcinoma in pleomorphic adenoma

## PHARYNX (INCLUDING BASE OF TONGUE, SOFT PALATE, AND UVULA)

**Hospital Name/Address**

---



---



---

**Patient Name/Information**

---



---



---

2

Type of Specimen \_\_\_\_\_

Histopathologic Type \_\_\_\_\_

Tumor Size \_\_\_\_\_

Laterality:     Bilateral     Left     Right

### DEFINITIONS

Clinical	Pathologic		Primary Tumor (T)
<input type="checkbox"/>	<input type="checkbox"/>	TX	Primary tumor cannot be assessed
<input type="checkbox"/>	<input type="checkbox"/>	T0	No evidence of primary tumor
<input type="checkbox"/>	<input type="checkbox"/>	Tis	Carcinoma <i>in situ</i>
<i>Nasopharynx</i>			
<input type="checkbox"/>	<input type="checkbox"/>	T1	Tumor confined to the nasopharynx
<input type="checkbox"/>	<input type="checkbox"/>	T2	Tumor extends to soft tissues
<input type="checkbox"/>	<input type="checkbox"/>	T2a	Tumor extends to the oropharynx and/or nasal cavity without parapharyngeal extension <sup>(1)</sup>
<input type="checkbox"/>	<input type="checkbox"/>	T2b	Any tumor with parapharyngeal extension <sup>(1)</sup>
<input type="checkbox"/>	<input type="checkbox"/>	T3	Tumor involves bony structures and/or paranasal sinuses
<input type="checkbox"/>	<input type="checkbox"/>	T4	Tumor with intracranial extension and/or involvement of cranial nerves, infra-temporal fossa, hypopharynx, orbit, or masticator space
<i>Oropharynx</i>			
<input type="checkbox"/>	<input type="checkbox"/>	T1	Tumor 2 cm or less in greatest dimension
<input type="checkbox"/>	<input type="checkbox"/>	T2	Tumor more than 2 cm but not more than 4 cm in greatest dimension
<input type="checkbox"/>	<input type="checkbox"/>	T3	Tumor more than 4 cm in greatest dimension
<input type="checkbox"/>	<input type="checkbox"/>	T4a	Tumor invades the larynx, deep/extrinsic muscle of tongue, medial pterygoid, hard palate, or mandible
<input type="checkbox"/>	<input type="checkbox"/>	T4b	Tumor invades lateral pterygoid muscle, pterygoid plates, lateral nasopharynx, or skull base or encases carotid artery
<i>Hypopharynx</i>			
<input type="checkbox"/>	<input type="checkbox"/>	T1	Tumor limited to one subsite of hypopharynx and 2 cm or less in greatest dimension
<input type="checkbox"/>	<input type="checkbox"/>	T2	Tumor invades more than one subsite of hypopharynx or an adjacent site, or measures more than 2 cm but not more than 4 cm in greatest diameter without fixation of hemilarynx
<input type="checkbox"/>	<input type="checkbox"/>	T3	Tumor measures more than 4 cm in greatest dimension or with fixation of hemilarynx
<input type="checkbox"/>	<input type="checkbox"/>	T4a	Tumor invades thyroid/cricoid cartilage, hyoid bone, thyroid gland, esophagus or central compartment soft tissue <sup>(2)</sup>
<input type="checkbox"/>	<input type="checkbox"/>	T4b	Tumor invades prevertebral fascia, encases carotid artery, or involves mediastinal structures

### Regional Lymph Nodes (N)

<i>Nasopharynx</i>			
<input type="checkbox"/>	<input type="checkbox"/>	NX	Regional lymph nodes cannot be assessed
<input type="checkbox"/>	<input type="checkbox"/>	N0	No regional lymph node metastasis
<input type="checkbox"/>	<input type="checkbox"/>	N1	Unilateral metastasis in lymph node(s), 6 cm or less in greatest dimension, above the supraclavicular fossa <sup>(3)</sup>
<input type="checkbox"/>	<input type="checkbox"/>	N2	Bilateral metastasis in lymph node(s), 6 cm or less in greatest dimension, above the supraclavicular fossa <sup>(3)</sup>
<input type="checkbox"/>	<input type="checkbox"/>	N3	Metastasis in a lymph node(s) >6cm and/or to supraclavicular fossa
<input type="checkbox"/>	<input type="checkbox"/>	N3a	Greater than 6 cm in dimension
<input type="checkbox"/>	<input type="checkbox"/>	N3b	Extension to the supraclavicular fossa <sup>(3)</sup>
<i>Oropharynx and Hypopharynx</i>			
<input type="checkbox"/>	<input type="checkbox"/>	NX	Regional lymph nodes cannot be assessed
<input type="checkbox"/>	<input type="checkbox"/>	N0	No regional lymph node metastasis
<input type="checkbox"/>	<input type="checkbox"/>	N1	Metastasis in a single ipsilateral lymph node, 3 cm or less in greatest dimension
<input type="checkbox"/>	<input type="checkbox"/>	N2	Metastasis in a single ipsilateral lymph node, more than 3 cm but not more than 6 cm in greatest dimension, or in multiple ipsilateral lymph nodes, none more than 6 cm in greatest dimension, or in bilateral or contralateral lymph nodes, none more than 6 cm in greatest dimension
<input type="checkbox"/>	<input type="checkbox"/>	N2a	Metastasis in a single ipsilateral lymph node more than 3 cm but not more than 6 cm in greatest dimension
<input type="checkbox"/>	<input type="checkbox"/>	N2b	Metastasis in multiple ipsilateral lymph nodes, none more than 6 cm in greatest dimension
<input type="checkbox"/>	<input type="checkbox"/>	N2c	Metastasis in bilateral or contralateral lymph nodes, none more than 6 cm in greatest dimension
<input type="checkbox"/>	<input type="checkbox"/>	N3	Metastasis in a lymph node more than 6 cm in greatest dimension

### Notes

1. Parapharyngeal extension denotes posterolateral infiltration of tumor beyond the pharyngobasilar fascia.
2. Central compartment soft tissue includes prelaryngeal strap muscles and subcutaneous fat.
3. Midline nodes are considered ipsilateral nodes.

(continued on reverse side)

Clinical	Pathologic	Distant Metastasis (M)	
<input type="checkbox"/>	<input type="checkbox"/>	MX	Distant metastasis cannot be assessed
<input type="checkbox"/>	<input type="checkbox"/>	M0	No distant metastasis
<input type="checkbox"/>	<input type="checkbox"/>	M1	Distant metastasis

Biopsy of metastatic site performed ..... Y ..... N  
 Source of pathologic metastatic specimen \_\_\_\_\_

Clinical	Pathologic	Stage Grouping: Nasopharynx			
<input type="checkbox"/>	<input type="checkbox"/>	0	Tis	N0	M0
<input type="checkbox"/>	<input type="checkbox"/>	1	T1	N0	M0
<input type="checkbox"/>	<input type="checkbox"/>	IIA	T2a	N0	M0
<input type="checkbox"/>	<input type="checkbox"/>		T1	N1	M0
<input type="checkbox"/>	<input type="checkbox"/>		T2	N1	M0
<input type="checkbox"/>	<input type="checkbox"/>		T2a	N1	M0
<input type="checkbox"/>	<input type="checkbox"/>	IIB	T2b	N0	M0
<input type="checkbox"/>	<input type="checkbox"/>		T2b	N1	M0
<input type="checkbox"/>	<input type="checkbox"/>		T1	N2	M0
<input type="checkbox"/>	<input type="checkbox"/>		T2a	N2	M0
<input type="checkbox"/>	<input type="checkbox"/>	III	T2b	N2	M0
<input type="checkbox"/>	<input type="checkbox"/>		T3	N0	M0
<input type="checkbox"/>	<input type="checkbox"/>		T3	N1	M0
<input type="checkbox"/>	<input type="checkbox"/>		T3	N2	M0
<input type="checkbox"/>	<input type="checkbox"/>	IVA	T4	N0	M0
<input type="checkbox"/>	<input type="checkbox"/>		T4	N1	M0
<input type="checkbox"/>	<input type="checkbox"/>		T4	N2	M0
<input type="checkbox"/>	<input type="checkbox"/>	IVB	Any T	N3	M0
<input type="checkbox"/>	<input type="checkbox"/>	IVC	Any T	Any N	M1

Clinical	Pathologic	Stage Grouping: Oropharynx and Hypopharynx			
<input type="checkbox"/>	<input type="checkbox"/>	0	Tis	N0	M0
<input type="checkbox"/>	<input type="checkbox"/>	I	T1	N0	M0
<input type="checkbox"/>	<input type="checkbox"/>	II	T2	N0	M0
<input type="checkbox"/>	<input type="checkbox"/>		T3	N0	M0
<input type="checkbox"/>	<input type="checkbox"/>		T1	N1	M0
<input type="checkbox"/>	<input type="checkbox"/>		T2	N1	M0
<input type="checkbox"/>	<input type="checkbox"/>	III	T3	N1	M0
<input type="checkbox"/>	<input type="checkbox"/>		T2	N2	M0
<input type="checkbox"/>	<input type="checkbox"/>		T1	N2	M0
<input type="checkbox"/>	<input type="checkbox"/>		T2	N2	M0
<input type="checkbox"/>	<input type="checkbox"/>	IVA	T3	N2	M0
<input type="checkbox"/>	<input type="checkbox"/>		T4a	N0	M0
<input type="checkbox"/>	<input type="checkbox"/>		T4a	N1	M0
<input type="checkbox"/>	<input type="checkbox"/>		T1	N2	M0
<input type="checkbox"/>	<input type="checkbox"/>	IVB	T2	N2	M0
<input type="checkbox"/>	<input type="checkbox"/>		T3	N2	M0
<input type="checkbox"/>	<input type="checkbox"/>		T4a	N2	M0
<input type="checkbox"/>	<input type="checkbox"/>		T4b	Any N	M0
<input type="checkbox"/>	<input type="checkbox"/>	IVC	Any T	N3	M0
<input type="checkbox"/>	<input type="checkbox"/>		Any T	Any N	M1

**Histologic Grade (G)** (Oropharynx, Hypopharynx)

- GX Grade cannot be assessed
- G1 Well differentiated
- G2 Moderately differentiated
- G3 Poorly differentiated

**Residual Tumor (R)**

- RX Presence of residual tumor cannot be assessed
- R0 No residual tumor
- R1 Microscopic residual tumor
- R2 Macroscopic residual tumor

**Additional Descriptors**

For identification of special cases of TNM or pTNM classifications, the “m” suffix and “y,” “r,” and “a” prefixes are used. Although they do not affect the stage grouping, they indicate cases needing separate analysis.

- m suffix** indicates the presence of multiple primary tumors in a single site and is recorded in parentheses: pT(m)NM.
- y prefix** indicates those cases in which classification is performed during or following initial multimodality therapy. The cTNM or pTNM category is identified by a “y” prefix. The ycTNM or ypTNM categorizes the extent of tumor actually present at the time of that examination. The “y” categorization is not an estimate of tumor prior to multimodality therapy.
- r prefix** indicates a recurrent tumor when staged after a disease-free interval, and is identified by the “r” prefix: rTNM.
- a prefix** designates the stage determined at autopsy: aTNM.

**Prognostic Indicators (If applicable)**

**Notes**

**Additional Descriptors**

**Lymphatic Vessel Invasion (L)**

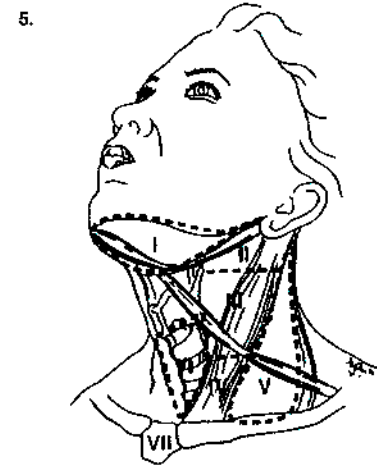
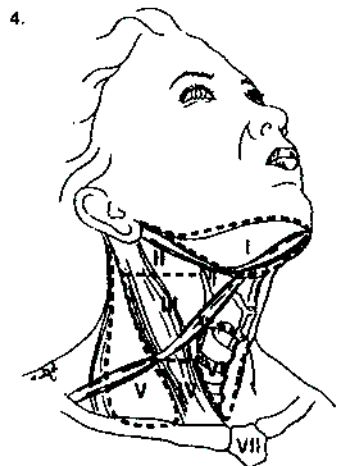
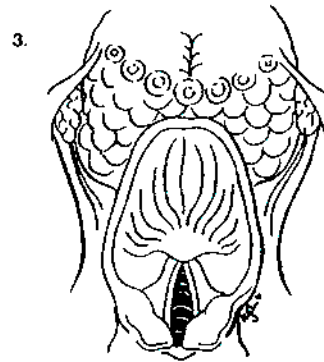
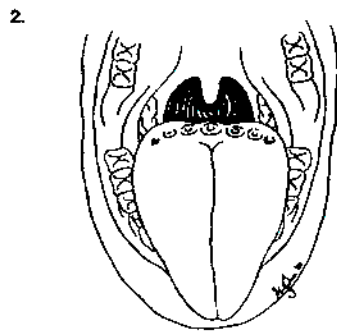
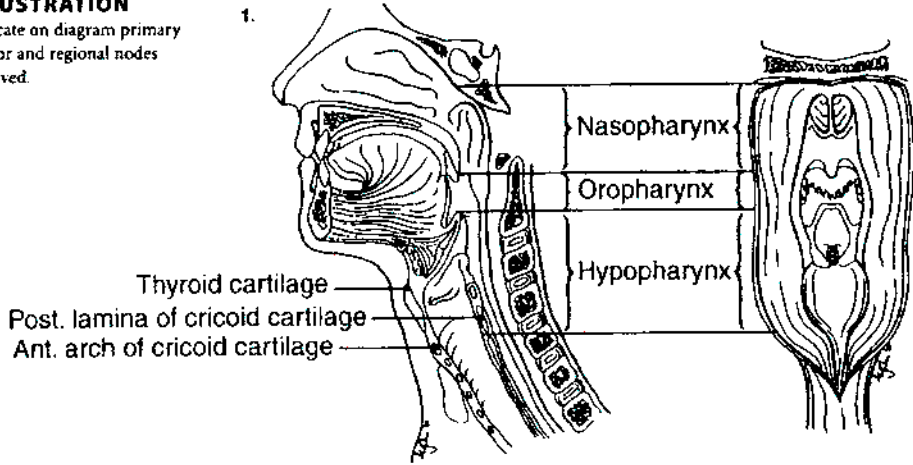
- LX Lymphatic vessel invasion cannot be assessed
- L0 No lymphatic vessel invasion
- L1 Lymphatic vessel invasion

**Venous Invasion (V)**

- VX Venous invasion cannot be assessed
- V0 No venous invasion
- V1 Microscopic venous invasion
- V2 Macroscopic venous invasion

**ILLUSTRATION**

Indicate on diagram primary tumor and regional nodes involved.



Physician's Signature \_\_\_\_\_

Date \_\_\_\_\_

## Larynx

(*Nonepithelial tumors such as those of lymphoid tissue, soft tissue, bone, and cartilage are not included.*)

C10.1 Anterior (lingual) surface of epiglottis	C32.1 Supraglottis (laryngeal surface)	C32.8 Overlapping lesion of larynx
C32.0 Glottis	C32.2 Subglottis	C32.9 Larynx, NOS
	C32.3 Laryngeal cartilage	

### SUMMARY OF CHANGES

- T4 lesions have been divided into T4a (resectable) and T4b (unresectable), leading to the division of Stage IV into Stage IVA, Stage IVB, and Stage IVC.

### ANATOMY

**Primary Site.** The following anatomic definition of the larynx allows classification of carcinomas arising in the encompassed mucous membranes but excludes cancers arising on the lateral or posterior pharyngeal wall, pyriform fossa, postcricoid area, or base of tongue.

The anterior limit of the larynx is composed of the anterior or lingual surface of the suprahyoid epiglottis, the thyrohyoid membrane, the anterior commissure, and the anterior wall of the subglottic region, which is composed of the thyroid cartilage, the cricothyroid membrane, and the anterior arch of the cricoid cartilage.

The posterior and lateral limits include the laryngeal aspect of the aryepiglottic folds, the arytenoid region, the interarytenoid space, and the posterior surface of the subglottic space, represented by the mucous membrane covering the surface of the cricoid cartilage.

The superolateral limits are composed of the tip and the lateral borders of the epiglottis. The inferior limits are made up of the plane passing through the inferior edge of the cricoid cartilage.

For purposes of this clinical stage classification, the larynx is divided into three regions: supraglottis, glottis, and subglottis. The supraglottis is composed of the epiglottis (both its lingual and laryngeal aspects), aryepiglottic folds (laryngeal aspect), arytenoids, and ventricular bands (false cords). The epiglottis is divided for staging purposes into suprahyoid and infrahyoid portions by a plane at the level of the hyoid bone. The inferior boundary of the supraglottis is a horizontal plane passing through the lateral margin of the ventricle at its junction with the superior surface of the vocal cord.

The glottis is composed of the superior and inferior surfaces of the true vocal cords, including the anterior and posterior commissures. It occupies a horizontal plane 1 cm in thickness, extending inferiorly from the lateral margin of the ventricle. The subglottis is the region extending from the lower boundary of the glottis to the lower margin of the cricoid cartilage.

The division of the larynx is summarized as follows:

Site	Subsite
Supraglottis	Suprahyoid epiglottis Infrahyoid epiglottis Aryepiglottic folds (laryngeal aspect) Arytenoids Ventricular bands (false cords)
Glottis	True vocal cords, including anterior and posterior commissures
Subglottis	Subglottis

**Regional Lymph Nodes.** The incidence and distribution of cervical nodal metastases from cancer of the larynx vary with the site of origin and the T classification of the primary tumor. The true vocal cords are nearly devoid of lymphatics, and tumors of that site alone rarely spread to regional nodes. By contrast, the supraglottis has a rich and bilaterally interconnected lymphatic network, and primary supraglottic cancers are commonly accompanied by regional lymph node spread. Glottic tumors may spread directly to adjacent soft tissues and prelaryngeal, pretracheal, paralaryngeal, and paratracheal nodes, as well as to upper, mid-, and lower jugular nodes. Supraglottic tumors commonly spread to upper and midjugular nodes, considerably less



commonly to submental or submandibular nodes, and occasionally to retropharyngeal nodes. The rare subglottic primary tumors spread first to adjacent soft tissues and pre-laryngeal, pretracheal, paralaryngeal, and paratracheal nodes, then to mid- and lower jugular nodes. Contralateral lymphatic spread is common.

In clinical evaluation, the physical size of the nodal mass should be measured. Most masses over 3 cm in diameter are not single nodes but, rather, are confluent nodes or tumor in soft tissues of the neck. There are three categories of clinically positive nodes: N1, N2, and N3. Midline nodes are considered ipsilateral nodes. In addition to the components to describe the N category, regional lymph nodes should also be described according to the level of the neck that is involved. Pathologic examination is necessary for documentation of such disease extent. Imaging studies showing amorphous spiculated margins of involved nodes or involvement of internodal fat resulting in loss of normal oval-to-round nodal shape strongly suggest extracapsular (extranodal) tumor spread. No imaging study (as yet) can identify microscopic foci in regional nodes or distinguish between small reactive nodes and small malignant nodes without central radiographic inhomogeneity.

**Metastatic Sites.** Distant spread is common only for patients who have bulky regional lymphadenopathy. When distant metastases occur, spread to the lungs is most common; skeletal or hepatic metastases occur less often. Mediastinal lymph node metastases are considered distant metastases.

## RULES FOR CLASSIFICATION

**Clinical Staging.** The assessment of the larynx is accomplished primarily by inspection, using indirect mirror and direct endoscopic examination with a fiberoptic nasolaryngoscope. The tumor must be confirmed histologically, and any other data obtained by biopsies may be included. Cross-sectional imaging in laryngeal carcinoma is recommended when the primary tumor extent is in question on the basis of clinical examination. Radiologic nodal staging should be done simultaneously to supplement clinical examination.

Complete endoscopy under general anesthesia is usually performed after completion of other diagnostic studies to accurately assess, document, and biopsy the tumor.

**Pathologic Staging.** Pathologic staging requires the use of all information obtained in clinical staging and in histologic study of the surgically resected specimen. The surgeon's evaluation of gross unresected residual tumor must also be included. Specimens that are resected after radiation or chemotherapy need to be identified and considered in context. The pathologic description of any lymphadenectomy specimen should describe the size, number, and position of the involved node(s) and the presence or absence of extracapsular extension.

## DEFINITION OF TNM

### Primary Tumor (T)

- TX Primary tumor cannot be assessed
- T0 No evidence of primary tumor
- Tis Carcinoma *in situ*

### Supraglottis

- T1 Tumor limited to one subsite of supraglottis with normal vocal cord mobility
- T2 Tumor invades mucosa of more than one adjacent subsite of supraglottis or glottis or region outside the supraglottis (e.g., mucosa of base of tongue, vallecula, medial wall of pyriform sinus) without fixation of the larynx
- T3 Tumor limited to larynx with vocal cord fixation and/or invades any of the following: postcricoid area, pre-epiglottic tissues, paraglottic space, and/or minor thyroid cartilage erosion (e.g., inner cortex)
- T4a Tumor invades through the thyroid cartilage and/or invades tissues beyond the larynx (e.g., trachea, soft tissues of neck including deep extrinsic muscle of the tongue, strap muscles, thyroid, or esophagus)
- T4b Tumor invades prevertebral space, encases carotid artery, or invades mediastinal structures

### Glottis

- T1 Tumor limited to the vocal cord(s) (may involve anterior or posterior commissure) with normal mobility
- T1a Tumor limited to one vocal cord
- T1b Tumor involves both vocal cords
- T2 Tumor extends to supraglottis and/or subglottis, and/or with impaired vocal cord mobility
- T3 Tumor limited to the larynx with vocal cord fixation and/or invades paraglottic space, and/or minor thyroid cartilage erosion (e.g., inner cortex)
- T4a Tumor invades through the thyroid cartilage and/or invades tissues beyond the larynx (e.g., trachea, soft tissues of neck including deep extrinsic muscle of the tongue, strap muscles, thyroid, or esophagus)
- T4b Tumor invades prevertebral space, encases carotid artery, or invades mediastinal structures

### Subglottis

- T1 Tumor limited to the subglottis
- T2 Tumor extends to vocal cord(s) with normal or impaired mobility
- T3 Tumor limited to larynx with vocal cord fixation
- T4a Tumor invades cricoid or thyroid cartilage and/or invades tissues beyond the larynx (e.g., trachea, soft tissues of neck including deep extrinsic muscles of the tongue, strap muscles, thyroid, or esophagus)
- T4b Tumor invades prevertebral space, encases carotid artery, or invades mediastinal structures

**Regional Lymph Nodes (N)**

- NX Regional lymph nodes cannot be assessed
- N0 No regional lymph node metastasis
- N1 Metastasis in a single ipsilateral lymph node, 3 cm or less in greatest dimension
- N2 Metastasis in a single ipsilateral lymph node, more than 3 cm but not more than 6 cm in greatest dimension, or in multiple ipsilateral lymph nodes, none more than 6 cm in greatest dimension, or in bilateral or contralateral lymph nodes, none more than 6 cm in greatest dimension
- N2a Metastasis in a single ipsilateral lymph node, more than 3 cm but not more than 6 cm in greatest dimension
- N2b Metastasis in multiple ipsilateral lymph nodes, none more than 6 cm in greatest dimension
- N2c Metastasis in bilateral or contralateral lymph nodes, none more than 6 cm in greatest dimension
- N3 Metastasis in a lymph node, more than 6 cm in greatest dimension

**Distant Metastasis (M)**

- MX Distant metastasis cannot be assessed
- M0 No distant metastasis
- M1 Distant metastasis

<b>STAGE GROUPING</b>			
Stage 0	Tis	N0	M0
Stage I	T1	N0	M0
Stage II	T2	N0	M0
Stage III	T3	N0	M0
	T1	N1	M0
	T2	N1	M0
	T3	N1	M0
Stage IVA	T4a	N0	M0
	T4a	N1	M0
	T1	N2	M0
	T2	N2	M0
	T3	N2	M0
Stage IVB	T4a	N2	M0
	T4b	Any N	M0
	Any T	N3	M0
Stage IVC	Any T	Any N	M1

a descriptive as well as numerical form (i.e., well differentiated, moderately differentiated, and poorly differentiated), depending on the degree of closeness to or deviation from squamous epithelium in mucosal sites. Also recommended where feasible is a quantitative evaluation of depth of invasion of the primary tumor and the presence or absence of vascular invasion and perineural invasion. Although the grade of tumor does not enter into the staging of the tumor, it should be recorded. The pathologic description of any lymphadenectomy specimen should describe the size, number, and position of the involved node(s) and the presence or absence of extracapsular extension.

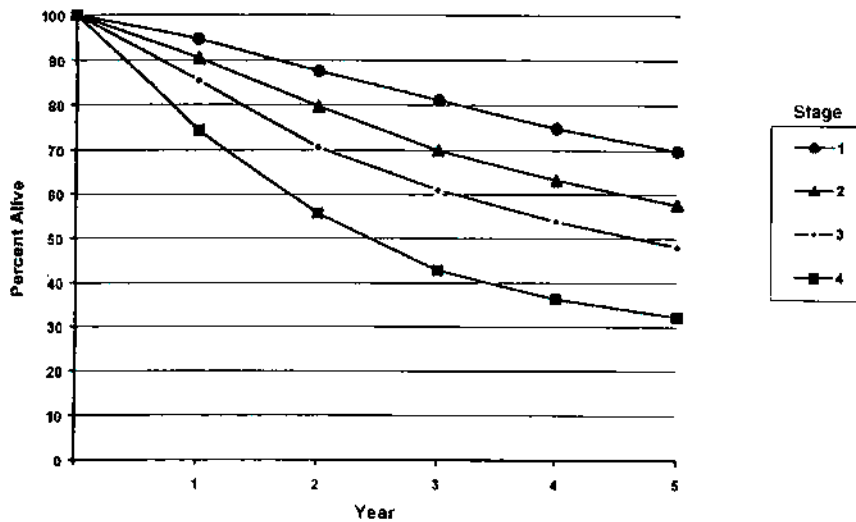
**HISTOLOGIC GRADE (G)**

- GX Grade cannot be assessed
- G1 Well differentiated
- G2 Moderately differentiated
- G3 Poorly differentiated

Figures 5.1A, 5.1B, 5.2A, 5.2B, 5.3A, 5.3B, 5.4A, and 5.4B show observed and relative survival rates for patients with squamous cell carcinoma of the larynx (5.1A,B), squamous cell carcinoma of the supraglottis (5.2A,B), squamous cell carcinoma of the glottis (5.3A,B), and squamous cell carcinoma of the subglottis (5.4A,B) for the year 1985–1991, classified by the AJCC staging classification.

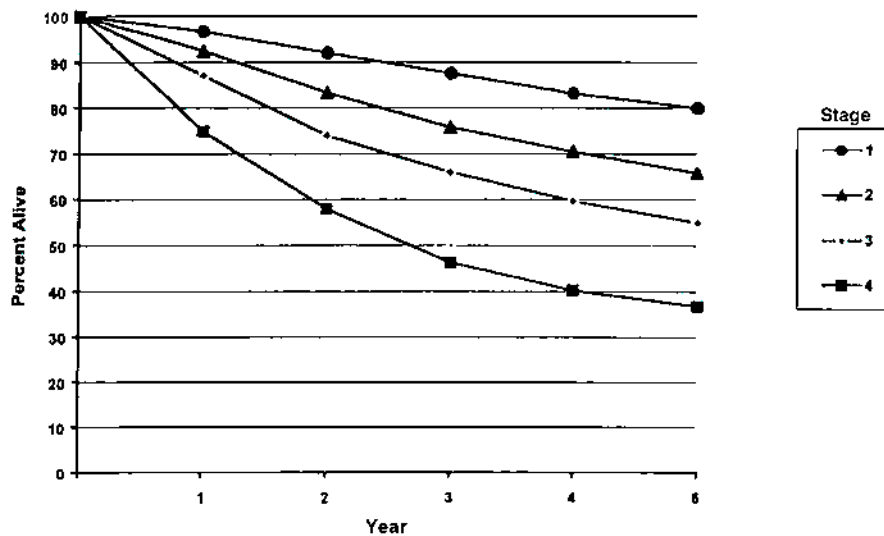
**HISTOPATHOLOGIC TYPE**

The predominant cancer is squamous cell carcinoma. The staging guidelines are applicable to all forms of carcinoma. Nonepithelial tumors such as those of lymphoid tissue, soft tissue, bone, and cartilage (i.e., lymphoma, melanoma, and sarcoma) are not included. Histologic confirmation of diagnosis is required. Histopathologic grading of squamous carcinoma is recommended. The grade is subjective and uses



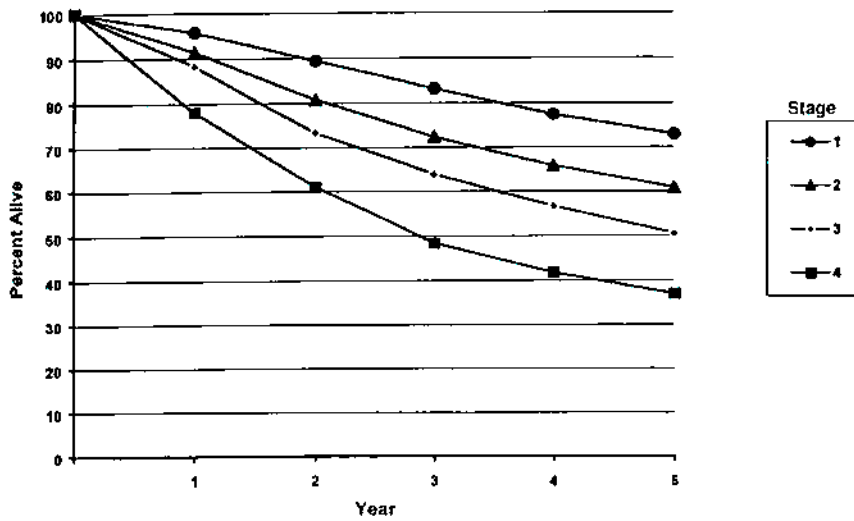
OBSERVED SURVIVAL BY STAGE	1	2	3	4	5	95% CIs*	CASES
1	94.6	87.5	81.0	74.8	69.8	68.6 - 71.1	5750
2	90.4	79.6	69.9	63.2	57.5	55.5 - 59.9	2763
3	85.4	70.6	61.0	53.8	48.1	46.1 - 50.1	2661
4	74.4	55.6	42.8	36.3	32.2	30.4 - 33.9	3064

**FIG. 5.1A.** Five-year, observed survival by "combined" AJCC stage for squamous cell carcinoma of the larynx, 1985-1991. (\*95% confidence intervals correspond to year-5 survival rates.)



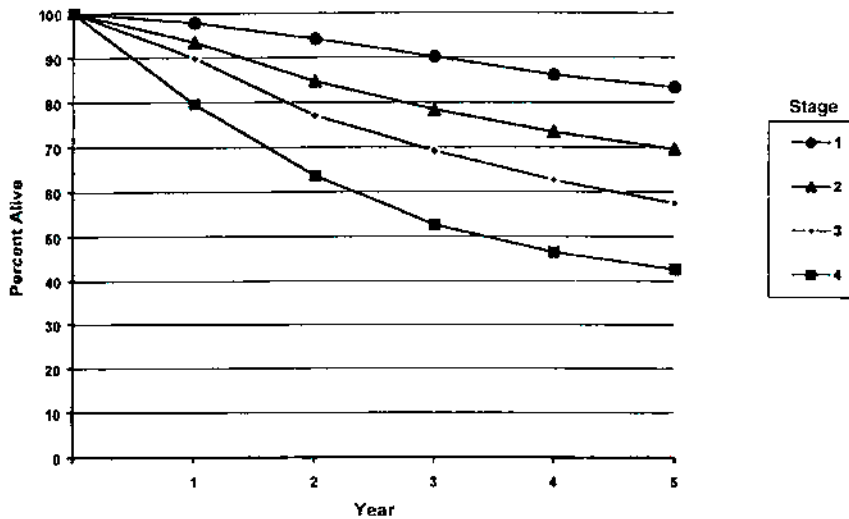
RELATIVE SURVIVAL BY STAGE	1	2	3	4	5	95% CIs*	CASES
1	96.7	92.0	87.6	83.2	79.9	78.4 - 81.3	5775
2	92.5	83.3	75.7	70.4	65.7	63.5 - 68.0	2779
3	87.1	73.9	65.9	59.6	55.0	52.6 - 57.3	2675
4	74.9	57.9	46.3	40.2	36.7	34.7 - 38.7	3095

**FIG. 5.1B.** Five-year, relative survival by "combined" AJCC stage for squamous cell carcinoma of the larynx, 1985-1991. (\*95% confidence intervals correspond to year-5 survival rates.)



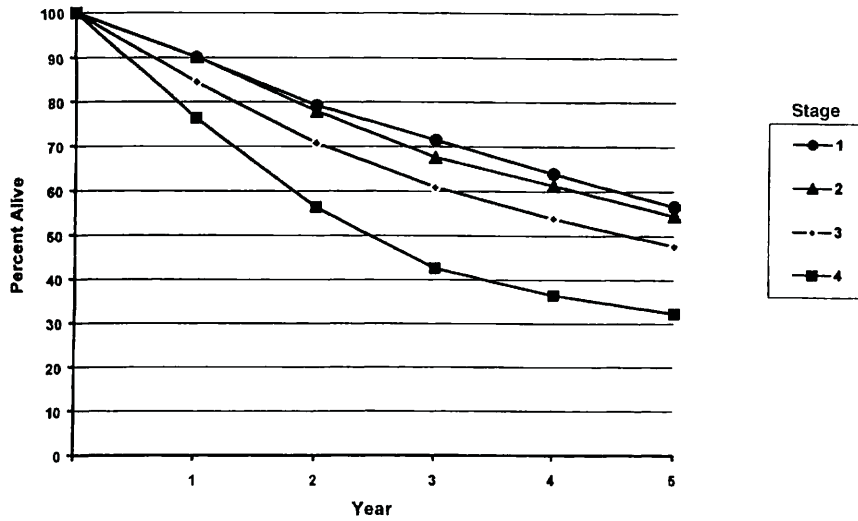
OBSERVED SURVIVAL BY STAGE	1	2	3	4	5	95% CIs*	CASES
1	95.7	89.4	83.3	77.4	72.9	71.5 – 74.3	4508
2	91.4	80.8	72.3	65.7	60.8	57.9 – 63.6	1333
3	88.3	73.3	63.8	56.6	50.5	46.9 – 54.0	868
4	78.0	61.0	48.4	41.7	36.9	32.6 – 41.1	581

**FIG. 5.2A.** Five-year, observed survival by “combined” AJCC stage for squamous cell carcinoma of the supraglottis, 1985–1991. (\*95% confidence intervals correspond to year-5 survival rates.)



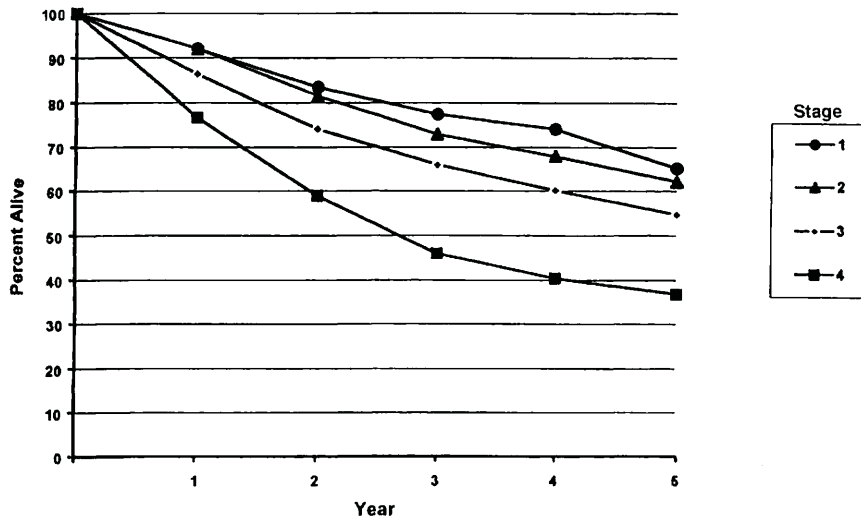
RELATIVE SURVIVAL BY STAGE	1	2	3	4	5	95% CIs*	CASES
1	97.8	94.1	90.1	86.1	83.4	81.8 – 85.0	4528
2	93.4	84.7	78.3	73.3	69.5	66.3 – 72.7	1340
3	89.9	77.0	69.1	62.6	57.4	53.3 – 61.5	872
4	79.6	63.6	52.5	46.4	42.6	37.7 – 47.4	587

**FIG. 5.2B.** Five-year, relative survival by “combined” AJCC stage for squamous cell carcinoma of the supraglottis, 1985–1991. (\*95% confidence intervals correspond to year-5 survival rates.)



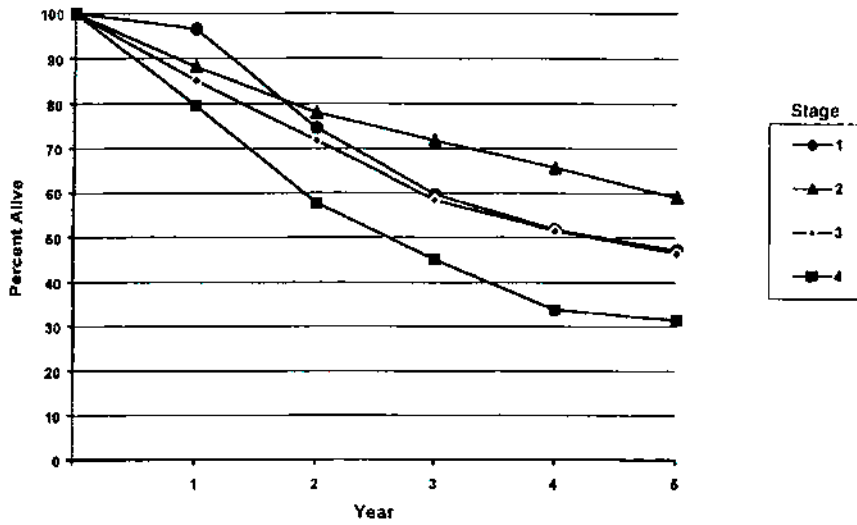
OBSERVED SURVIVAL BY STAGE	1	2	3	4	5	95% CIs*	CASES
1	90.1	79.2	71.5	63.9	56.6	53.0 – 60.2	823
2	90.2	77.9	67.5	61.3	54.5	51.3 – 57.7	1044
3	84.5	70.8	60.9	53.9	47.7	44.7 – 50.7	1203
4	76.4	56.4	42.6	36.4	32.3	29.9 – 34.7	1657

**FIG. 5.3A.** Five-year, observed survival by “combined” AJCC stage for squamous cell carcinoma of the glottis, 1985–1991. (\*95% confidence intervals correspond to year-5 survival rates.)



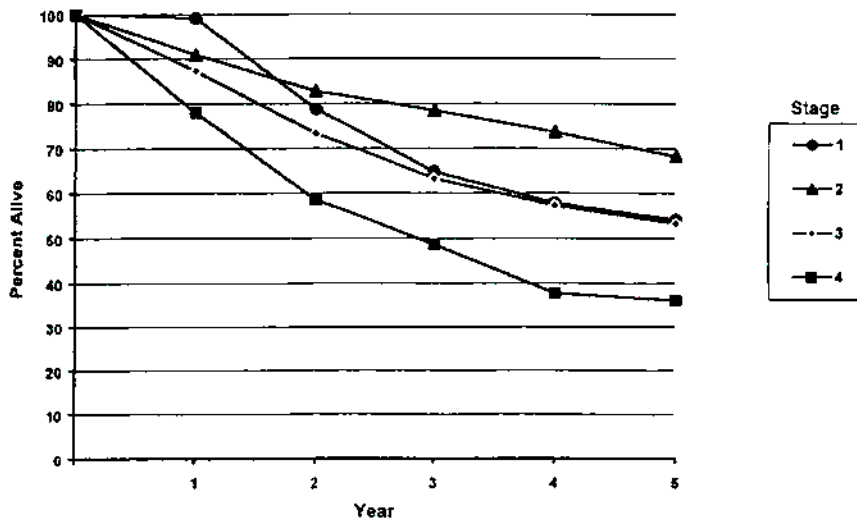
RELATIVE SURVIVAL BY STAGE	1	2	3	4	5	95% CIs*	CASES
1	92.0	83.5	77.4	71.0	65.1	61.0 – 69.3	826
2	92.0	81.5	72.9	67.9	62.1	58.5 – 65.8	1049
3	86.4	74.1	65.9	60.1	54.7	51.3 – 58.2	1208
4	76.7	58.9	45.9	40.4	36.8	34.1 – 39.6	1672

**FIG. 5.3B.** Five-year, relative survival by “combined” AJCC stage for squamous cell carcinoma of the glottis, 1985–1991. (\*95% confidence intervals correspond to year-5 survival rates.)



OBSERVED SURVIVAL BY STAGE	1	2	3	4	5	95% CIs*	CASES
1	96.5	74.6	59.7	51.8	47.3	28.0 – 66.5	29
2	88.1	78.0	71.8	65.6	59.0	45.1 – 72.9	51
3	85.1	71.8	58.4	51.5	46.5	31.7 – 61.2	48
4	79.6	57.7	45.1	33.8	31.4	18.1 – 44.7	56

FIG. 5.4A. Five-year, observed survival by “combined” AJCC stage for squamous cell carcinoma of the subglottis, 1985–1991. (\*95% confidence intervals correspond to year-5 survival rates.)



RELATIVE SURVIVAL BY STAGE	1	2	3	4	5	95% CIs*	CASES
1	99.1	79.7	64.7	57.8	54.1	31.9 – 76.4	29
2	90.9	82.8	78.4	73.6	68.2	52.3 – 84.1	53
3	87.3	73.3	63.2	57.2	53.2	36.2 – 70.2	48
4	78.0	58.5	48.6	37.6	36.0	20.7 – 51.2	56

FIG. 5.4B. Five-year, relative survival by “combined” AJCC stage for squamous cell carcinoma of the subglottis, 1985–1991. (\*95% confidence intervals correspond to year-5 survival rates.)

## BIBLIOGRAPHY

- Archer CR, Yeager VL, Herbold DR: CT versus histology of laryngeal cancer: the value in predicting laryngeal cartilage invasion. *Laryngoscope* 93:140-147, 1983
- Cooper JS, Farnan NC, Asbell SO, et al: Recursive partitioning analysis of 2,105 patients treated in Radiation Therapy Oncology Group studies of head and neck cancer. *Cancer* 77:1905-1911, 1996
- Deleyiannis FW, Thomas DB, Vaughan TL, et al: Alcoholism: independent predictor of survival in patients with head and neck cancer. *J Natl Cancer Inst* 88:542-549, 1996
- Eibaud JD, Elias EG, Suter CM, et al: Prognostic factors in squamous cell carcinoma of the larynx. *Am J Surg* 58:314-317, 1989
- Faye-Lund H, Abdelnoor M: Prognostic factors of survival in a cohort of head and neck cancer patients in Oslo. *Eur J Cancer B Oral Oncol* 2:83-90, 1996
- Isaacs JJ, Mancuso AA, Mendenhall WM, et al: Deep spread patterns in CT staging of T2-4 squamous cell laryngeal carcinoma. *Otolaryngol Head Neck Surg* 99:455-464, 1988
- Kaplan MH, Feinstein AR: The importance of classifying initial co-morbidity in evaluating the outcome of diabetes mellitus. *J Chron Dis* 37:387-404, 1974
- Karnofsky DA, Abelman WH, Craver LF, Burchenal JH: The use of nitrogen mustards in the palliative treatment of carcinoma. *Cancer* 1:634-656, 1948
- Mafee MF, Schield JA, Valvassori GE, et al: CT of the larynx: correlation with anatomic and pathologic studies in cases of laryngeal carcinoma. *Radiology* 147:123-128, 1983
- Mendenhall WM, Parsons JT, Stringer SP, et al: Carcinoma of the supraglottic larynx: a basis for comparing the results of radiotherapy and surgery. *Head Neck* 12:204-209, 1990
- Piccirillo JF: Inclusion of comorbidity in a staging system for head and neck cancer. *Oncology* 9:831-836, 1995
- Rozack MS, Maipang T, Sabo K, et al: Management of advanced glottic carcinomas. *Am J Surg* 158:318-320, 1989
- Singh B, Alfonso A, Sabin S, et al: Outcome differences in younger and older patients with laryngeal cancer: a retrospective case-control study. *Am J Otolaryngol* 21:92-97, 2000
- Singh B, Bhaya M, Zimble M, et al: Impact of comorbidity on outcome of young patients with head and neck squamous cell carcinoma. *Head Neck* 20:1-7, 1998
- Strong EW: Cancer of the larynx and hypopharynx. *Prob Gen Surg* 5:166-189, 1988
- Van Nostrand AWP, Brodarec I: Laryngeal carcinoma: modification of surgical techniques based upon an understanding of tumor growth characteristics. *J Otolaryngol* 11:186-192, 1982
- Veterans Administration Laryngeal Study Group: Induction chemotherapy plus radiation compared to surgery plus radiation in patients with advanced laryngeal cancer. *N Engl J Med* 324:1685-1690, 1991

## HISTOLOGIES—LARYNX

- 8010/2 Carcinoma *in situ*, NOS  
8010/3 Carcinoma, NOS

- 8012/3 Large cell carcinoma, NOS  
8013/3 Large cell neuroendocrine carcinoma  
8020/3 Carcinoma, undifferentiated, NOS  
8021/3 Carcinoma, anaplastic, NOS  
8030/3 Giant cell and spindle cell carcinoma  
8031/3 Giant cell carcinoma  
8032/3 Spindle cell carcinoma, NOS  
8033/3 Pseudosarcomatous carcinoma  
8041/3 Small cell carcinoma, NOS  
8042/3 Oat cell carcinoma  
8043/3 Small cell carcinoma, fusiform cell  
8044/3 Small cell carcinoma, intermediate cell  
8045/3 Combined small cell carcinoma  
8051/3 Verrucous carcinoma, NOS  
8052/2 Papillary squamous cell carcinoma, non-invasive  
8052/3 Papillary squamous cell carcinoma  
8070/2 Squamous cell carcinoma *in situ*, NOS  
8070/3 Squamous cell carcinoma, NOS  
8071/3 Squamous cell carcinoma, keratinizing, NOS  
8072/3 Squamous cell carcinoma, large cell  
8073/3 Squamous cell carcinoma, small cell, non-keratinizing  
8074/3 Squamous cell carcinoma, spindle cell  
8075/3 Squamous cell carcinoma, adenoid  
8076/2 Squamous cell carcinoma *in situ* with questionable stromal invasion  
8076/3 Squamous cell carcinoma, microinvasive  
8082/3 Lymphoepithelial carcinoma  
8083/3 Basaloid squamous cell carcinoma  
8084/3 Squamous cell carcinoma, clear cell type  
8090/3 Basal cell carcinoma, NOS  
8091/3 Multifocal superficial basal cell carcinoma  
8092/3 Infiltrating basal cell carcinoma, NOS  
8093/3 Basal cell carcinoma, fibroepithelial  
8094/3 Basosquamous carcinoma  
8097/3 Basal cell carcinoma, nodular  
8098/3 Adenoid basal carcinoma  
8123/3 Basaloid carcinoma  
8140/2 Adenocarcinoma *in situ*, NOS  
8140/3 Adenocarcinoma, NOS  
8144/3 Adenocarcinoma, intestinal type  
8145/3 Carcinoma, diffuse type  
8147/3 Basal cell adenocarcinoma  
8200/3 Adenoid cystic carcinoma  
8246/3 Neuroendocrine carcinoma, NOS  
8310/3 Clear cell adenocarcinoma, NOS  
8430/3 Mucoepidermoid carcinoma  
8440/3 Cystadenocarcinoma, NOS  
8480/3 Mucinous adenocarcinoma  
8481/3 Mucin-producing adenocarcinoma  
8510/3 Medullary carcinoma, NOS  
8525/3 Polymorphous low-grade adenocarcinoma  
8550/3 Acinar cell carcinoma  
8560/3 Adenosquamous carcinoma  
8562/3 Epithelial-myoepithelial carcinoma  
8574/3 Adenocarcinoma with neuroendocrine differentiation  
8940/3 Mixed tumor, malignant, NOS  
8941/3 Carcinoma in pleomorphic adenoma

# LARYNX

**Hospital Name/Address**

**Patient Name/Information**

2

Type of Specimen \_\_\_\_\_  
Tumor Size \_\_\_\_\_

Histopathologic Type \_\_\_\_\_  
Laterality:     Bilateral     Left     Right

**DEFINITIONS**

Clinical	Pathologic	<b>Primary Tumor (T)</b>	
<input type="checkbox"/>	<input type="checkbox"/>	TX	Primary tumor cannot be assessed
<input type="checkbox"/>	<input type="checkbox"/>	T0	No evidence of primary tumor
<input type="checkbox"/>	<input type="checkbox"/>	Tis	Carcinoma <i>in situ</i>
<i>Supraglottis</i>			
<input type="checkbox"/>	<input type="checkbox"/>	T1	Tumor limited to one subsite of supraglottis with normal vocal cord mobility
<input type="checkbox"/>	<input type="checkbox"/>	T2	Tumor invades mucosa of more than one adjacent subsite of supraglottis or glottis or region outside the supraglottis (e.g., mucosa of base of tongue, vallecula, medial wall of pyriform sinus) without fixation of the larynx
<input type="checkbox"/>	<input type="checkbox"/>	T3	Tumor limited to larynx with vocal cord fixation and/or invades any of the following: postcricoid area, pre-epiglottic tissues, paraglottic space, and/or minor thyroid cartilage erosion (e.g., inner cortex)
<input type="checkbox"/>	<input type="checkbox"/>	T4a	Tumor invades through the thyroid cartilage and/or invades tissues beyond the larynx (e.g., trachea, soft tissues of neck including deep extrinsic muscle of the tongue, strap muscles, thyroid, or esophagus)
<input type="checkbox"/>	<input type="checkbox"/>	T4b	Tumor invades prevertebral space, encases carotid artery, or invades mediastinal structures
<i>Glottis</i>			
<input type="checkbox"/>	<input type="checkbox"/>	T1	Tumor limited to the vocal cord(s) (may involve anterior or posterior commissure) with normal mobility
<input type="checkbox"/>	<input type="checkbox"/>	T1a	Tumor limited to one vocal cord
<input type="checkbox"/>	<input type="checkbox"/>	T1b	Tumor involves both vocal cords
<input type="checkbox"/>	<input type="checkbox"/>	T2	Tumor extends to supraglottis and/or subglottis, or with impaired vocal cord mobility
<input type="checkbox"/>	<input type="checkbox"/>	T3	Tumor limited to the larynx with vocal cord fixation, and/or invades paraglottic space, and/or minor thyroid cartilage erosion (e.g., inner cortex).
<input type="checkbox"/>	<input type="checkbox"/>	T4a	Tumor invades through the thyroid cartilage and/or invades tissues beyond the larynx (e.g., trachea, soft tissues of neck including deep extrinsic muscle of the tongue, strap muscles, thyroid, or esophagus)
<input type="checkbox"/>	<input type="checkbox"/>	T4b	Tumor invades prevertebral space, encases carotid artery, or invades mediastinal structures
<i>Subglottis</i>			
<input type="checkbox"/>	<input type="checkbox"/>	T1	Tumor limited to the subglottis
<input type="checkbox"/>	<input type="checkbox"/>	T2	Tumor extends to vocal cord(s) with normal or impaired mobility
<input type="checkbox"/>	<input type="checkbox"/>	T3	Tumor limited to larynx with vocal cord fixation
<input type="checkbox"/>	<input type="checkbox"/>	T4a	Tumor invades cricoid or thyroid cartilage and/or invades tissues beyond the larynx (e.g., trachea, soft tissues of neck including deep extrinsic muscles of the tongue, strap muscles, thyroid, or esophagus)
<input type="checkbox"/>	<input type="checkbox"/>	T4b	Tumor invades prevertebral space, encases carotid artery, or invades mediastinal structures
<b>Regional Lymph Nodes (N)</b>			
<input type="checkbox"/>	<input type="checkbox"/>	NX	Regional lymph nodes cannot be assessed
<input type="checkbox"/>	<input type="checkbox"/>	N0	No regional lymph node metastasis
<input type="checkbox"/>	<input type="checkbox"/>	N1	Metastasis in a single ipsilateral lymph node, 3 cm or less in greatest dimension
<input type="checkbox"/>	<input type="checkbox"/>	N2	Metastasis in a single ipsilateral lymph node, more than 3 cm but not more than 6 cm in greatest dimension, or in multiple ipsilateral lymph nodes, none more than 6 cm in greatest dimension, or in bilateral or contralateral lymph nodes, none more than 6 cm in greatest dimension
<input type="checkbox"/>	<input type="checkbox"/>	N2a	Metastasis in a single ipsilateral lymph node, more than 3 cm but not more than 6 cm in greatest dimension
<input type="checkbox"/>	<input type="checkbox"/>	N2b	Metastasis in multiple ipsilateral lymph nodes, none more than 6 cm in greatest dimension
<input type="checkbox"/>	<input type="checkbox"/>	N2c	Metastasis in bilateral or contralateral lymph nodes, none more than 6 cm in greatest dimension
<input type="checkbox"/>	<input type="checkbox"/>	N3	Metastasis in a lymph node, more than 6 cm in greatest dimension
<b>Distant Metastasis (M)</b>			
<input type="checkbox"/>	<input type="checkbox"/>	MX	Distant metastasis cannot be assessed
<input type="checkbox"/>	<input type="checkbox"/>	M0	No distant metastasis
<input type="checkbox"/>	<input type="checkbox"/>	M1	Distant metastasis
			Biopsy of metastatic site performed ..... <input type="checkbox"/> Y ..... <input type="checkbox"/> N
			Source of pathologic metastatic specimen _____ (continued on reverse side)



Clinical	Pathologic	Stage Grouping				Notes
<input type="checkbox"/>	<input type="checkbox"/>	0	Tis	N0	M0	<b>Additional Descriptors</b> <b>Lymphatic Vessel Invasion (L)</b> LX Lymphatic vessel invasion cannot be assessed L0 No lymphatic vessel invasion L1 Lymphatic vessel invasion <b>Venous Invasion (V)</b> VX Venous invasion cannot be assessed V0 No venous invasion V1 Microscopic venous invasion V2 Macroscopic venous invasion
<input type="checkbox"/>	<input type="checkbox"/>	I	T1	N0	M0	
<input type="checkbox"/>	<input type="checkbox"/>	II	T2	N0	M0	
<input type="checkbox"/>	<input type="checkbox"/>	III	T3	N0	M0	
			T1	N1	M0	
			T2	N1	M0	
			T3	N1	M0	
<input type="checkbox"/>	<input type="checkbox"/>	IVA	T4a	N0	M0	
			T4a	N1	M0	
			T1	N2	M0	
			T2	N2	M0	
			T3	N2	M0	
<input type="checkbox"/>	<input type="checkbox"/>	IVB	T4a	N2	M0	
			T4b	Any N	M0	
<input type="checkbox"/>	<input type="checkbox"/>	IVC	Any T	N3	M0	
			Any T	Any N	M1	

- Histologic Grade (G)**
- GX Grade cannot be assessed
  - G1 Well differentiated
  - G2 Moderately differentiated
  - G3 Poorly differentiated

- Residual Tumor (R)**
- RX Presence of residual tumor cannot be assessed
  - R0 No residual tumor
  - R1 Microscopic residual tumor
  - R2 Macroscopic residual tumor

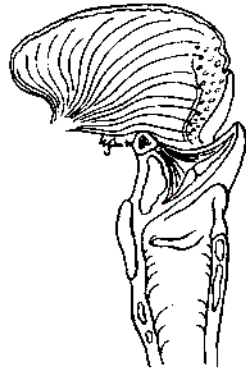
- Additional Descriptors**
- For identification of special cases of TNM or pTNM classifications, the "m" suffix and "y," "r," and "a" prefixes are used. Although they do not affect the stage grouping, they indicate cases needing separate analysis.
- m suffix** indicates the presence of multiple primary tumors in a single site and is recorded in parentheses: pT(m)NM.
  - y prefix** indicates those cases in which classification is performed during or following initial multimodality therapy. The cTNM or pTNM category is identified by a "y" prefix. The ycTNM or ypTNM categorizes the extent of tumor actually present at the time of that examination. The "y" categorization is not an estimate of tumor prior to multimodality therapy.
  - r prefix** indicates a recurrent tumor when staged after a disease-free interval, and is identified by the "r" prefix: rTNM.
  - a prefix** designates the stage determined at autopsy: aTNM.

**Prognostic Indicators (if applicable)**

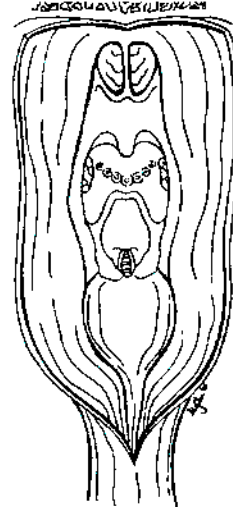
**ILLUSTRATION**

Indicate on diagram primary tumor and regional nodes involved.

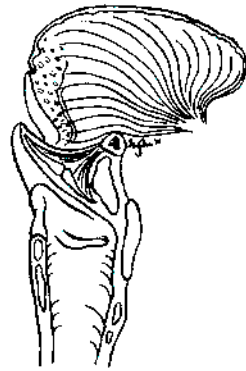1.



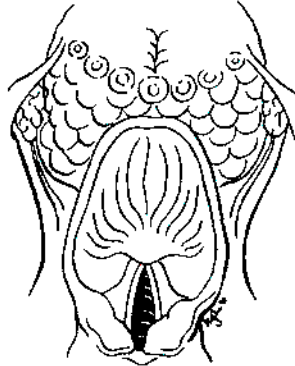
2.



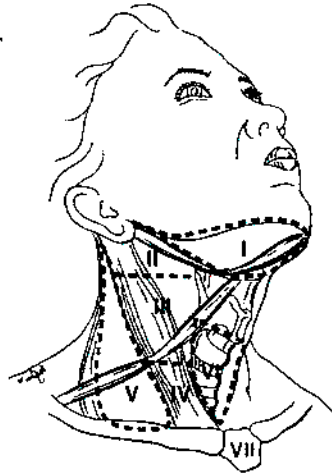
3.



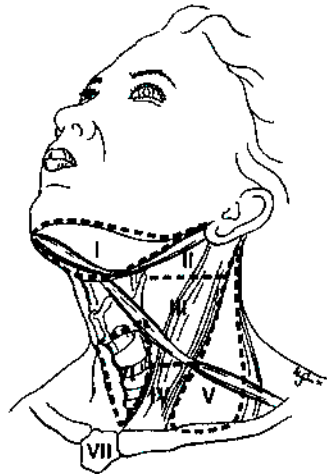
4.



5.



6.



Physician's Signature \_\_\_\_\_ Date \_\_\_\_\_

2

## Nasal Cavity and Paranasal Sinuses

(Nonepithelial tumors such as those of lymphoid tissue, soft tissue, bone, and cartilage are not included)

C30.0 Nasal cavity

C31.0 Maxillary sinus

C31.1 Ethmoid sinus

### SUMMARY OF CHANGES

- A new site has been added for inclusion into the staging system. In addition to maxillary sinus, the nasoethmoid complex is described as a second site with two regions within this site: nasal cavity and ethmoid sinuses.
- The nasal cavity region is further divided into four subsites: septum, floor, lateral wall, and vestibule. The ethmoid sinus region is divided into two subsites: right and left.
- The T staging of ethmoid lesions has been revised to reflect nasoethmoid tumors, and appropriate description for the T staging has been added.
- For maxillary sinus, T4 lesions have been divided into T4a (resectable) and T4b (unresectable), leading to the division of Stage IV into Stage IVA, Stage IVB, and Stage IVC.

### ANATOMY

**Primary Sites.** Cancer of the maxillary sinus is the most common of the sinonasal malignancies. Ethmoid sinus and nasal cavity cancers are equal in frequency but considerably less common than maxillary sinus cancers. Tumors of the sphenoid and frontal sinuses are rare.

The location as well as the extent of the mucosal lesion within the maxillary sinus has prognostic significance. Historically, Ohngren's line, connecting the medial canthus of the eye to the angle of the mandible, is used to divide the maxillary sinus into an anteroinferior portion (infrastructure), which is associated with a good prognosis, and a superoposterior portion (suprastructure), which has a poor prognosis (Fig. 6.1A,B). The poorer outcome associated with superoposterior cancers reflects early access of these tumors to critical structures, including the eye, skull base, pterygoids, and infratemporal fossa.

For the purpose of staging, the nasoethmoidal complex is divided into two sites: nasal cavity and ethmoid sinuses. The ethmoids are further subdivided into two subsites: left and right, separated by the nasal septum. The nasal cavity is divided into four subsites: the septum, floor, lateral wall, and vestibule.

Site	Subsite
Maxillary Sinus	Left/Right
Nasal Cavity	Septum Floor Lateral wall Vestibule
Ethmoid sinus	Left Right

**Regional Lymph Nodes.** Regional lymph node spread from cancer of nasal cavity and paranasal sinuses is relatively uncommon. Involvement of buccinator, submandibular, upper jugular, and (occasionally) retropharyngeal nodes may occur with advanced maxillary sinus cancer, particularly those extending beyond the sinus walls to involve adjacent structures, including soft tissues of the cheek, upper alveolus, palate, and buccal mucosa. Ethmoid sinus cancers are less prone to regional lymphatic spread. When only one side of the neck is involved, it should be considered ipsilateral. Bilateral spread may occur with advanced primary cancer, particularly with spread of the primary beyond the midline.

In clinical evaluation, the physical size of the nodal mass should be measured. Most masses over 3 cm in diameter are

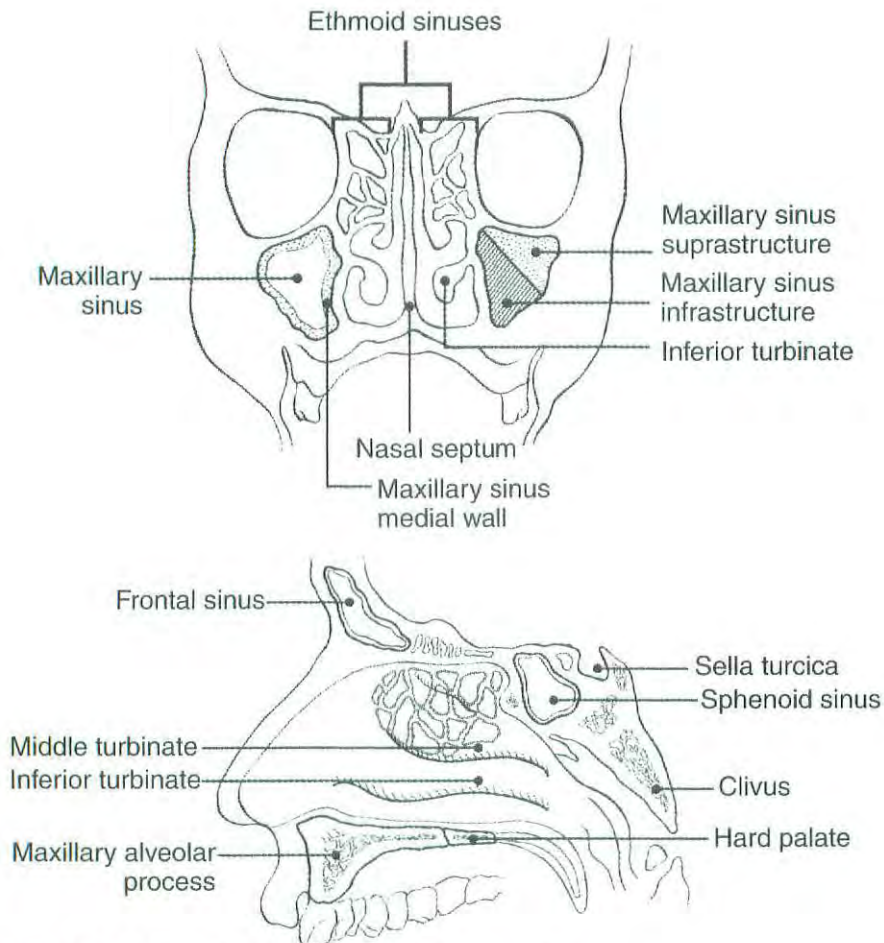


FIG. 6.1A, B. Sites of origin of tumors of the paranasal sinuses.

not single nodes but, rather, are confluent nodes or tumor in soft tissues of the neck. There are three categories of clinically positive nodes: N1, N2, and N3. The use of subgroups a, b, and c is not required but is recommended. Midline nodes are considered ipsilateral nodes. In addition to the components to describe the N category, regional lymph nodes should also be described according to the level of the neck that is involved. Pathologic examination is necessary for documentation of such disease extent. Imaging studies showing amorphous spiculated margins of involved nodes or involvement of internodal fat resulting in loss of normal oval-to-round nodal shape strongly suggest extracapsular (extranodal) tumor spread. No imaging study (as yet) can identify microscope foci in regional nodes or distinguish between small reactive nodes and small malignant nodes without central radiographic inhomogeneity.

For pN, a selective neck dissection will ordinarily include 6 or more lymph nodes, and a radical or modified radical neck dissection will ordinarily include 10 or more lymph nodes. Negative pathologic examination of a lesser number of lymph nodes still mandates a pN0 designation.

**Metastatic Sites.** Distant spread usually occurs to lungs but occasionally there is spread to bone.

## RULES FOR CLASSIFICATION

**Clinical Staging.** The assessment of primary maxillary sinus, nasal cavity, and ethmoid tumors is based on inspection and palpation, including examination of the orbits, nasal and oral cavities, and nasopharynx, and neurologic evaluation of the cranial nerves. Nasal endoscopy with rigid or fiberoptic flexible instruments is recommended. Radiologic assessment with magnetic resonance imaging (MRI) or computed tomography (CT) is mandatory for accurate pretreatment staging of malignant tumor of the sinuses. If available, MRI more accurately depicts skull base and intracranial involvement and the differentiation of fluid from solid tumor. Neck nodes are assessed by palpation +/- imaging. Imaging for possible nodal metastases is probably unnecessary in the presence of a clinically negative neck. Examinations for distant metastases include appropriate radiographs, blood chemistries, blood count, and other routine studies as indicated.

**Pathologic Staging.** Pathologic staging requires the use of all information obtained in clinical staging and histologic study of the surgically resected specimen. The surgeon's evaluation of gross unresected residual tumor must also be in-

cluded. Specimens that are resected after radiation or chemotherapy need to be identified and considered in context. The pathologic description of the lymphadenectomy specimen should describe the size, number, and position of the involved node(s) and the presence or absence of extracapsular extension.

## DEFINITION OF TNM

### Primary Tumor (T)

- TX Primary tumor cannot be assessed
- T0 No evidence of primary tumor
- Tis Carcinoma *in situ*

### Maxillary Sinus

- T1 Tumor limited to maxillary sinus mucosa with no erosion or destruction of bone
- T2 Tumor causing bone erosion or destruction including extension into the hard palate and/or middle nasal meatus, except extension to posterior wall of maxillary sinus and pterygoid plates
- T3 Tumor invades any of the following: bone of the posterior wall of maxillary sinus, subcutaneous tissues, floor or medial wall of orbit, pterygoid fossa, ethmoid sinuses
- T4a Tumor invades anterior orbital contents, skin of cheek, pterygoid plates, infratemporal fossa, cribriform plate, sphenoid or frontal sinuses
- T4b Tumor invades any of the following: orbital apex, dura, brain, middle cranial fossa, cranial nerves other than maxillary division of trigeminal nerve (V<sub>2</sub>), nasopharynx, or clivus

### Nasal Cavity and Ethmoid Sinus

- T1 Tumor restricted to any one subsite, with or without bony invasion
- T2 Tumor invading two subsites in a single region or extending to involve an adjacent region within the nasoethmoidal complex, with or without bony invasion
- T3 Tumor extends to invade the medial wall or floor of the orbit, maxillary sinus, palate, or cribriform plate
- T4a Tumor invades any of the following: anterior orbital contents, skin of nose or cheek, minimal extension to anterior cranial fossa, pterygoid plates, sphenoid or frontal sinuses
- T4b Tumor invades any of the following: orbital apex, dura, brain, middle cranial fossa, cranial nerves other than (V<sub>2</sub>), nasopharynx, or clivus

### Regional Lymph Nodes (N)

- NX Regional lymph nodes cannot be assessed
- N0 No regional lymph node metastasis
- N1 Metastasis in a single ipsilateral lymph node, 3 cm or less in greatest dimension

- N2 Metastasis in a single ipsilateral lymph node, more than 3 cm but not more than 6 cm in greatest dimension, or in multiple ipsilateral lymph nodes, none more than 6 cm in greatest dimension, or in bilateral or contralateral lymph nodes, none more than 6 cm in greatest dimension
- N2a Metastasis in a single ipsilateral lymph node, more than 3 cm but not more than 6 cm in greatest dimension
- N2b Metastasis in multiple ipsilateral lymph nodes, none more than 6 cm in greatest dimension
- N2c Metastasis in bilateral or contralateral lymph nodes, none more than 6 cm in greatest dimension
- N3 Metastasis in a lymph node, more than 6 cm in greatest dimension

### Distant Metastasis (M)

- MX Distant metastasis cannot be assessed
- M0 No distant metastasis
- M1 Distant metastasis

## STAGE GROUPING

Stage 0	Tis	N0	M0
Stage I	T1	N0	M0
Stage II	T2	N0	M0
Stage III	T3	N0	M0
	T1	N1	M0
	T2	N1	M0
Stage IVA	T3	N1	M0
	T4a	N0	M0
	T4a	N1	M0
Stage IVB	T1	N2	M0
	T2	N2	M0
	T3	N2	M0
	T4a	N2	M0
Stage IVC	T4b	Any N	M0
	Any T	N3	M0
Stage IVC	Any T	Any N	M1

## HISTOPATHOLOGIC TYPE

The predominant cancer is squamous cell carcinoma. The staging guidelines are applicable to all forms of carcinoma. Nonepithelial tumors such as those of lymphoid tissue, soft tissue, bone, and cartilage are not included. Histologic confirmation of diagnosis is required. Histopathologic grading of squamous carcinoma is recommended. The grade is subjective and uses a descriptive as well as a numerical form (i.e., well differentiated, moderately differentiated, and poorly differentiated), depending on the degree of closeness to or deviation from squamous epithelium in mucosal sites.

Also recommended where feasible is a quantitative evaluation of depth of invasion of the primary tumor and the presence or absence of vascular invasion and perineural invasion. Although the grade of the tumor does not enter into the staging of the tumor, it should be recorded. The pathologic description of any lymphadenectomy specimen should describe the size, number, and position of the involved node(s) and the presence or absence of extracapsular extension.

## HISTOLOGIC GRADE (G)

- GX Grade cannot be assessed
- G1 Well differentiated
- G2 Moderately differentiated
- G3 Poorly differentiated

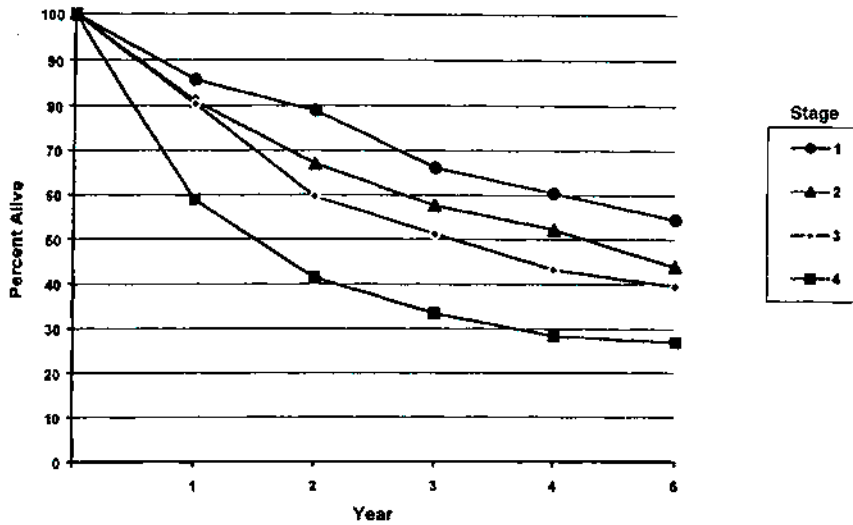
## PROGNOSTIC FACTORS

In addition to the importance of the TNM factors outlined previously, the overall health of these patients clearly influences outcome. Comorbidity can be classified by more general measures, such as the Karnofsky performance score, or by more specific measures, such as the Kaplan-Feinstein Index or the Charlson Index, and it can increase in incidence and severity with increasing age. Continued exposure to carcinogens, such as alcohol and tobacco smoke, probably affects patients' outcomes adversely.

Figures 6.2A and 6.2B show observed and relative survival rates for patients with cancer of the maxillary sinus for the years 1985–1991, classified by the AJCC staging classification.

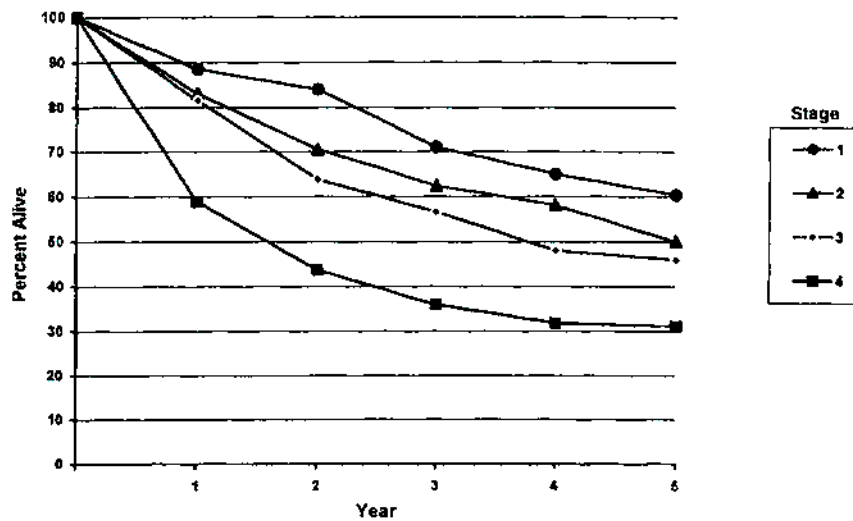
## BIBLIOGRAPHY

- Bridger GP, Mendelsohn MS, Baldwin M, et al: Paranasal sinus cancer. *Aust N Z J Surg* 61:290–294, 1991
- Cantu G, Solero CL, Mariani L, et al: A new classification for malignant tumors involving the anterior skull base. *Arch Otolaryngol Head Neck Surg* 125:1252–1257, 1999
- Jiang GL, Ang KA, Peters LJ, et al: Maxillary sinus carcinomas: natural history and results of postoperative radiotherapy. *Radiother Oncol* 21:194–200, 1991
- Jiang GL, Morrison WH, Garden AS, et al: Ethmoid sinus carcinoma: natural history and treatment results. *Radiother Oncol* 49:21–27, 1998
- Kondo M, Horiuchi M, Shiga H, et al: CT of malignant tumors of the nasal cavity and paranasal sinuses. *Cancer* 50:226–231, 1982
- Le QT, Fu KK, Kaplan M, et al: Treatment of maxillary sinus carcinoma. A comparison of the 1997 and 1977 American Joint Committee on Cancer Staging Systems. *Cancer* 86:1700–1711, 1999
- Paulino AFG, Singh B, Carew J, et al: Epstein-Barr virus in squamous carcinoma of the anterior nasal cavity. *Ann Diagn Pathol* 4:7–10, 2000
- Piccirillo JF: Inclusion of comorbidity in a staging system for head and neck cancer. *Oncology* 9:831–836, 1995
- Shah JP, Kraus DH, Bilsky MH, et al: Craniofacial resection for malignant tumors involving the anterior skull base. *Arch Otolaryngol Head Neck Surg* 13:1312–1317, 1997
- Singh B, Bhaya M, Zimble M, et al: Impact of comorbidity on outcome of young patients with head and neck squamous cell carcinoma. *Head Neck* 20:1–7, 1998
- Sisson GA, Toriumi DM, Atiyah RH: Paranasal sinus malignancy: a comprehensive update. *Laryngoscope* 99:143–150, 1989
- Som PM, Dillon WP, Sze G, et al: Benign and malignant sinonasal lesions with intracranial extension: differentiation with MRI imaging. *Radiology* 172:763–766, 1989
- Van Tassel P, Lee YY: GD-DTPA enhanced MR for detecting intracranial extension of sinonasal malignancies. *JCAT* 15:387–392, 1991



OBSERVED SURVIVAL BY STAGE	1	2	3	4	5	95% Cis*	CASES
1	85.7	78.9	66.0	60.4	54.5	41.4 - 67.6	65
2	81.0	68.9	57.6	52.2	43.8	32.6 - 54.9	87
3	80.4	59.6	51.2	43.2	39.5	31.5 - 47.5	162
4	58.9	51.4	33.4	28.4	27.0	22.2 - 31.8	364

FIG. 6.2A. Five-year, observed survival by "combined" AJCC stage for cancer of the maxillary sinus, 1985-1991. (\*95% confidence intervals correspond to year-5 survival rates.)



RELATIVE SURVIVAL BY STAGE	1	2	3	4	5	95% Cis*	CASES
1	88.5	84.0	71.0	65.0	60.4	45.5 - 75.3	67
2	83.1	70.5	62.4	58.1	50.0	37.1 - 62.9	87
3	81.6	63.8	58.6	47.9	45.9	36.8 - 55.0	167
4	58.9	43.6	35.9	31.8	31.1	25.5 - 36.7	370

FIG. 6.2B. Five-year, relative survival by "combined" AJCC stage for cancer of the maxillary sinus, 1985-1991. (\*95% confidence intervals correspond to year-5 survival rates.)

## HISTOLOGIES—PARANASAL SINUSES

8010/2	Carcinoma <i>in situ</i> , NOS	8083/3	Basaloid squamous cell carcinoma
8010/3	Carcinoma, NOS	8084/3	Squamous cell carcinoma, clear cell type
8012/3	Large cell carcinoma, NOS	8090/3	Basal cell carcinoma, NOS
8013/3	Large cell neuroendocrine carcinoma	8091/3	Multifocal superficial basal cell carcinoma
8020/3	Carcinoma, undifferentiated, NOS	8092/3	Infiltrating basal cell carcinoma, NOS
8021/3	Carcinoma, anaplastic, NOS	8093/3	Basal cell carcinoma, fibroepithelial
8030/3	Giant cell and spindle cell carcinoma	8094/3	Basosquamous carcinoma
8031/3	Giant cell carcinoma	8097/3	Basal cell carcinoma, nodular
8032/3	Spindle cell carcinoma, NOS	8098/3	Adenoid basal carcinoma
8033/3	Pseudosarcomatous carcinoma	8123/3	Basaloid carcinoma
8041/3	Small cell carcinoma, NOS	8140/2	Adenocarcinoma <i>in situ</i> , NOS
8042/3	Oat cell carcinoma	8140/3	Adenocarcinoma, NOS
8043/3	Small cell carcinoma, fusiform cell	8144/3	Adenocarcinoma, intestinal type
8044/3	Small cell carcinoma, intermediate cell	8145/3	Carcinoma, diffuse type
8045/3	Combined small cell carcinoma	8147/3	Basal cell adenocarcinoma
8051/3	Verrucous carcinoma, NOS	8200/3	Adenoid cystic carcinoma
8052/2	Papillary squamous cell carcinoma, non-invasive	8246/3	Neuroendocrine carcinoma, NOS
8052/3	Papillary squamous cell carcinoma	8310/3	Clear cell adenocarcinoma, NOS
8070/2	Squamous cell carcinoma <i>in situ</i> , NOS	8430/3	Mucoepidermoid carcinoma
8070/3	Squamous cell carcinoma, NOS	8440/3	Cystadenocarcinoma, NOS
8071/3	Squamous cell carcinoma, keratinizing, NOS	8480/3	Mucinous adenocarcinoma
8072/3	Squamous cell carcinoma, large cell	8481/3	Mucin-producing adenocarcinoma
8073/3	Squamous cell carcinoma, small cell, non-keratinizing	8510/3	Medullary carcinoma, NOS
8074/3	Squamous cell carcinoma, spindle cell	8525/3	Polymorphous low-grade adenocarcinoma
8075/3	Squamous cell carcinoma, adenoid	8550/3	Acinar cell carcinoma
8076/2	Squamous cell carcinoma <i>in situ</i> with questionable stromal invasion	8560/3	Adenosquamous carcinoma
8076/3	Squamous cell carcinoma, microinvasive	8562/3	Epithelial-myoepithelial carcinoma
8082/3	Lymphoepithelial carcinoma	8574/3	Adenocarcinoma with neuroendocrine differentiation
		8940/3	Mixed tumor, malignant, NOS
		8941/3	Carcinoma in pleomorphic adenoma



# NASAL CAVITY AND PARANASAL SINUSES

**Hospital Name/Address**

**Patient Name/Information**

2

Type of Specimen \_\_\_\_\_  
Tumor Size \_\_\_\_\_

Histopathologic Type \_\_\_\_\_  
Laterality:     Bilateral     Left     Right

**DEFINITIONS**

**Primary Tumor (T)**

<i>Clinical</i>	<i>Pathologic</i>	<i>Maxillary Sinus</i>
<input type="checkbox"/>	<input type="checkbox"/>	TX Primary tumor cannot be assessed
<input type="checkbox"/>	<input type="checkbox"/>	T0 No evidence of primary tumor
<input type="checkbox"/>	<input type="checkbox"/>	Tis Carcinoma <i>in situ</i>
<input type="checkbox"/>	<input type="checkbox"/>	T1 Tumor limited to the maxillary sinus mucosa with no erosion or destruction of bone
<input type="checkbox"/>	<input type="checkbox"/>	T2 Tumor causing bone erosion or destruction including extension into the hard palate and/or middle nasal meatus, except extension to posterior wall of maxillary sinus and pterygoid plates
<input type="checkbox"/>	<input type="checkbox"/>	T3 Tumor invades any of the following: bone of the posterior wall of maxillary sinus, subcutaneous tissues, floor or medial wall of orbit, pterygoid fossa, ethmoid sinuses
<input type="checkbox"/>	<input type="checkbox"/>	T4a Tumor invades anterior orbital contents, skin of cheek, pterygoid plates, infratemporal fossa, cribriform plate, sphenoid or frontal sinuses
<input type="checkbox"/>	<input type="checkbox"/>	T4b Tumor invades any of the following: orbital apex, dura, brain, middle cranial fossa, cranial nerves other than maxillary division of trigeminal nerve V <sub>2</sub> , nasopharynx, or clivus

*Nasal Cavity and Ethmoid Sinus*

<input type="checkbox"/>	<input type="checkbox"/>	TX Primary tumor cannot be assessed
<input type="checkbox"/>	<input type="checkbox"/>	T0 No evidence of primary tumor
<input type="checkbox"/>	<input type="checkbox"/>	Tis Carcinoma <i>in situ</i>
<input type="checkbox"/>	<input type="checkbox"/>	T1 Tumor restricted to any one subsite, with or without bony invasion
<input type="checkbox"/>	<input type="checkbox"/>	T2 Tumor invading two subsites in a single region or extending to involve an adjacent region within the nasoethmoidal complex, with or without bony invasion
<input type="checkbox"/>	<input type="checkbox"/>	T3 Tumor extends to invade the medial wall or floor of the orbit, maxillary sinus, palate, or cribriform plate
<input type="checkbox"/>	<input type="checkbox"/>	T4a Tumor invades any of the following: anterior orbital contents, skin of nose or cheek, minimal extension to anterior cranial fossa, pterygoid plates, sphenoid or frontal sinuses
<input type="checkbox"/>	<input type="checkbox"/>	T4b Tumor invades any of the following: orbital apex, dura, brain, middle cranial fossa, cranial nerves other than V <sub>2</sub> , nasopharynx, or clivus

**Regional Lymph Nodes (N)**

<input type="checkbox"/>	<input type="checkbox"/>	NX Regional lymph nodes cannot be assessed
<input type="checkbox"/>	<input type="checkbox"/>	N0 No regional lymph node metastasis
<input type="checkbox"/>	<input type="checkbox"/>	N1 Metastasis in a single ipsilateral lymph node, 3 cm or less in greatest dimension
<input type="checkbox"/>	<input type="checkbox"/>	N2 Metastasis in a single ipsilateral lymph node, more than 3 cm but not more than 6 cm in greatest dimension, or in multiple ipsilateral lymph nodes, none more than 6 cm in greatest dimension, or in bilateral or contralateral lymph nodes, none more than 6 cm in greatest dimension
<input type="checkbox"/>	<input type="checkbox"/>	N2a Metastasis in a single ipsilateral lymph node, more than 3 cm but not more than 6 cm in greatest dimension
<input type="checkbox"/>	<input type="checkbox"/>	N2b Metastasis in multiple ipsilateral lymph nodes, none more than 6 cm in greatest dimension
<input type="checkbox"/>	<input type="checkbox"/>	N2c Metastasis in bilateral or contralateral lymph nodes, none more than 6 cm in greatest dimension
<input type="checkbox"/>	<input type="checkbox"/>	N3 Metastasis in a lymph node, more than 6 cm in greatest dimension

**Distant Metastasis (M)**

<input type="checkbox"/>	<input type="checkbox"/>	MX Distant metastasis cannot be assessed
<input type="checkbox"/>	<input type="checkbox"/>	M0 No distant metastasis
<input type="checkbox"/>	<input type="checkbox"/>	M1 Distant metastasis

Biopsy of metastatic site performed .....  Y .....  N

Source of pathologic metastatic specimen \_\_\_\_\_ (continued on reverse side)

Clinical	Pathologic	Stage Grouping			Notes	
<input type="checkbox"/>	<input type="checkbox"/>	0	Tis	N0	M0	<b>Additional Descriptors</b> Lymphatic Vessel Invasion (L) LX Lymphatic vessel invasion cannot be assessed L0 No lymphatic vessel invasion L1 Lymphatic vessel invasion Venous Invasion (V) VX Venous invasion cannot be assessed V0 No venous invasion V1 Microscopic venous invasion V2 Macroscopic venous invasion
<input type="checkbox"/>	<input type="checkbox"/>	I	T1	N0	M0	
<input type="checkbox"/>	<input type="checkbox"/>	II	T2	N0	M0	
<input type="checkbox"/>	<input type="checkbox"/>	III	T3	N0	M0	
			T1	N1	M0	
			T2	N1	M0	
			T3	N1	M0	
<input type="checkbox"/>	<input type="checkbox"/>	IVA	T4a	N0	M0	
			T4a	N1	M0	
			T1	N2	M0	
			T2	N2	M0	
			T3	N2	M0	
<input type="checkbox"/>	<input type="checkbox"/>	IVB	T4a	N2	M0	
			T4b	Any N	M0	
<input type="checkbox"/>	<input type="checkbox"/>	IVC	Any T	N3	M0	
			Any T	Any N	M1	

**Histologic Grade (G)**

- GX Grade cannot be assessed
- G1 Well differentiated
- G2 Moderately differentiated
- G3 Poorly differentiated

**Residual Tumor (R)**

- RX Presence of residual tumor cannot be assessed
- R0 No residual tumor
- R1 Microscopic residual tumor
- R2 Macroscopic residual tumor

**Additional Descriptors**

For identification of special cases of TNM or pTNM classifications, the "m" suffix and "y," "r," and "a" prefixes are used. Although they do not affect the stage grouping, they indicate cases needing separate analysis.

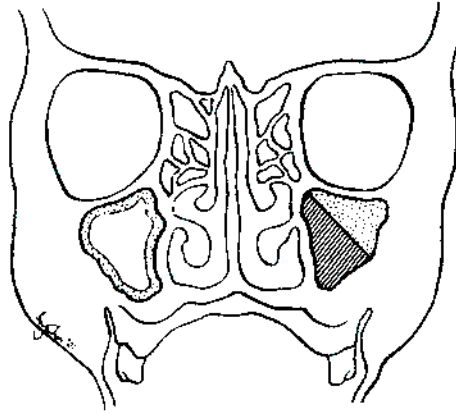
- m suffix** indicates the presence of multiple primary tumors in a single site and is recorded in parentheses: pT(m)NM.
- y prefix** indicates those cases in which classification is performed during or following initial multimodality therapy. The cTNM or pTNM category is identified by a "y" prefix. The ycTNM or ypTNM categorizes the extent of tumor actually present at the time of that examination. The "y" categorization is not an estimate of tumor prior to multimodality therapy.
- r prefix** indicates a recurrent tumor when staged after a disease-free interval, and is identified by the "r" prefix: rTNM.
- a prefix** designates the stage determined at autopsy: aTNM.

**Prognostic Indicators (if applicable)**

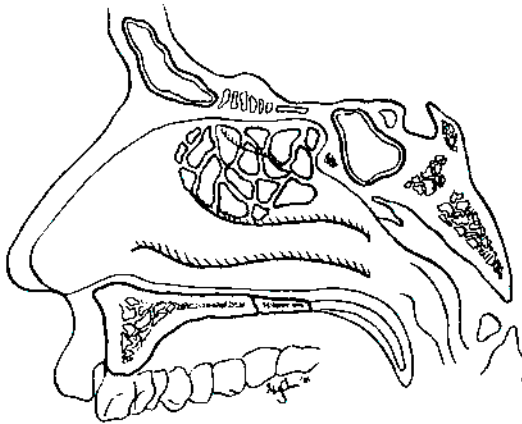
**ILLUSTRATION**

Indicate on diagram primary tumor and regional nodes involved.

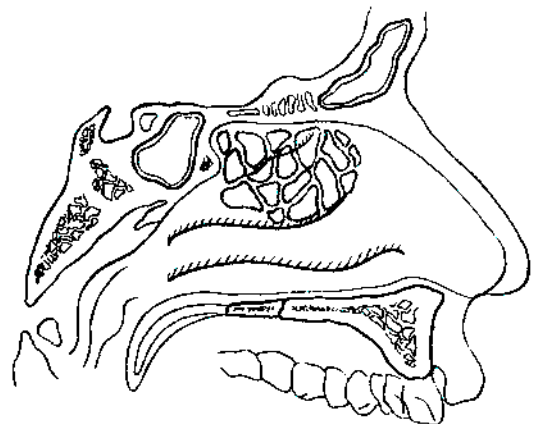
1.



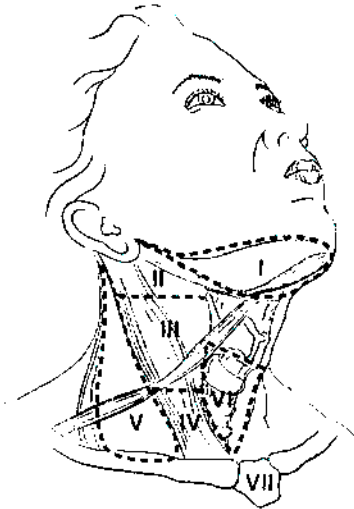
2.



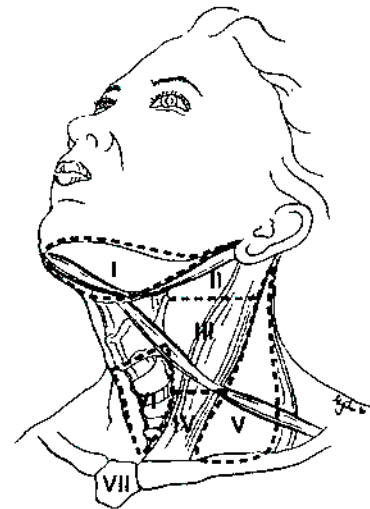
3.



4.



5.



Physician's Signature \_\_\_\_\_ Date \_\_\_\_\_

# Major Salivary Glands

(Parotid, Submandibular, and Sublingual)

C07.9 Parotid gland

C08.0 Submandibular gland

C08.1 Sublingual gland

C08.8 Overlapping lesion of major salivary glands

C08.9 Major salivary gland, NOS

## SUMMARY OF CHANGES

- In order to maintain internal consistency of T staging across all sites, the description for T3 has been revised. In addition to tumors having extraparenchymal extension, all tumors larger than 4 cm are considered T3.
- T4 lesions have been divided into T4a (resectable) and T4b (unresectable), leading to the division of Stage IV into Stage IVA, Stage IVB, and Stage IVC.

This staging system is based on an extensive retrospective review of the world literature regarding malignant tumors of the major salivary glands. Numerous factors affect patient survival, including the histologic diagnosis, cellular differentiation of the tumor (grade), site, size, degree of fixation or local extension, facial nerve involvement, and the status of regional lymph nodes as well as distant metastases. The classification involves the four dominant clinical variables: tumor size, local extension of the tumor, nodal metastasis, and distant metastasis. The T4 category has been divided into T4a and T4b. T4a indicates advanced lesions that are resectable with grossly clear margins; T4b reflects extension to areas that preclude resection with clear margins. Histologic grade, patient age, and tumor site are important additional factors that should be recorded for future analysis and potential inclusion in the staging system.

## ANATOMY

**Primary Site.** The major salivary glands include the parotid, submandibular, and sublingual glands. Tumors arising in minor salivary glands (mucus-secreting glands in the lining membrane of the upper aerodigestive tract) are staged according to the anatomic site of origin (e.g., oral cavity, sinuses, etc.).

Primary tumors of the parotid constitute the largest proportion of salivary gland tumors. Sublingual primary cancers are rare and may be difficult to distinguish with certainty from minor salivary gland primary tumors of the anterior floor of the mouth.

**Regional Lymph Nodes.** Regional lymphatic spread from salivary gland cancer is less common than from head and neck mucosal squamous cancers and varies according to the histology and size of the primary tumor. Most nodal metastases will be clinically apparent on initial evaluation. Low-grade tumors rarely metastasize to regional nodes, whereas the risk of regional spread is substantially higher from high-grade cancers. Regional dissemination tends to be orderly, progressing from intraglandular to adjacent (periparotid, submandibular) nodes, then to upper and midjugular nodes, and occasionally to retropharyngeal nodes. Bilateral lymphatic spread is rare.

For pathologic reporting (pN), histologic examination of a selective neck dissection will ordinarily include 6 or more lymph nodes and a radical or modified radical neck dissection will ordinarily include 10 or more lymph nodes. Negative pathologic evaluation of a lesser number of nodes still mandates a pN0 designation.

**Metastatic Sites.** Distant spread is most frequently to the lungs.

## RULES FOR CLASSIFICATION

**Clinical Staging.** The assessment of primary salivary gland tumors includes a pertinent history (pain, trismus, etc.), inspection, palpation, and evaluation of the cranial nerves. Radiologic studies may add information valuable for staging. The soft tissues of the neck from the skull base to the hyoid bone must be studied, with the lower neck included whenever lymph node metastases are suspected. Images of

the intratemporal facial nerve are critical to the identification of perineural tumor in this area. Cancers of the submandibular and sublingual salivary glands merit cross-sectional imaging. Computed tomography (CT) or MRI may be useful in assessing the extent of deep extraglandular tumor, bone invasion, and deep tissue extent (extrinsic tongue muscle and/or soft tissues of the neck).

**Pathologic Staging.** The surgical pathology report and all other available data should be used to assign a pathologic classification to those patients who have resection of the cancer.

## DEFINITION OF TNM

### Primary Tumor (T)

- TX Primary tumor cannot be assessed
- T0 No evidence of primary tumor
- T1 Tumor 2 cm or less in greatest dimension without extraparenchymal extension\*
- T2 Tumor more than 2 cm but not more than 4 cm in greatest dimension without extraparenchymal extension\*
- T3 Tumor more than 4 cm and/or tumor having extraparenchymal extension\*
- T4a Tumor invades skin, mandible, ear canal, and/or facial nerve
- T4b Tumor invades skull base and/or pterygoid plates and/or encases carotid artery

\*Note: Extraparenchymal extension is clinical or macroscopic evidence of invasion of soft tissues. Microscopic evidence alone does not constitute extraparenchymal extension for classification purposes.

### Regional Lymph Nodes (N)

- NX Regional lymph nodes cannot be assessed
- N0 No regional lymph node metastasis
- N1 Metastasis in a single ipsilateral lymph node, 3 cm or less in greatest dimension
- N2 Metastasis in a single ipsilateral lymph node, more than 3 cm but not more than 6 cm in greatest dimension, or in multiple ipsilateral lymph nodes, none more than 6 cm in greatest dimension, or in bilateral or contralateral lymph nodes, none more than 6 cm in greatest dimension
- N2a Metastasis in a single ipsilateral lymph node, more than 3 cm but not more than 6 cm in greatest dimension
- N2b Metastasis in multiple ipsilateral lymph nodes, none more than 6 cm in greatest dimension
- N2c Metastasis in bilateral or contralateral lymph nodes, none more than 6 cm in greatest dimension
- N3 Metastasis in a lymph node, more than 6 cm in greatest dimension

### Distant Metastasis (M)

- MX Distant metastasis cannot be assessed
- M0 No distant metastasis
- M1 Distant metastasis

## STAGE GROUPING

Stage I	T1	N0	M0
Stage II	T2	N0	M0
Stage III	T3	N0	M0
	T1	N1	M0
	T2	N1	M0
Stage IVA	T3	N1	M0
	T4a	N0	M0
	T4a	N1	M0
	T1	N2	M0
	T2	N2	M0
Stage IVB	T3	N2	M0
	T4a	N2	M0
	T4b	Any N	M0
Stage IVC	Any T	N3	M0
	Any T	Any N	M1

## HISTOPATHOLOGIC TYPE

The suggested histopathologic typing is that proposed by the World Health Organization.

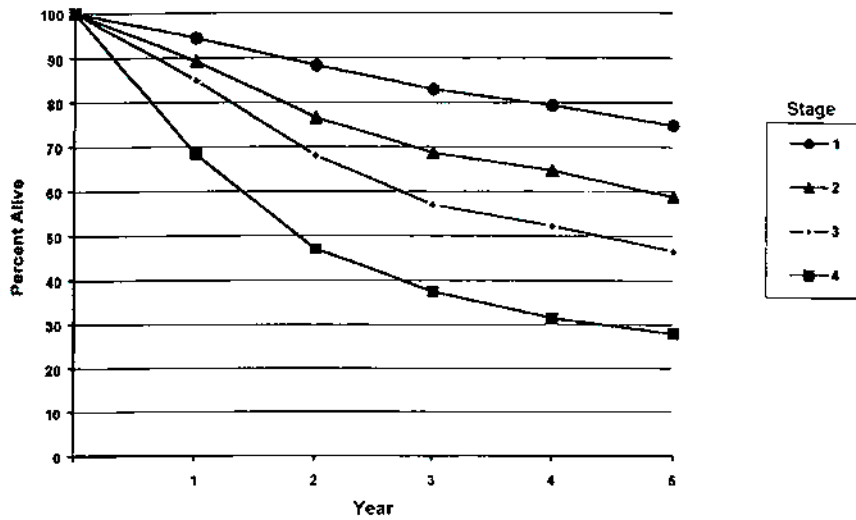
Acinic cell carcinoma  
 Mucoepidermoid carcinoma  
 Adenoid cystic carcinoma  
 Polymorphous low-grade adenocarcinoma  
 Epithelial-myoeplithelial carcinoma  
 Basal cell adenocarcinoma  
 Sebaceous carcinoma  
 Papillary cystadenocarcinoma  
 Mucinous adenocarcinoma  
 Oncocytic carcinoma  
 Salivary duct carcinoma  
 Adenocarcinoma  
 Myoepithelial carcinoma  
 Carcinoma in pleomorphic adenoma  
 Squamous cell carcinoma  
 Small cell carcinoma  
 Other carcinomas

## HISTOLOGIC GRADE (G)

Histologic grading is applicable only to some types of salivary cancer: mucoepidermoid carcinoma, adenocarcinoma not otherwise specified, or when either of these is the carcinomatous element of carcinoma in pleomorphic adenoma.

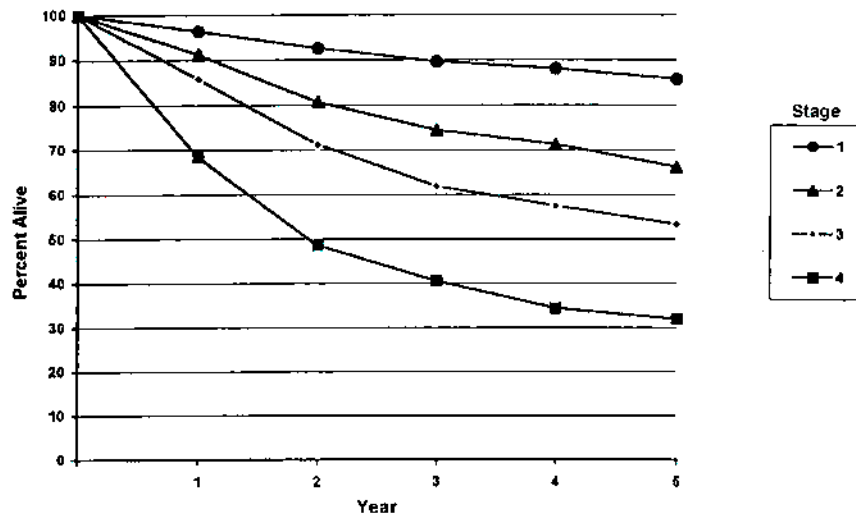
In most instances, the histologic type defines the grade (i.e., salivary duct carcinoma is high grade; basal cell adenocarcinoma is low grade).

Figures 7.1A and 7.1B show relative and observed survival rates for patients with cancer of the major salivary glands for the years 1985–1991, classified by the AJCC staging classification.



OBSERVED SURVIVAL BY STAGE	1	2	3	4	5	95% Cis*	CASES
1	94.3	88.3	83.0	79.3	74.9	72.1 – 77.6	1124
2	89.2	76.6	68.7	64.6	58.7	53.9 – 63.4	476
3	85.0	68.0	57.0	52.2	46.5	41.7 – 51.3	470
4	68.4	47.0	37.4	31.4	27.9	24.0 – 31.8	576

**FIG. 7.1A.** Five-year, observed survival by "combined" AJCC stage for cancer of the major salivary glands, 1985–1991. (\*95% confidence intervals correspond to year-5 survival rates.)



RELATIVE SURVIVAL BY STAGE	1	2	3	4	5	95% Cis*	CASES
1	96.3	92.5	89.6	88.1	85.8	82.7 – 89.0	1130
2	91.1	80.7	74.4	71.2	66.2	60.8 – 71.7	478
3	85.8	71.2	61.9	57.4	53.3	47.8 – 58.7	477
4	68.4	48.5	40.5	34.3	31.9	7.5 – 36.4	580

**FIG. 7.1B.** Five-year, relative survival by "combined" AJCC stage for cancer of the major salivary glands, 1985–1991. (\*95% confidence intervals correspond to year-5 survival rates.)

## BIBLIOGRAPHY

- Batsakis JG, Luna MA: Histopathologic grading of salivary gland neoplasms: I. Mucoepidermoid carcinomas. *Ann Otol Rhinol Laryngol* 99:835-838, 1990
- Beckhardt RN, Weber RS, Zane R, et al: Minor salivary gland tumors of the palate: clinical and pathologic correlates of outcome. *Laryngoscope* 105:1155-1160, 1995
- Calearo C, Pastore A, Storch OF, et al: Parotid gland carcinoma: analysis of prognostic factors. *Ann Otol Rhinol Laryngol* 107:969-973, 1998
- Frankenthaler RA, Luna MA, Lee SS, et al: Prognostic variables in parotid gland cancer. *Arch Otolaryngol Head Neck Surg* 11:1251-1256, 1991
- Gallo O, Franchi A, Bottai GV, et al: Risk factors for distant metastases from carcinoma of the parotid gland. *Cancer* 80:844-851, 1977
- Goepfert H, Luna MA, Lindberg RH, et al: Malignant salivary gland tumors of the paranasal sinuses and nasal cavity. *Arch Otolaryngol* 109:662-668, 1983
- Hicks MJ, el-Naggar AK, Byers RM, et al: Prognostic factors in mucoepidermoid carcinomas of major salivary glands: a clinicopathologic and flow cytometric study. *Eur J Cancer B Oral Oncol* 30B:329-334, 1994
- Hoffman HT, Karnell LH, Robinson RA, et al: National Cancer Data Base report on cancer of the head and neck: acinic cell carcinoma. *Head Neck* 21:297-309, 1999
- Iro H, Waldfahrer F. Evaluation of the newly updated TNM classification of head and neck carcinoma with data from 3,247 patients. *Cancer* 83:2201-2207, 1998
- Kane WJ, McCaffrey TV, Olsen KD, et al: Primary parotid malignancies: a clinical and pathologic review. *Arch Otolaryngol Head and Neck Surg* 117:307-315, 1991
- Lopes MA, Santos GC, Kowalski LP: Multivariate survival analysis of 128 cases of oral cavity minor salivary gland carcinomas. *Head Neck* 20:699-706, 1998
- Overgaard PD, Sogaard H, Elbrond O, et al: Malignant parotid tumors in 110 consecutive patients: treatment results and prognosis. *Laryngoscope* 102:1064-1069, 1992
- Renehan A, Gleave EN, Hancock BD et al: Long-term follow-up of over 1,000 patients with salivary gland tumours treated in a single centre. *Br J Surg* 83:1750-1754, 1996
- Seifert G, Sobin LH: Histological typing of salivary gland tumours. WHO international histological classification of tumours, 2nd ed. Berlin-Heidelberg-New York: Springer-Verlag, 1991
- Spiro RH: Salivary neoplasms: Overview of a 35-year experience with 2,807 patients. *Head Neck Surg* 8:177-184, 1986
- Spiro RH, Hajdu SI, Strong EW: Tumors of the submaxillary gland. *Am J Surg* 132:463-468, 1976
- Spiro RH, Huvos AG: Stage means more than grade in adenoid cystic carcinoma. *Am J Surg* 164:623-628, 1992
- Therkildsen MH, Christensen M, Andersen LJ, et al: Salivary gland carcinomas—prognostic factors. *Acta Oncol* 37:701-713, 1998
- Vander Poorten VL, Balm AJ, Hilgers FJ, et al: The development of a prognostic score for patients with parotid carcinoma. *Cancer* 85:2057-2067, 1999
- Vander Poorten VL, Balm AJ, Hilgers FJ, et al: Prognostic factors for long-term results of the treatment of patients with malignant submandibular gland tumors. *Cancer* 85:2255-2264, 1999

## HISTOLOGIES—MAJOR SALIVARY GLANDS

8010/3	Carcinoma, NOS
8013/3	Large cell neuroendocrine carcinoma
8020/3	Carcinoma, undifferentiated, NOS
8021/3	Carcinoma, anaplastic, NOS
8032/3	Spindle cell carcinoma, NOS
8033/3	Pseudosarcomatous carcinoma
8041/3	Small cell carcinoma, NOS
8042/3	Oat cell carcinoma
8043/3	Small cell carcinoma, fusiform cell
8044/3	Small cell carcinoma, intermediate cell
8045/3	Combined small cell carcinoma
8070/3	Squamous cell carcinoma, NOS
8076/3	Squamous cell carcinoma, microinvasive
8082/3	Lymphoepithelial carcinoma
8083/3	Basaloid squamous cell carcinoma
8140/3	Adenocarcinoma
8147/3	Basal cell adenocarcinoma
8200/3	Adenoid cystic carcinoma
8246/3	Neuroendocrine carcinoma, NOS
8290/3	Oncocytic carcinoma
8310/3	Clear cell adenocarcinoma, NOS
8410/3	Sebaceous carcinoma
8430/3	Mucoepidermoid carcinoma
8440/3	Cystadenocarcinoma, NOS
8441/3	Serous cystadenocarcinoma, NOS
8450/3	Papillary cystadenocarcinoma
8480/3	Mucinous adenocarcinoma
8525/3	Polymorphous low-grade adenocarcinoma
8550/3	Acinar cell carcinoma
8560/3	Adenosquamous carcinoma
8562/3	Epithelial-myoepithelial carcinoma
8940/3	Mixed tumor, malignant, NOS
8941/3	Carcinoma in pleomorphic adenoma
8982/3	Malignant myoepithelioma

# MAJOR SALIVARY GLANDS (PAROTID, SUBMANDIBULAR, AND SUBLINGUAL)

**Hospital Name/Address**

---



---



---

**Patient Name/Information**

---



---



---

2

Type of Specimen \_\_\_\_\_  
 Tumor Size \_\_\_\_\_

Histopathologic Type \_\_\_\_\_  
 Laterality:     Bilateral     Left     Right

### DEFINITIONS

Clinical	Pathologic		Primary Tumor (T)
<input type="checkbox"/>	<input type="checkbox"/>	TX	Primary tumor cannot be assessed
<input type="checkbox"/>	<input type="checkbox"/>	T0	No evidence of primary tumor
<input type="checkbox"/>	<input type="checkbox"/>	T1	Tumor 2 cm or less in greatest dimension without extraparenchymal extension <sup>(1)</sup>
<input type="checkbox"/>	<input type="checkbox"/>	T2	Tumor more than 2 cm but not more than 4 cm in greatest dimension without extraparenchymal extension <sup>(1)</sup>
<input type="checkbox"/>	<input type="checkbox"/>	T3	Tumor more than 4 cm and/or tumor having extraparenchymal extension <sup>(1)</sup>
<input type="checkbox"/>	<input type="checkbox"/>	T4a	Tumor invades skin, mandible, ear canal, and/or facial nerve
<input type="checkbox"/>	<input type="checkbox"/>	T4b	Tumor invades skull base and/or pterygoid plates and/or encases carotid artery

### Notes

1. Extraparenchymal extension is clinical or macroscopic evidence of invasion of soft tissues. Microscopic evidence alone does not constitute extraparenchymal extension for classification purposes.

Clinical	Pathologic		Regional Lymph Nodes (N)
<input type="checkbox"/>	<input type="checkbox"/>	NX	Regional lymph nodes cannot be assessed
<input type="checkbox"/>	<input type="checkbox"/>	N0	No regional lymph node metastasis
<input type="checkbox"/>	<input type="checkbox"/>	N1	Metastasis in a single ipsilateral lymph node, 3 cm or less in greatest dimension
<input type="checkbox"/>	<input type="checkbox"/>	N2	Metastasis in a single ipsilateral lymph node, more than 3 cm but not more than 6 cm in greatest dimension, or in multiple ipsilateral lymph nodes, none more than 6 cm in greatest dimension, or in bilateral or contralateral lymph nodes, none more than 6 cm in greatest dimension
<input type="checkbox"/>	<input type="checkbox"/>	N2a	Metastasis in a single ipsilateral lymph node, more than 3 cm but not more than 6 cm in greatest dimension
<input type="checkbox"/>	<input type="checkbox"/>	N2b	Metastasis in multiple ipsilateral lymph nodes, none more than 6 cm in greatest dimension
<input type="checkbox"/>	<input type="checkbox"/>	N2c	Metastasis in bilateral or contralateral lymph nodes, none more than 6 cm in greatest dimension
<input type="checkbox"/>	<input type="checkbox"/>	N3	Metastasis in a lymph node, more than 6 cm in greatest dimension

Clinical	Pathologic		Distant Metastasis (M)
<input type="checkbox"/>	<input type="checkbox"/>	MX	Distant metastasis cannot be assessed
<input type="checkbox"/>	<input type="checkbox"/>	M0	No distant metastasis
<input type="checkbox"/>	<input type="checkbox"/>	M1	Distant metastasis

Biopsy of metastatic site performed .....  Y .....  N  
 Source of pathologic metastatic specimen \_\_\_\_\_

Clinical	Pathologic		Stage Grouping
<input type="checkbox"/>	<input type="checkbox"/>	I	T1      N0      M0
<input type="checkbox"/>	<input type="checkbox"/>	II	T2      N0      M0
<input type="checkbox"/>	<input type="checkbox"/>	III	T3      N0      M0
			T1      N1      M0
			T2      N1      M0
			T3      N1      M0
<input type="checkbox"/>	<input type="checkbox"/>	IVA	T4a    N0      M0
			T4a    N1      M0
			T1      N2      M0
			T2      N2      M0
			T3      N2      M0
			T4a    N2      M0
<input type="checkbox"/>	<input type="checkbox"/>	IVB	T4b    Any N    M0
			Any T    N3      M0
<input type="checkbox"/>	<input type="checkbox"/>	IVC	Any T    Any N    M1

*(continued on reverse side)*



**Histologic Grade (G)**

Histologic grading is applicable only to some types of salivary cancer: mucoepidermoid carcinoma, adenocarcinoma not otherwise specified, or when either of these is the carcinomatous element of carcinoma in pleomorphic adenoma. In most instances, the histologic type defines the grade (i.e., salivary duct carcinoma is high grade; basal cell adenocarcinoma is low grade)

**Residual Tumor (R)**

- RX Presence of residual tumor cannot be assessed
- R0 No residual tumor
- R1 Microscopic residual tumor
- R2 Macroscopic residual tumor

**Additional Descriptors**

For identification of special cases of TNM or pTNM classifications, the “m” suffix and “y,” “r,” and “a” prefixes are used. Although they do not affect the stage grouping, they indicate cases needing separate analysis.

- m suffix** indicates the presence of multiple primary tumors in a single site and is recorded in parentheses: pT(m)NM.
- y prefix** indicates those cases in which classification is performed during or following initial multimodality therapy. The cTNM or pTNM category is identified by a “y” prefix. The ycTNM or ypTNM categorizes the extent of tumor actually present at the time of that examination. The “y” categorization is not an estimate of tumor prior to multimodality therapy.
- r prefix** indicates a recurrent tumor when staged after a disease-free interval, and is identified by the “r” prefix: rTNM.
- a prefix** designates the stage determined at autopsy: aTNM.

**Prognostic Indicators (if applicable)**

**Notes**

**Additional Descriptors**

**Lymphatic Vessel Invasion (L)**

- LX Lymphatic vessel invasion cannot be assessed
- L0 No lymphatic vessel invasion
- L1 Lymphatic vessel invasion

**Venous Invasion (V)**

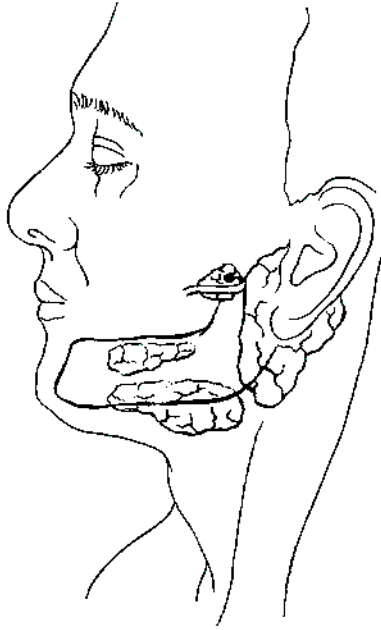
- VX Venous invasion cannot be assessed
- V0 No venous invasion
- V1 Microscopic venous invasion
- V2 Macroscopic venous invasion

**MAJOR SALIVARY GLANDS (PAROTID, SUBMANDIBULAR, AND SUBLINGUAL)**

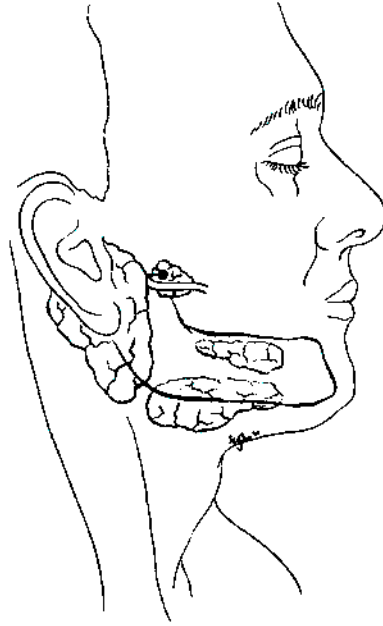
**ILLUSTRATION**

Indicate on diagram primary tumor and regional nodes involved.

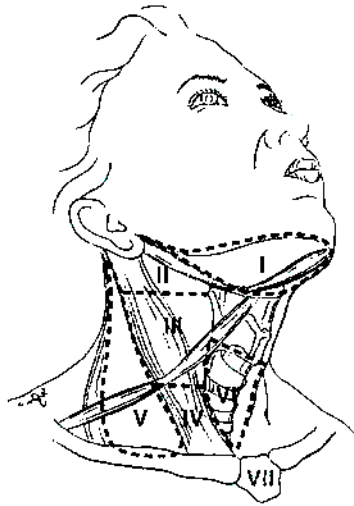
1.



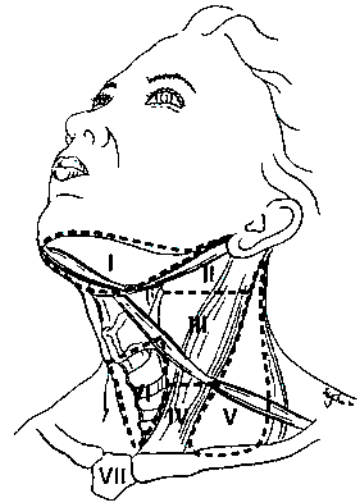
2.



3.



4.



Physician's Signature \_\_\_\_\_

Date \_\_\_\_\_

C73.9 Thyroid gland

**SUMMARY OF CHANGES**

- Tumor staging (T) has been revised and the categories redefined.
- T4 is now divided into T4a and T4b.
- Nodal staging (N) has been revised.
- All anaplastic carcinomas are considered T4. The T4 category for anaplastic carcinomas is divided into T4a (intrathyroidal anaplastic carcinoma—surgically resectable) and T4b (extrathyroidal anaplastic carcinoma—surgically unresectable).
- For papillary and follicular carcinomas, the stage grouping for patients older than 45 has been revised. Stage III includes tumors with minimal extrathyroid extension. Stage IVA includes tumors of any size extending beyond the thyroid capsule to invade subcutaneous soft tissues, larynx, trachea, esophagus OR recurrent laryngeal nerve. Stage IVB includes tumors that invade prevertebral fascia, carotid artery, or mediastinal vessels. Stage IVC includes advanced tumors with distant metastasis.

Although staging for cancers in other head and neck sites is based entirely on the anatomic extent of disease, it is not possible to follow this pattern for the unique group of malignant tumors that arise in the thyroid gland. Both the *histologic diagnosis* and the *age* of the patient are of such importance in the behavior and prognosis of thyroid cancer that these factors are included in this staging system.

**ANATOMY**

**Primary Site.** The thyroid gland ordinarily is composed of a right and a left lobe lying adjacent and lateral to the upper trachea and esophagus. An isthmus connects the two lobes, and in some cases a pyramidal lobe is present extending upward anterior to the thyroid cartilage.

**Regional Lymph Nodes.** Regional lymph node spread from thyroid cancer is common but of less prognostic significance in patients with well-differentiated tumors (papillary, follicular) than in medullary cancers. The adverse prognostic influence of lymph node metastasis in patients with differentiated carcinomas is observed, only in the older age group. The first echelon of nodal metastasis consists of the

paralaryngeal, paratracheal, and prelaryngeal (Delphian) nodes adjacent to the thyroid gland in the central compartment of the neck generally described as Level VI. Metastases secondarily involve the mid- and lower jugular, the supraclavicular, and (much less commonly) the upper deep jugular and spinal accessory lymph nodes. Lymph node metastasis to submandibular and submental lymph nodes is very rare. Upper mediastinal (Level VII) nodal spread occurs frequently both anteriorly and posteriorly. Retropharyngeal nodal metastasis may be seen, usually in the presence of extensive lateral cervical metastasis. Bilateral nodal spread is common. The components of the N category are described as follows: first echelon (central compartment/Level VI), or N1a, and lateral cervical and/or superior mediastinal or N1b. The lymph node metastasis should also be described according to the level of the neck that is involved. Nodal metastases from medullary thyroid cancer carry a much more ominous prognosis, although they follow a similar pattern of spread.

For pN, histologic examination of a selective neck dissection will ordinarily include 6 or more lymph nodes, whereas histologic examination of a radical or a modified radical comprehensive neck dissection will ordinarily include 10 or more lymph nodes. Negative pathologic evaluation of a lesser number of nodes still mandates a pN0 designation.

**Metastatic Sites.** Distant spread occurs by hematogenous routes—for example to lungs and bones—but many other sites may be involved.

## RULES FOR CLASSIFICATION

**Clinical Staging.** The assessment of a thyroid tumor depends on inspection and palpation of the thyroid gland and regional lymph nodes. Indirect laryngoscopy to evaluate vocal cord motion is essential. A variety of imaging procedures can provide additional useful information. These include radioisotope thyroid scans, ultrasonography, computed tomography scans (CT), and magnetic resonance imaging (MRI) scans. When cross-sectional imaging is utilized, MRI is recommended so as to avoid contamination of the body with the iodinated contrast medium generally used with CT. Iodinated contrast media make it necessary to delay the postoperative administration of radioactive iodine-131. The diagnosis of thyroid cancer must be confirmed by needle biopsy or open biopsy of the tumor. Further information for clinical staging may be obtained by biopsy of lymph nodes or other areas of suspected local or distant spread. All information available prior to first treatment should be used.

**Pathologic Staging.** Pathologic staging requires the use of all information obtained in the clinical staging, as well as histologic study of the surgically resected specimen. The surgeon's description of gross unresected residual tumor must also be included.

## DEFINITION OF TNM

### Primary Tumor (T)

*Note:* All categories may be subdivided: (a) solitary tumor, (b) multifocal tumor (the largest determines the classification).

TX	Primary tumor cannot be assessed
T0	No evidence of primary tumor
T1	Tumor 2 cm or less in greatest dimension limited to the thyroid
T2	Tumor more than 2 cm but not more than 4 cm in greatest dimension limited to the thyroid
T3	Tumor more than 4 cm in greatest dimension limited to the thyroid or any tumor with minimal extrathyroid extension (e.g., extension to sternothyroid muscle or perithyroid soft tissues)
T4a	Tumor of any size extending beyond the thyroid capsule to invade subcutaneous soft tissues, larynx, trachea, esophagus, or recurrent laryngeal nerve

T4b Tumor invades prevertebral fascia or encases carotid artery or mediastinal vessels

*All anaplastic carcinomas are considered T4 tumors.*

T4a Intrathyroidal anaplastic carcinoma—surgically resectable.

T4b Extrathyroidal anaplastic carcinoma—surgically unresectable

### Regional Lymph Nodes (N)

Regional lymph nodes are the central compartment, lateral cervical, and upper mediastinal lymph nodes.

NX Regional lymph nodes cannot be assessed.

N0 No regional lymph node metastasis

N1 Regional lymph node metastasis

N1a Metastasis to Level VI (pretracheal, paratracheal, and prelaryngeal/Delphian lymph nodes)

N1b Metastasis to unilateral, bilateral, or contralateral cervical or superior mediastinal lymph nodes

### Distant Metastasis (M)

MX Distant metastasis cannot be assessed

M0 No distant metastasis

M1 Distant metastasis

## STAGE GROUPING

Separate stage groupings are recommended for papillary or follicular, medullary, and anaplastic (undifferentiated) carcinoma.

<i>Papillary or Follicular</i>			
UNDER 45 YEARS			
Stage I	Any T	Any N	M0
Stage II	Any T	Any N	M1
<i>Papillary or Follicular</i>			
45 YEARS AND OLDER			
Stage I	T1	N0	M0
Stage II	T2	N0	M0
Stage III	T3	N0	M0
	T1	N1a	M0
	T2	N1a	M0
Stage IVA	T3	N1a	M0
	T4a	N0	M0
	T4a	N1a	M0
Stage IVB	T1	N1b	M0
	T2	N1b	M0
	T3	N1b	M0
	T4a	N1b	M0
Stage IVB	T4b	Any N	M0
Stage IVC	Any T	Any N	M1

*continued*

**STAGE GROUPING (continued)**

<i>Medullary Carcinoma</i>			
Stage I	T1	N0	M0
Stage II	T2	N0	M0
Stage III	T3	N0	M0
	T1	N1a	M0
	T2	N1a	M0
	T3	N1a	M0
Stage IVA	T4a	N0	M0
	T4a	N1a	M0
	T1	N1b	M0
	T2	N1b	M0
	T3	N1b	M0
	T4a	N1b	M0
Stage IVB	T4b	Any N	M0
Stage IVC	Any T	Any N	M1

*Anaplastic Carcinoma*

All anaplastic carcinomas are considered Stage IV

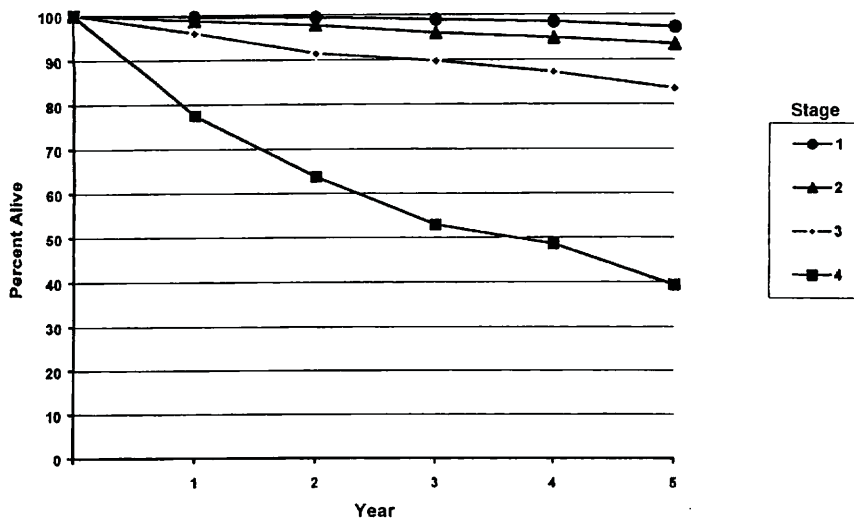
Stage IVA	T4a	Any N	M0
Stage IVB	T4b	Any N	M0
Stage IVC	Any T	Any N	M1

**HISTOPATHOLOGIC TYPE**

There are four major histopathologic types:

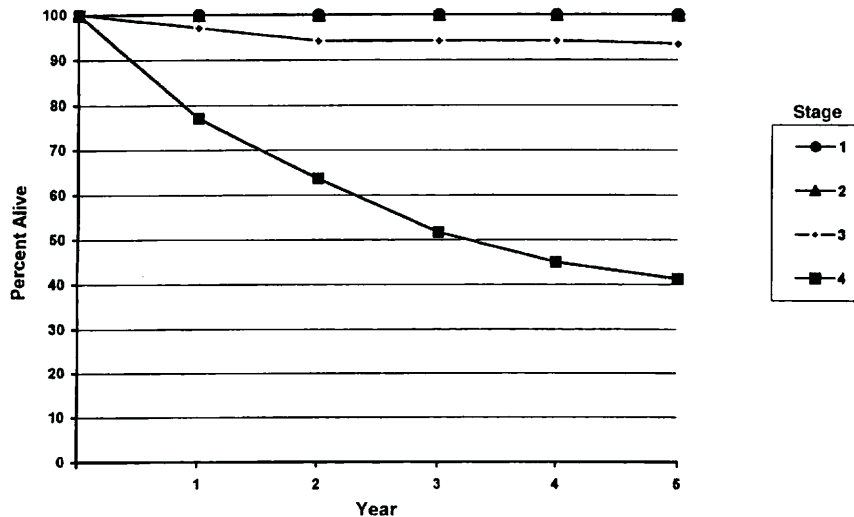
- Papillary carcinoma (including follicular variant of papillary carcinoma)
- Follicular carcinoma (including Hurthle cell carcinoma)
- Medullary carcinoma
- Undifferentiated (anaplastic) carcinoma

Figures 8.1A, 8.1B, 8.2A, 8.2B, 8.3A, 8.3B, 8.4A, 8.4B, show observed and relative survival rates for patients with papillary adenocarcinoma of the thyroid gland (8.1A,B), follicular adenocarcinoma of the thyroid gland (8.2A,B), medullary carcinoma of the thyroid gland (8.3A,B). Stage 4 anaplastic carcinoma of the thyroid gland (8.4A,B) and cancer of the thyroid gland.



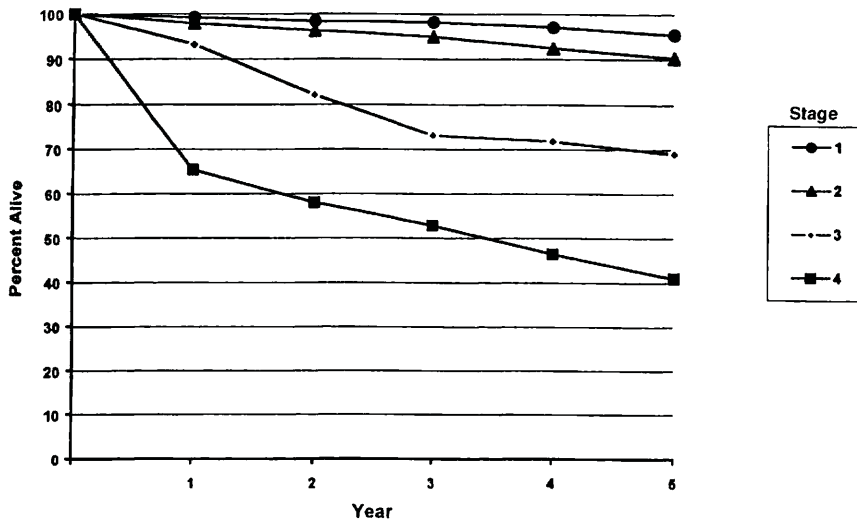
OBSERVED SURVIVAL BY STAGE	1	2	3	4	5	95% CIs*	CASES
1	99.4	98.9	98.4	97.9	97.2	96.7 – 97.7	4223
2	98.7	97.7	95.9	94.8	93.4	91.9 – 94.9	1225
3	95.9	91.4	89.7	87.2	83.5	80.9 – 86.1	928
4	77.5	63.7	52.8	48.5	39.3	31.9 – 46.7	200

**FIG. 8.1A.** Five-year, observed survival by “combined” AJCC stage for papillary adenocarcinoma of the thyroid gland, 1985–1991. (\*95% confidence intervals correspond to year-5 survival rates.)



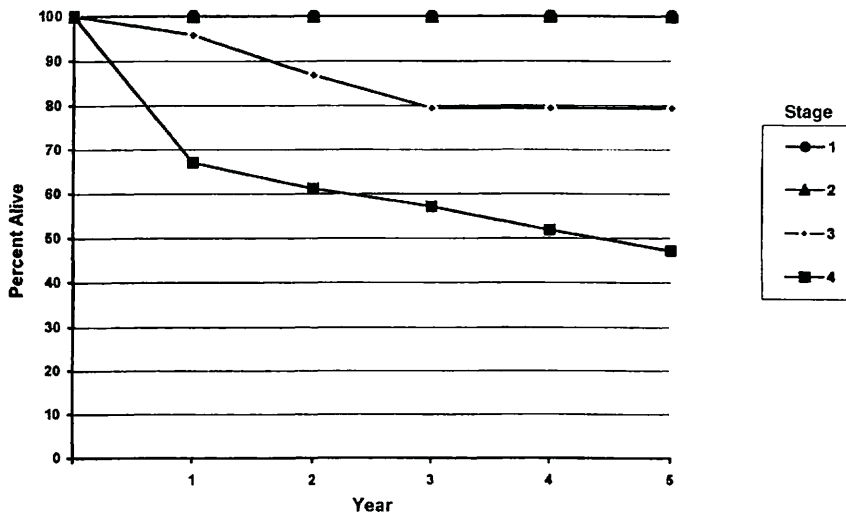
RELATIVE SURVIVAL BY STAGE	1	2	3	4	5	95% CIs*	CASES
1	100	100	100	100	100	100 – 100	4232
2	100	100	100	100	100	100 – 100	1227
3	98.1	96.2	96.2	96.2	95.8	92.8 – 98.8	930
4	78.6	66.1	57.0	53.2	45.3	36.9 – 53.8	201

**FIG. 8.1B.** Five-year, relative survival by “combined” AJCC stage for papillary adenocarcinoma of the thyroid gland, 1985–1991. (\*95% confidence intervals correspond to year-5 survival rates.)



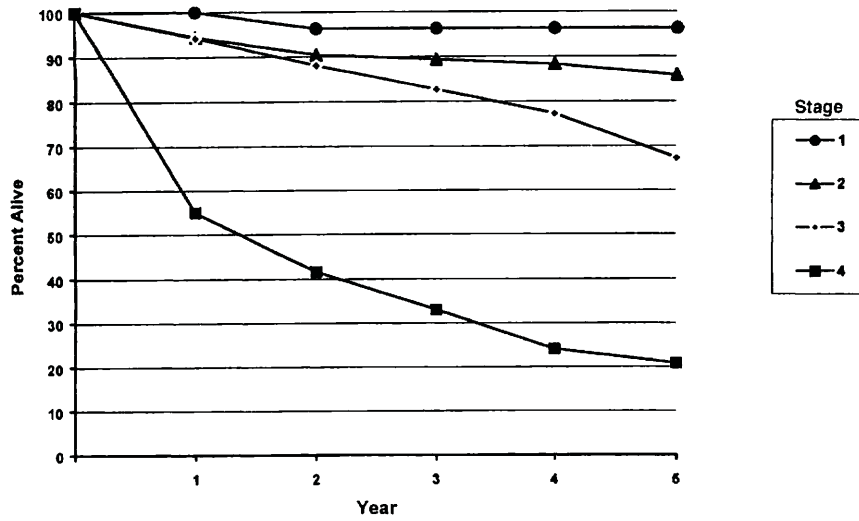
OBSERVED SURVIVAL BY STAGE	1	2	3	4	5	95% CIs*	CASES
1	99.2	98.4	98.2	97.1	95.4	93.4 – 97.3	540
2	97.9	96.2	94.9	92.7	90.3	87.1 – 93.5	394
3	93.2	82.2	73.1	71.8	69.0	58.9 – 79.2	91
4	65.4	58.0	52.8	46.4	41.0	31.2 – 50.8	104

**FIG. 8.2A.** Five-year, observed survival by “combined” AJCC stage for follicular adenocarcinoma of the thyroid gland, 1985–1991. (\*95% confidence intervals correspond to year-5 survival rates.)



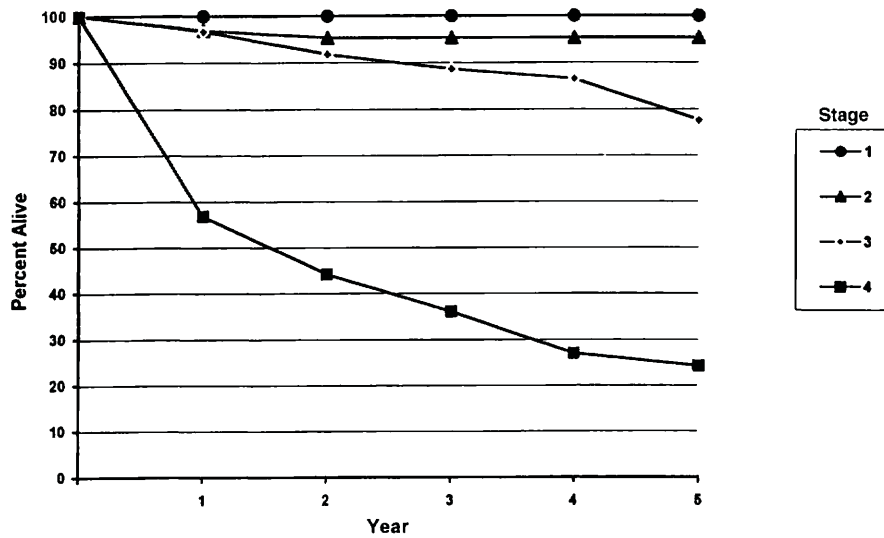
RELATIVE SURVIVAL BY STAGE	1	2	3	4	5	95% CIs*	CASES
1	100	100	100	100	100	100 – 100	540
2	100	100	100	100	100	100 – 100	395
3	95.8	86.8	79.4	79.4	79.4	67.9 – 91.2	91
4	67.1	61.1	57.1	51.8	47.1	35.8 – 58.4	104

**FIG. 8.2B.** Five-year, relative survival by “combined” AJCC stage for follicular adenocarcinoma of the thyroid gland, 1985–1991. (\*95% confidence intervals correspond to year-5 survival rates.)



OBSERVED SURVIVAL BY STAGE	1	2	3	4	5	95% CIs*	CASES
1	100	96.2	96.2	96.2	96.2	91.0 - 100	55
2	94.4	90.4	89.3	88.2	85.8	78.8 - 92.7	110
3	94.2	88.0	82.7	77.3	67.2	57.7 - 76.8	107
4	55.0	41.6	33.0	24.0	20.8	7.3 - 34.2	41

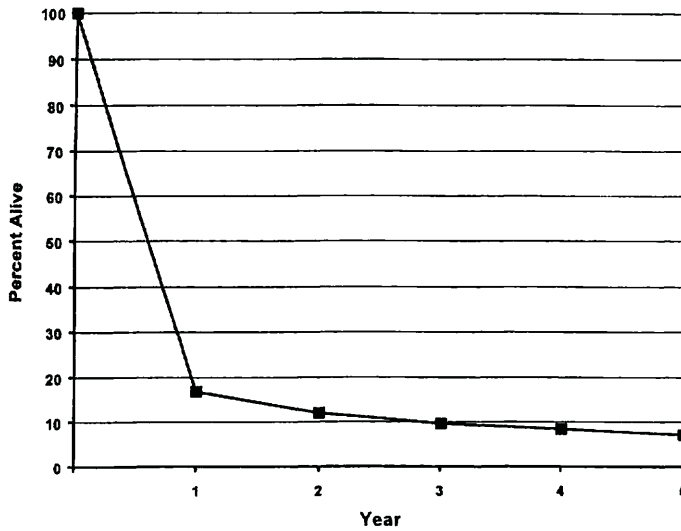
**FIG. 8.3A.** Five-year, observed survival by “combined” AJCC stage for medullary carcinoma of the thyroid gland, 1985–1991. (\*95% confidence intervals correspond to year-5 survival rates.)



RELATIVE SURVIVAL BY STAGE	1	2	3	4	5	95% CIs*	CASES
1	100	100	100	100	100	100 - 100	57
2	96.9	95.3	96.8	96.8	96.8	90.3 - 100	110
3	96.7	91.8	88.6	86.5	77.6	66.7 - 88.4	107
4	56.9	44.2	36.1	27.0	24.3	8.83 - 39.9	41

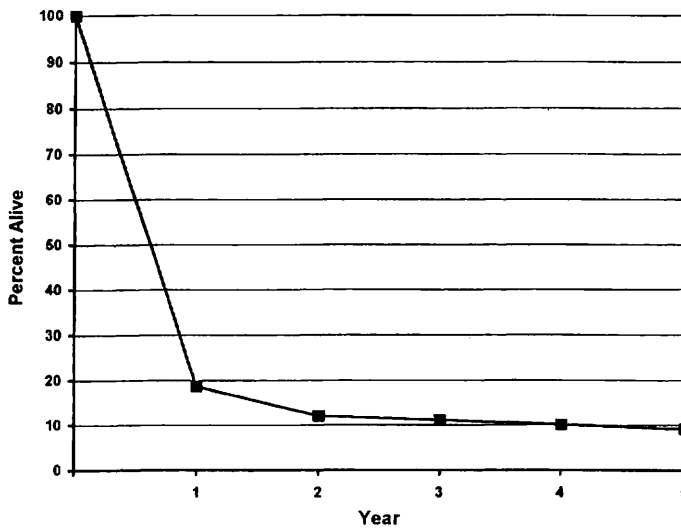
**FIG. 8.3B.** Five-year, relative survival by “combined” AJCC stage for medullary carcinoma of the thyroid gland, 1985–1991. (\*95% confidence intervals correspond to year-5 survival rates.)





OBSERVED SURVIVAL FOR STAGE 4	1	2	3	4	5	95% CIs*	CASES
4	17.8	13.0	10.7	9.5	8.2	2.4 - 14.0	91

**FIG. 8.4A.** Five-year, observed survival by “combined” AJCC stage for Stage 4 anaplastic carcinoma of the thyroid gland, 1985–1991. (\*95% confidence intervals correspond to year-5 survival rates.)



RELATIVE SURVIVAL FOR STAGE 4	1	2	3	4	5	95% CIs*	CASES
4	18.6	12.0	11.1	10.1	9.1	2.64 - 15.6	94

**FIG. 8.4B.** Five-year, relative survival by “combined” AJCC stage for Stage 4 anaplastic carcinoma of the thyroid gland, 1985–1991. (\*95% confidence intervals correspond to year-5 survival rates.)

## BIBLIOGRAPHY

- Ain KB: Papillary thyroid carcinoma: etiology, assessment, and therapy. *Endocrinol Metab Clin North Am* 24:711-760, 1995
- Andersen PE, Kinsella J, Loree TR, Shaha AR, Shah JP: Differentiated carcinoma of the thyroid with extrathyroid extension—risks for failure and patterns of recurrence. *Am J Surg* 170:467-470, 1995
- Antonacci A, Brierley G, Bacchi F, Consorti C, et al: Thyroid cancer. In Hermanek P, Gospodarowicz MK, Henson DE, et al (Eds.): *Prognostic factors in cancer*. Berlin: Springer-Verlag 28-36, 1995
- Brierley JD, Panzarella T, Tsang RW, et al: Comparing staging classifications using thyroid cancer as an example. *Cancer* 79:2414-2413, 1997
- Brierley J, Tsang R, Simpson WJ, et al: Medullary thyroid cancer—analyses of survival and prognostic factors and the role of radiation therapy in local control. *Thyroid* 6:305-310, 1996
- Cady B, Rossi R, Silverman M, et al: Further evidence of the validity of risk group definition in differentiated thyroid carcinoma. *Surgery* 98:1171-1178, 1985
- Cohn K, Blackdahl M, Forsslund G, et al: Prognostic value of nuclear DNA content in papillary thyroid carcinoma. *World J Surg* 8:474-480, 1984
- Hay ID, Grant CS, Taylor WF, et al: Ipsilateral lobectomy versus bilateral lobar resection in papillary thyroid carcinoma: a retrospective analysis of surgical outcome using a novel prognostic scoring system. *Surgery* 102:1088-1095, 1987
- Hedinger C. *Histological typing of thyroid tumours: WHO international histological classification of tumours*, 2nd ed. Berlin-Heidelberg-New York: Springer-Verlag, 1988
- Hundahl SA, Cady B, Cunningham MP, Mazzaferri E, McKee R, Rosai J, Shah JP, Fremgen AM, Stewart AK, Holzer S (United States and German Thyroid Cancer Study Group): Initial results from a prospective cohort of 5,583 cases of thyroid carcinoma treated in the United States during 1996. *Cancer* 89:202-217, 2000
- LiVolsi VA. *Surgical pathology of the thyroid*. Philadelphia: WB Saunders, 1990
- Mazzaferri EL, Jhiang S: Long-term impact of initial surgical and medical therapy on papillary and follicular thyroid cancer. *Am J Med* 97:418-428, 1994
- McConahey WM, Hay ID, Woolner LB, et al: Papillary thyroid cancer treated at the Mayo Clinic 1946-1970: initial manifestations, pathological findings, therapy and outcome. *Mayo Clinic Proc* 61:978-996, 1986
- Rosai J, Carcangiu L, DeLellis RA: *Tumors of the thyroid gland*, 3rd series. Washington, DC: Armed Forces Institute of Pathology, 1992
- Rossi R: Prognosis of undifferentiated carcinoma and lymphoma of the thyroid. *Am J Surg* 135:589-596, 1978
- Saad MF, Ordonez NG, Rashid RK, et al: Medullary carcinoma of the thyroid: a study of the clinical features and prognostic factors in 161 patients. *Medicine* 63:319-342, 1984
- Shah JP, Loree TR, Dharker D, et al: Prognostic factors in differentiated carcinoma of the thyroid gland. *Am J Surg* 164:658-661, 1992
- Shaha AR, Loree TR, Shah JP: Prognostic factors and risk group analysis in follicular carcinoma of the thyroid. *Surgery* 118:1131-1138, 1995
- Shaha AR, Shah JP, Loree TR: Risk group stratification and prognostic factors in papillary carcinoma of the thyroid. *Ann Surg Onc* 3:534-538, 1996
- Simpson WL, Panzarella T, Carruthers JS, et al: Papillary and follicular thyroid cancer: impact of treatment in 1,578 patients. *Int J Radiation Oncol Biol Phys* 14:1063-1075, 1988
- Young RL, Mazzaferri EL, Raheja J, et al: Pure follicular thyroid carcinoma: impact of therapy in 214 patients. *J Nucl Med* 21:733-737, 1980

## HISTOLOGIES—THYROID GLAND

- |        |  |
|--------|--|
| 8020/3 | Carcinoma, undifferentiated, NOS               |
| 8021/3 | Carcinoma, anaplastic, NOS                     |
| 8050/3 | Papillary carcinoma, NOS                       |
| 8051/3 | Verrucous carcinoma, NOS                       |
| 8260/3 | Papillary adenocarcinoma                       |
| 8290/3 | Hurthle cell adenocarcinoma                    |
| 8330/3 | Follicular adenocarcinoma                      |
| 8331/3 | Follicular adenocarcinoma, well differentiated |
| 8335/3 | Follicular carcinoma, minimally invasive       |
| 8337/3 | Insular carcinoma                              |
| 8340/3 | Papillary carcinoma, follicular variant        |
| 8341/3 | Papillary microcarcinoma                       |
| 8342/3 | Papillary carcinoma, oxyphilic cell            |
| 8343/3 | Papillary carcinoma, encapsulated              |
| 8344/3 | Papillary carcinoma, columnar cell             |
| 8345/3 | Medullary carcinoma with amyloid stroma        |
| 8346/3 | Mixed medullary-follicular carcinoma           |
| 8347/3 | Mixed medullary-papillary carcinoma            |
| 8430/3 | Mucoepidermoid carcinoma                       |
| 8480/3 | Mucinous adenocarcinoma                        |
| 8481/3 | Mucin-producing adenocarcinoma                 |
| 8510/3 | Medullary carcinoma, NOS                       |

## THYROID

**Hospital Name/Address**

---



---



---

**Patient Name/Information**

---



---



---

2

Type of Specimen \_\_\_\_\_  
 Tumor Size \_\_\_\_\_

Histopathologic Type \_\_\_\_\_  
 Laterality:     Bilateral     Left     Right

### DEFINITIONS

Clinical	Pathologic	Primary Tumor (T)	
<input type="checkbox"/>	<input type="checkbox"/>	TX	Primary tumor cannot be assessed
<input type="checkbox"/>	<input type="checkbox"/>	T0	No evidence of primary tumor
<input type="checkbox"/>	<input type="checkbox"/>	T1	Tumor 2 cm or less in greatest dimension limited to the thyroid
<input type="checkbox"/>	<input type="checkbox"/>	T2	Tumor more than 2 cm but not more than 4 cm in greatest dimension limited to the thyroid
<input type="checkbox"/>	<input type="checkbox"/>	T3	Tumor more than 4 cm in greatest dimension limited to the thyroid or any tumor with minimal extrathyroid extension (e.g., extension to sternothyroid muscle or perithyroid soft tissues)
<input type="checkbox"/>	<input type="checkbox"/>	T4a	Tumor of any size extending beyond the thyroid capsule to invade subcutaneous soft tissues, larynx, trachea, esophagus, or recurrent laryngeal nerve
<input type="checkbox"/>	<input type="checkbox"/>	T4b	Tumor invades prevertebral fascia or encases carotid artery or mediastinal vessels
<i>All anaplastic carcinomas are considered T4 tumors.</i>			
<input type="checkbox"/>	<input type="checkbox"/>	T4a	Intrathyroidal anaplastic carcinoma – surgically resectable
<input type="checkbox"/>	<input type="checkbox"/>	T4b	Extrathyroidal anaplastic carcinoma – surgically unresectable

**Notes**

1. All categories may be subdivided: (a) solitary tumor, (b) multifocal tumor (the largest determines the classification)

### Regional Lymph Nodes (N)

*Regional lymph nodes are the central compartment, lateral cervical, and upper mediastinal lymph nodes.*

<input type="checkbox"/>	<input type="checkbox"/>	NX	Regional lymph nodes cannot be assessed
<input type="checkbox"/>	<input type="checkbox"/>	N0	No regional lymph node metastasis
<input type="checkbox"/>	<input type="checkbox"/>	N1	Regional lymph node metastasis
<input type="checkbox"/>	<input type="checkbox"/>	N1a	Metastasis to Level VI (pretracheal, paratracheal, and prelaryngeal/Delphian lymph nodes)
<input type="checkbox"/>	<input type="checkbox"/>	N1b	Metastasis to unilateral, bilateral, or contralateral cervical or superior mediastinal lymph nodes

### Distant Metastasis (M)

<input type="checkbox"/>	<input type="checkbox"/>	MX	Distant metastasis cannot be assessed
<input type="checkbox"/>	<input type="checkbox"/>	M0	No distant metastasis
<input type="checkbox"/>	<input type="checkbox"/>	M1	Distant metastasis
Biopsy of metastatic site performed .... <input type="checkbox"/> Y..... <input type="checkbox"/> N			
Source of pathologic metastatic specimen _____			

*(continued on reverse side)*

**Stage Grouping**

Separate stage groupings are recommended for papillary or follicular, medullary, and anaplastic (undifferentiated) carcinoma.

**Papillary or Follicular**

Clinical	Pathologic				
<input type="checkbox"/>	<input type="checkbox"/>	I	Any T	Any N	M0
<input type="checkbox"/>	<input type="checkbox"/>	II	Any T	Any N	M1

**Papillary or Follicular**

45 years and older

Clinical	Pathologic				
<input type="checkbox"/>	<input type="checkbox"/>	I	T1	N0	M0
<input type="checkbox"/>	<input type="checkbox"/>	II	T2	N0	M0
<input type="checkbox"/>	<input type="checkbox"/>	III	T3	N0	M0
<input type="checkbox"/>	<input type="checkbox"/>	IVA	T1	N1a	M0
<input type="checkbox"/>	<input type="checkbox"/>		T2	N1a	M0
<input type="checkbox"/>	<input type="checkbox"/>		T3	N1a	M0
<input type="checkbox"/>	<input type="checkbox"/>		T4a	N0	M0
<input type="checkbox"/>	<input type="checkbox"/>		T4a	N1a	M0
<input type="checkbox"/>	<input type="checkbox"/>		T1	N1b	M0
<input type="checkbox"/>	<input type="checkbox"/>		T2	N1b	M0
<input type="checkbox"/>	<input type="checkbox"/>	T3	N1b	M0	
<input type="checkbox"/>	<input type="checkbox"/>	T4a	N1b	M0	
<input type="checkbox"/>	<input type="checkbox"/>	IVB	T4b	Any N	M0
<input type="checkbox"/>	<input type="checkbox"/>	IVC	Any T	Any N	M1

Clinical	Pathologic					
<input type="checkbox"/>	<input type="checkbox"/>	I	T1	N0	M0	
<input type="checkbox"/>	<input type="checkbox"/>		T2	N0	M0	
<input type="checkbox"/>	<input type="checkbox"/>		T3	N0	M0	
<input type="checkbox"/>	<input type="checkbox"/>	III	T1	N1a	M0	
<input type="checkbox"/>	<input type="checkbox"/>		T2	N1a	M0	
<input type="checkbox"/>	<input type="checkbox"/>		T3	N1a	M0	
<input type="checkbox"/>	<input type="checkbox"/>		IVA	T4a	N0	M0
<input type="checkbox"/>	<input type="checkbox"/>			T4a	N1a	M0
<input type="checkbox"/>	<input type="checkbox"/>			T1	N1b	M0
<input type="checkbox"/>	<input type="checkbox"/>			T2	N1b	M0
<input type="checkbox"/>	<input type="checkbox"/>	T3	N1b	M0		
<input type="checkbox"/>	<input type="checkbox"/>	T4a	N1b	M0		
<input type="checkbox"/>	<input type="checkbox"/>	IVB	T4b	Any N	M0	
<input type="checkbox"/>	<input type="checkbox"/>	IVC	Any T	Any N	M1	

**Anaplastic Carcinoma**

<input type="checkbox"/>	<input type="checkbox"/>	IVA	T4a	Any N	M0
<input type="checkbox"/>	<input type="checkbox"/>	IVB	T4b	Any N	M0
<input type="checkbox"/>	<input type="checkbox"/>	IVC	Any T	Any N	M1

**Residual Tumor (R)**

- RX Presence of residual tumor cannot be assessed
- R0 No residual tumor
- R1 Microscopic residual tumor
- R2 Macroscopic residual tumor

**Additional Descriptors**

For identification of special cases of TNM or pTNM classifications, the "m" suffix and "y," "r," and "a" prefixes are used. Although they do not affect the stage grouping, they indicate cases needing separate analysis.

- m suffix** indicates the presence of multiple primary tumors in a single site and is recorded in parentheses: pT(m)NM.
- y prefix** indicates those cases in which classification is performed during or following initial multimodality therapy. The cTNM or pTNM category is identified by a "y" prefix. The ycTNM or ypTNM categorizes the extent of tumor actually present at the time of that examination. The "y" categorization is not an estimate of tumor prior to multimodality therapy.
- r prefix** indicates a recurrent tumor when staged after a disease-free interval, and is identified by the "r" prefix: rTNM.
- a prefix** designates the stage determined at autopsy: aTNM.

**Prognostic Indicators (if applicable)**

**Notes**

**Additional Descriptors**

**Lymphatic Vessel Invasion (L)**

- LX Lymphatic vessel invasion cannot be assessed
- L0 No lymphatic vessel invasion
- L1 Lymphatic vessel invasion

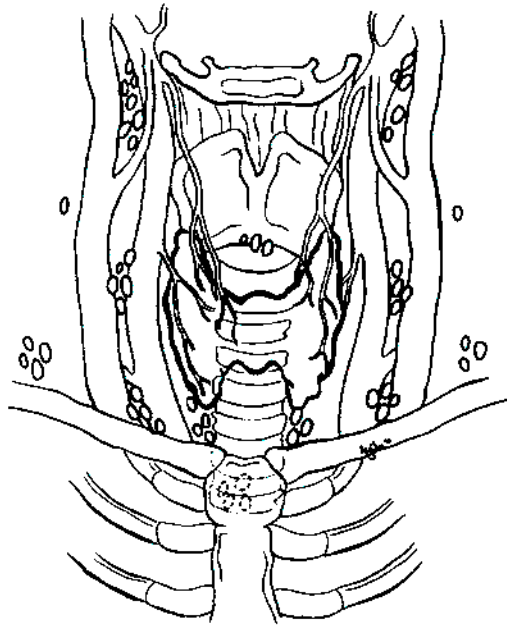
**Venous Invasion (V)**

- VX Venous invasion cannot be assessed
- V0 No venous invasion
- V1 Microscopic venous invasion
- V2 Macroscopic venous invasion

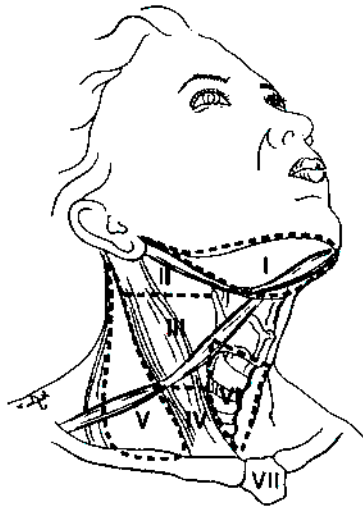
**ILLUSTRATION**

Indicate on diagram primary tumor and regional nodes involved.

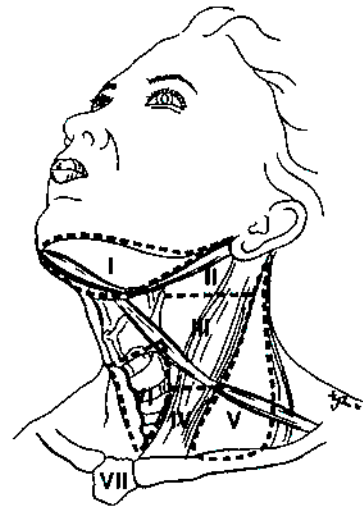
1.



2.



3.



2

Physician's Signature \_\_\_\_\_

Date \_\_\_\_\_



# **PART III**

## **Digestive System**

# Esophagus

(Sarcomas are not included.)

C15.0 Cervical esophagus  
C15.1 Thoracic esophagus  
C15.2 Abdominal esophagus

C15.3 Upper third of esophagus  
C15.4 Middle third of esophagus  
C15.5 Lower third of esophagus

C15.8 Overlapping lesion of esophagus  
C15.9 Esophagus, NOS

## SUMMARY OF CHANGES

- The definition of TNM and the Stage Grouping for this chapter have not changed from the Fifth Edition.

## INTRODUCTION

Occurring more often in males, cancer of the esophagus accounts for 5.5% of all malignant tumors of the gastrointestinal tract and for less than 1% of all cancers in the United States. However, during the past 20 years, there has been a dramatic shift in the epidemiology of esophageal cancer in North America and most Western countries, characterized by a very rapid rise in the incidence of this disease and a marked shift from squamous cell carcinomas occurring predominantly in the middle third and distal esophagus to adenocarcinomas arising in the distal esophagus and the esophagogastric (EG) junction. Predisposing factors for squamous cell carcinomas include a high alcohol intake and heavy use of tobacco or nutritional deficiencies of vitamins and minerals. In contrast, EG junction carcinomas arise most frequently in Barrett's epithelium. The underlying causes for this marked epidemiologic change remain undefined.

Esophageal cancers, regardless of histologic type, may extend over wide areas of the mucosal surface. Squamous cell carcinomas often arise as multifocal tumors, presumably as a result of field carcinogenesis. Adenocarcinomas may have varying lengths of mucosal and submucosal disease, particularly in patients with long segments of Barrett's mucosa. However, only the depth of penetration into the esophageal wall and nodal status are considered in staging.

Many patients are asymptomatic during the early stages of disease. Early symptoms include those related to gastroesophageal reflux and associated Barrett's esophagus or odynophagia caused by esophageal ulceration. Unfortunately, the most common clinical symptom for all lesions is dysphagia, which occurs with large tumors that obstruct the lumen and deeply invade the esophageal wall. Therefore, most patients already have locally advanced or metastatic disease at diagnosis.

## ANATOMY

**Primary Site.** Beginning at the hypopharynx, the esophagus lies posterior to the trachea and the heart, passing through the posterior mediastinum and entering the stomach through an opening in the diaphragm called the hiatus.

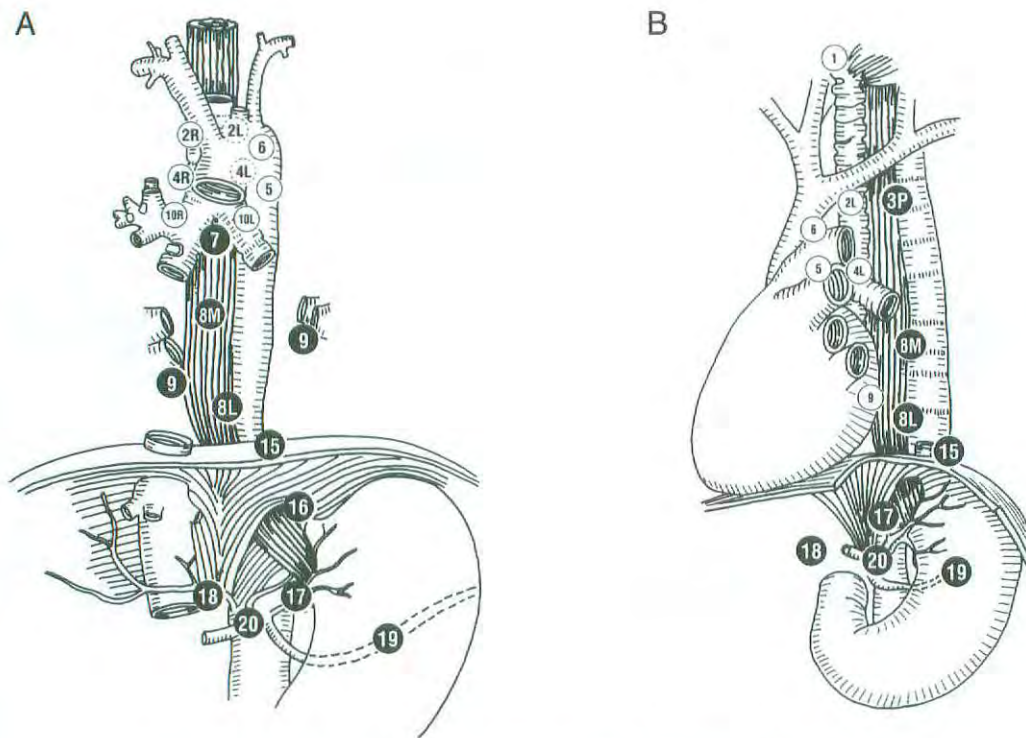
Histologically, the esophagus has four layers: mucosa, submucosa, muscle coat or muscularis propria, and adventitia. There is no serosa.

For classification, staging, and reporting of cancer, the esophagus is divided into four regions. Because the behavior of esophageal cancer and its treatment vary with the anatomic divisions, these regions should be recorded and reported separately. The location of the esophageal cancer at the time of endoscopy is often measured from the incisors (front teeth).

*Cervical esophagus.* The cervical esophagus begins at the level of the lower border of the cricoid cartilage and ends at the thoracic inlet (the suprasternal notch), approximately 18 cm from the upper incisor teeth.

*Intrathoracic and abdominal esophagus.* This region is divided into two portions: The *upper thoracic portion* extends from the thoracic inlet to the level of the tracheal bifurcation, approximately 24 cm from the upper incisor teeth. The *mid-thoracic portion* of the esophagus lies between the tracheal bifurcation and the distal esophagus just above the esophagogastric junction. The lower level of this portion is approximately 32 cm from the upper incisor teeth.

*Lower thoracic and abdominal portion.* Approximately 3 cm in length, the lower esophagus also includes the intra-abdominal portion of the esophagus and the EG junction, which is located approximately 40 cm from the upper incisor teeth. Most adenocarcinomas arise from the EG junction and involve both the distal esophagus and the proximal stomach. Controversy exists over how to distinguish proximal gastric



Regional lymph node stations for staging esophageal cancer, from front (A) and side (B).

1	Supraclavicular nodes	Above suprasternal notch and clavicles
2R	Right upper paratracheal nodes	Between intersection of caudal margin of innominate artery with trachea and the apex of the lung
2L	Left upper paratracheal nodes	Between top of aortic arch and apex of the lung
● 3P	Posterior mediastinal nodes	Upper paraesophageal nodes, above tracheal bifurcation
4R	Right lower paratracheal nodes	Between intersection of caudal margin of innominate artery with trachea and cephalic border of azygous vein
4L	Left lower paratracheal nodes	Between top of aortic arch and carina
5	Aortopulmonary nodes	Subaortic and para-aortic nodes lateral to the ligamentum arteriosum
6	Anterior mediastinal nodes	Anterior to ascending aorta or innominate artery
● 7	Subcarinal nodes	Caudal to the carina of the trachea
● 8M	Middle paraesophageal lymph nodes	From the tracheal bifurcation to the caudal margin of the inferior pulmonary vein
● 8L	Lower paraesophageal lymph nodes	From the caudal margin of the inferior pulmonary vein to the esophagogastric junction
● 9	Pulmonary ligament nodes	Within the inferior pulmonary ligament
10R	Right tracheobronchial nodes	From cephalic border of azygous vein to origin of RUL bronchus
10L	Left tracheobronchial nodes	Between carina and LUL bronchus
● 15	Diaphragmatic nodes	Lying on the dome of the diaphragm, and adjacent to or behind its crura
● 16	Paracardial nodes	Immediately adjacent to the gastroesophageal junction
● 17	Left gastric nodes	Along the course of the left gastric artery
● 18	Common hepatic nodes	Along the course of the common hepatic artery
● 19	Splenic nodes	Along the course of the splenic artery
● 20	Celiac nodes	At the base of the celiac artery

**FIG. 9.1.** Esophageal lymph node map indicating regional lymph node stations for staging esophageal cancer, from front (A) and side (B). (Reproduced with permission from Bristol-Myers Oncology Division.)



cancers involving the EG junction from distal esophageal and EG junction cancers extending inferiorly to involve the gastric cardia. In the absence of underlying Barrett's mucosa, making this distinction can be difficult. Siewert has proposed classifying EG junction cancers into types I, II and III depending on the relative extent of involvement of either the esophagus or the stomach. Further validation of this classification is needed to determine whether it is reliable for staging or for prognosis. In clinical practice, tumors arising within the EG junction and gastric cardia that have minimal (2 cm or less) involvement of the esophagus are considered primary gastric cancers.

**Regional Lymph Nodes.** Specific regional lymph nodes are listed as follows:

- Cervical esophagus
  - Scalene
  - Internal jugular
  - Upper and lower cervical
  - Periesophageal
  - Supraclavicular
- Intrathoracic esophagus—upper, middle, and lower
  - Upper periesophageal (above the azygous vein)
  - Subcarinal
  - Lower periesophageal (below the azygous vein)
- Gastroesophageal junction
  - Lower esophageal (below the azygous vein)
  - Diaphragmatic
  - Pericardial
  - Left gastric
  - Celiac

Involvement of more distant lymph nodes (such as cervical or celiac axis nodes for intrathoracic tumors) is currently considered distant metastasis (M1a). However, recent analyses suggest that extensive nodal disease is associated with a better overall survival than visceral metastases and with an approximately 10% chance of cure at 5 years after surgical resection. On this basis, it has been suggested that the involvement of distant lymph nodes be classified as N2 disease rather than M1a, but such a change in classification requires further study.

The nomenclature used to indicate the location of involved lymph nodes has most frequently been that shown above, which provides a general anatomical description. More recently, a lymph node map that extends the nomenclature and numbering system used for the staging of non-small cell lung cancer has been developed and used in clinical trials. This map, which is shown in Figure 9.1, makes possible the more precise identification of involved lymph nodes.

**Metastatic Sites.** The liver, lungs, and pleura are the most common sites of distant metastases. Occasionally, the tumor may extend directly into mediastinal structures before distant metastasis is evident. This occurs most frequently

with tumors of the intrathoracic esophagus, which may extend directly into the aorta, trachea, and pericardium.

## RULES FOR CLASSIFICATION

**Clinical Staging.** Clinical staging depends on the anatomic extent of the primary tumor, which can be ascertained by examination before treatment. Such an examination includes some combination of medical history, physical examination, routine laboratory studies, esophagogastroscope with biopsy, esophageal ultrasound (EUS), computed tomography (CT), and positron emission tomography (PET). EUS is considered the most accurate way to identify the depth of tumor invasion and may also reveal regional lymph node metastases. CT is more useful in identifying distant metastatic disease. Although the experience with PET is still limited, it appears to be more sensitive than CT in detecting distant metastases. The combined use of EUS, CT, and PET may prove to be the most accurate non-invasive means of staging esophageal carcinomas.

The anatomic location of the primary tumor (cervical, upper thoracic, midthoracic, or lower thoracic or gastroesophageal junction) should be recorded.

**Pathologic Staging.** Pathologic staging is based on surgical exploration and on the examination of the surgically resected esophagus and associated lymph nodes. Involvement of the adjacent structures depends on the location of the primary tumor. This extension and the presence of distant metastases should be specifically documented. A single classification serves all regions of the esophagus and the EG junction. It also serves both clinical and pathologic staging.

## DEFINITION OF TNM

### Primary Tumor (T)

- TX Primary tumor cannot be assessed
- T0 No evidence of primary tumor
- Tis Carcinoma *in situ*
- T1 Tumor invades lamina propria or submucosa
- T2 Tumor invades muscularis propria
- T3 Tumor invades adventitia
- T4 Tumor invades adjacent structures

### Regional Lymph Nodes (N)

- NX Regional lymph nodes cannot be assessed
- N0 No regional lymph node metastasis
- N1 Regional lymph node metastasis

### Distant Metastasis (M)

- MX Distant metastasis cannot be assessed
- M0 No distant metastasis
- M1 Distant metastasis

Tumors of the lower thoracic esophagus:

M1a Metastasis in celiac lymph nodes

M1b Other distant metastasis

Tumors of the midthoracic esophagus:

M1a Not applicable

M1b Nonregional lymph nodes and/or other distant metastasis

Tumors of the upper thoracic esophagus:

M1a Metastasis in cervical nodes

M1b Other distant metastasis

#### STAGE GROUPING

Stage 0	Tis	N0	M0
Stage I	T1	N0	M0
Stage IIA	T2	N0	M0
	T3	N0	M0
Stage IIB	T1	N1	M0
	T2	N1	M0
Stage III	T3	N1	M0
	T4	Any N	M0
Stage IV	Any T	Any N	M1
Stage IVA	Any T	Any N	M1a
Stage IVB	Any T	Any N	M1b

#### HISTOPATHOLOGIC TYPE

The classification applies to all carcinomas. Sarcomas are not included. Worldwide, squamous cell carcinomas are the most common, but the incidence of adenocarcinoma is increasing. In North America and Europe, adenocarcinomas are more common than squamous cell carcinomas. Adenocarcinomas arising from Barrett's esophagus are included in the classification.

Barrett's esophagus (Barrett's mucosa) is a columnar metaplasia of the esophagus that is due to chronic gastroesophageal reflux. It is the only known precursor of esophageal adenocarcinoma, although the risk of Barrett's cancer varies greatly from one study to another. The diagnosis of Barrett's mucosa is made when two criteria are satisfied. First, there must be endoscopic or grossly abnormal columnar mucosa involving the distal esophagus, usually identified as tongues of pink mucosa extending above the normal squamocolumnar junction. This junction is the normal border between esophageal and gastric mucosa. Usually this junction coincides with the anatomic gastroesophageal junction, but sometimes it actually lies within the distal 2 cm of the tubular esophagus. Second, biopsies of the abnormal endoscopic areas must contain goblet cells in the columnar mucosa. Barrett's mucosa has been divided into two types based on length: short-segment disease that is less than 3 cm and long-segment disease that is 3 cm or longer. If all patients with short-segment and long-segment disease are compared, there is no significant difference in cancer risk, although there may

be a gradual increase in risk with increasing length. The precursor lesion for carcinoma and the marker of very high cancer risk is high-grade dysplasia in the Barrett's mucosa. High-grade dysplasia includes all non-invasive neoplastic epithelium that was formally called carcinoma *in situ*, a diagnosis that is no longer used for columnar mucosae anywhere in the gastrointestinal tract.

#### HISTOLOGIC GRADE (G)

GX Grade cannot be assessed

G1 Well differentiated

G2 Moderately differentiated

G3 Poorly differentiated

G4 Undifferentiated

#### PROGNOSTIC FACTORS

Anatomic location does not appear to be an important prognostic variable. However, upper thoracic and cervical esophageal lesions may be more difficult to manage surgically than more inferiorly located tumors because of their proximity to vital structures, including the trachea and great vessels. Depth of invasion (T) is an independent variable; tumor length is not. This has encouraged pretreatment endoscopic ultrasound for staging, particularly in patients who may be candidates for non-operative therapy. Lymphatic spread is a strong independent prognostic variable, as are distant metastases. In the latter category, distant organ metastasis appears to be associated with a worse prognosis than distant non-regional lymph node metastases. The histologic type (squamous cell carcinoma versus adenocarcinoma) is not a prognostic factor. Tumor differentiation, DNA ploidy status, and various oncogenes, growth factors, and other markers are being intensively studied as prognostic indicators, but data are still insufficient for a conclusive statement regarding these potential prognostic factors.

#### BIBLIOGRAPHY

- Block MI, Patterson GA, Sundaresan RS, et al: Improvement in staging of esophageal cancer with the addition of positron emission tomography. *Ann Thorac Surg* 64:770-777, 1997
- Casson AG, Rusch VW, Ginsberg RJ, Zankowicz N, Finley RJ: Lymph node mapping of esophageal cancer. *Ann Thorac Surg* 58:1569-1570, 1994
- Ellis FH Jr, Heatley GJ, Krasna MJ, Williamson WA, Balogh K: Esophagogastrectomy for carcinoma of the esophagus and cardia: a comparison of findings and results after standard resection in three consecutive eight-year intervals with improved staging criteria. *J Thorac Cardiovasc Surg* 113:836-848, 1997
- Kawahara K, Maekawa T, Okabayashi K, et al: The number of lymph node metastases influences survival in esophageal cancer. *J Surg Oncol* 67:160-163, 1998

- Kelsen DP, Ginsberg R, Pajak TF, et al: Chemotherapy followed by surgery compared with surgery alone for localized esophageal cancer. *N Engl J Med* 339:1979–1984, 1998
- Killinger WA, Jr., Rice TW, Adelstein DJ, et al: Stage II esophageal carcinoma: the significance of T and N. *J Thorac Cardiovasc Surg* 111:935–940, 1996
- Lightdale CJ: Positron emission tomography: another useful test for staging esophageal cancer. *J Clin Oncol* 18:3199–3201, 2000
- Nishimaki T, Tanaka O, Ando N, et al: Evaluation of the accuracy of preoperative staging in thoracic esophageal cancer. *Ann Thorac Surg* 68:2059–2064, 1999
- Pera M, Cameron AJ, Trastek VF, Carpenter HA, Zinsmeister AR: Increasing incidence of adenocarcinoma of the esophagus and esophagogastric junction. *Gastroenterol* 104:510–513, 1993
- Rudolph RE, Vaughan TL, Storer BE, et al: Effect of segment length on risk for neoplastic progression in patients with Barrett esophagus. *Ann Int Med* 132:612–620, 2000
- Rusch VW, Levine DS, Haggitt R, Reid BJ: The management of high grade dysplasia and early cancer in Barrett's esophagus. *Cancer* 74:1225–1229, 1994
- Sabik JF, Rice TW, Goldblum JR, et al: Superficial esophageal carcinoma. *Ann Thorac Surg* 60:896–902, 1995
- Sampliner RE: Practice guidelines on the diagnosis, surveillance, and therapy of Barrett's esophagus: the Practice Parameters Committee of the American College of Gastroenterology. *Am J Gastroenterol* 93:1028–1032, 1998
- Siewert JR, Feith M, Werner M, Stein HJ: Adenocarcinoma of the esophagogastric junction: results of surgical therapy based on anatomical/topographic classification in 1,002 consecutive patients. *Trans Am Surg Assoc* 118:67–75, 2000
- Steup WH, De Leyn P, Deneffe G, Van Raemdonck D, Coosemans W, Lerut T: Tumors of the esophagogastric junction. Long term survival in relation to the pattern of lymph node metastasis and a critical analysis of the accuracy or inaccuracy of pTNM classification. *J Thorac Cardiovasc Surg* 111:85–95, 1996
- Yang PC, Davis S: Incidence of cancer of the esophagus in the U.S. by histologic type. *Cancer* 61:612–617, 1988
- 8033/3 Pseudosarcomatous carcinoma
- 8034/3 Polygonal cell carcinoma
- 8035/3 Carcinoma with osteoclast-like giant cells
- 8041/3 Small cell carcinoma, NOS
- 8042/3 Oat cell carcinoma
- 8043/3 Small cell carcinoma, fusiform cell
- 8044/3 Small cell carcinoma, intermediate cell
- 8045/3 Combined small cell carcinoma
- 8046/3 Non-small cell carcinoma
- 8050/3 Papillary carcinoma, NOS
- 8051/3 Verrucous carcinoma, NOS
- 8052/2 Papillary squamous cell carcinoma, non-invasive
- 8052/3 Papillary squamous cell carcinoma
- 8070/2 Squamous cell carcinoma *in situ*, NOS
- 8070/3 Squamous cell carcinoma, NOS
- 8071/3 Squamous cell carcinoma, keratinizing, NOS
- 8072/3 Squamous cell carcinoma, large cell, nonkeratinizing, NOS
- 8073/3 Squamous cell carcinoma, small cell, nonkeratinizing
- 8074/3 Squamous cell carcinoma, spindle cell
- 8075/3 Squamous cell carcinoma, adenoid
- 8076/2 Squamous cell carcinoma *in situ* with questionable stromal invasion
- 8076/3 Squamous cell carcinoma, microinvasive
- 8077/2 Squamous intraepithelial neoplasia, grade III
- 8082/3 Lymphoepithelial carcinoma
- 8083/3 Basaloid squamous cell carcinoma
- 8084/3 Squamous cell carcinoma, clear cell type
- 8090/3 Basal cell carcinoma, NOS
- 8091/3 Multifocal superficial basal cell carcinoma
- 8092/3 Infiltrating basal cell carcinoma, NOS
- 8093/3 Basal cell carcinoma, fibroepithelial
- 8094/3 Basosquamous carcinoma
- 8095/3 Metatypical carcinoma
- 8097/3 Basal cell carcinoma, nodular
- 8098/3 Adenoid basal carcinoma
- 8244/3 Composite carcinoid
- 8245/3 Adenocarcinoid tumor
- 8246/3 Neuroendocrine carcinoma, NOS
- 8247/3 Merkel cell carcinoma
- 8249/3 Atypical carcinoid tumor
- 8255/3 Adenocarcinoma with mixed subtypes
- 8260/3 Papillary adenocarcinoma, NOS
- 8430/3 Mucoepidermoid carcinoma
- 8440/3 Cystadenocarcinoma, NOS
- 8480/3 Mucinous adenocarcinoma
- 8481/3 Mucin-producing adenocarcinoma
- 8490/3 Signet ring cell carcinoma
- 8510/3 Medullary carcinoma, NOS
- 8560/3 Adenosquamous carcinoma
- 8570/3 Adenocarcinoma with squamous metaplasia
- 8571/3 Adenocarcinoma with cartilaginous and osseous metaplasia
- 8572/3 Adenocarcinoma with spindle cell metaplasia
- 8573/3 Adenocarcinoma with apocrine metaplasia
- 8574/3 Adenocarcinoma with neuroendocrine differentiation
- 8575/3 Metaplastic carcinoma, NOS
- 8830/3 Malignant fibrous histiocytoma
- 8933/3 Adenosarcoma
- 8940/3 Mixed tumor, malignant, NOS
- 8941/3 Carcinoma in pleomorphic adenoma

## HISTOLOGIES—ESOPHAGUS

- 8000/3 Neoplasm, malignant
- 8001/3 Tumor cells, malignant
- 8002/3 Malignant tumor, small cell type
- 8003/3 Malignant tumor, giant cell type
- 8004/3 Malignant tumor, spindle cell type
- 8005/3 Malignant tumor, clear cell type
- 8010/2 Carcinoma *in situ*, NOS
- 8010/3 Carcinoma, NOS
- 8011/3 Epithelioma, malignant
- 8012/3 Large cell carcinoma, NOS
- 8013/3 Large cell neuroendocrine carcinoma
- 8014/3 Large cell carcinoma with rhabdoid phenotype
- 8015/3 Glassy cell carcinoma
- 8020/3 Carcinoma, undifferentiated, NOS
- 8021/3 Carcinoma, anaplastic, NOS
- 8022/3 Pleomorphic carcinoma
- 8030/3 Giant cell and spindle cell carcinoma
- 8031/3 Giant cell carcinoma
- 8032/3 Spindle cell carcinoma, NOS

## ESOPHAGUS

**Hospital Name/Address**

---



---



---

**Patient Name/Information**

---



---



---

Type of Specimen \_\_\_\_\_

Histopathologic Type \_\_\_\_\_

Tumor Size \_\_\_\_\_

3

### DEFINITIONS

<i>Clinical</i>	<i>Pathologic</i>	<b>Primary Tumor (T)</b>	
<input type="checkbox"/>	<input type="checkbox"/>	TX	Primary tumor cannot be assessed
<input type="checkbox"/>	<input type="checkbox"/>	T0	No evidence of primary tumor
<input type="checkbox"/>	<input type="checkbox"/>	Tis	Carcinoma <i>in situ</i>
<input type="checkbox"/>	<input type="checkbox"/>	T1	Tumor invades lamina propria or submucosa
<input type="checkbox"/>	<input type="checkbox"/>	T2	Tumor invades muscularis propria
<input type="checkbox"/>	<input type="checkbox"/>	T3	Tumor invades adventitia
<input type="checkbox"/>	<input type="checkbox"/>	T4	Tumor invades adjacent structures

<i>Clinical</i>	<i>Pathologic</i>	<b>Regional Lymph Nodes (N)</b>	
<input type="checkbox"/>	<input type="checkbox"/>	NX	Regional lymph nodes cannot be assessed
<input type="checkbox"/>	<input type="checkbox"/>	N0	No regional lymph node metastasis
<input type="checkbox"/>	<input type="checkbox"/>	N1	Regional lymph node metastasis

<i>Clinical</i>	<i>Pathologic</i>	<b>Distant Metastasis (M)</b>	
<input type="checkbox"/>	<input type="checkbox"/>	MX	Distant metastasis cannot be assessed
<input type="checkbox"/>	<input type="checkbox"/>	M0	No distant metastasis
<input type="checkbox"/>	<input type="checkbox"/>	M1	Distant metastasis
		<i>Tumors of the lower thoracic esophagus:</i>	
<input type="checkbox"/>	<input type="checkbox"/>	M1a	Metastasis in celiac lymph nodes
<input type="checkbox"/>	<input type="checkbox"/>	M1b	Other distant metastasis
		<i>Tumors of the midthoracic esophagus:</i>	
<input type="checkbox"/>	<input type="checkbox"/>	M1a	Not applicable
<input type="checkbox"/>	<input type="checkbox"/>	M1b	Nonregional lymph nodes and/or other distant metastasis
		<i>Tumors of the upper thoracic esophagus:</i>	
<input type="checkbox"/>	<input type="checkbox"/>	M1a	Metastasis in cervical nodes
<input type="checkbox"/>	<input type="checkbox"/>	M1b	Other distant metastasis

Biopsy of metastatic site performed ..... Y..... N

Source of pathologic metastatic specimen \_\_\_\_\_

<i>Clinical</i>	<i>Pathologic</i>	<b>Stage Grouping</b>			
<input type="checkbox"/>	<input type="checkbox"/>	0	Tis	N0	M0
<input type="checkbox"/>	<input type="checkbox"/>	I	T1	N0	M0
<input type="checkbox"/>	<input type="checkbox"/>	IIA	T2	N0	M0
			T3	N0	M0
<input type="checkbox"/>	<input type="checkbox"/>	IIB	T1	N1	M0
			T2	N1	M0
<input type="checkbox"/>	<input type="checkbox"/>	III	T3	N1	M0
			T4	Any N	M0
<input type="checkbox"/>	<input type="checkbox"/>	IV	Any T	Any N	M1
<input type="checkbox"/>	<input type="checkbox"/>	IVA	Any T	Any N	M1a
<input type="checkbox"/>	<input type="checkbox"/>	IVB	Any T	Any N	M1b

*(continued on reverse side)*

**Histologic Grade (G)**

- GX Grade cannot be assessed
- G1 Well differentiated
- G2 Moderately differentiated
- G3 Poorly differentiated
- G4 Undifferentiated

**Residual Tumor (R)**

- RX Presence of residual tumor cannot be assessed
- R0 No residual tumor
- R1 Microscopic residual tumor
- R2 Macroscopic residual tumor

**Additional Descriptors**

For identification of special cases of TNM or pTNM classifications, the "m" suffix and "y," "r," and "a" prefixes are used. Although they do not affect the stage grouping, they indicate cases needing separate analysis.

- m suffix** indicates the presence of multiple primary tumors in a single site and is recorded in parentheses: pT(m)NM.
- y prefix** indicates those cases in which classification is performed during or following initial multimodality therapy. The cTNM or pTNM category is identified by a "y" prefix. The ycTNM or ypTNM categorizes the extent of tumor actually present at the time of that examination. The "y" categorization is not an estimate of tumor prior to multimodality therapy.
- r prefix** indicates a recurrent tumor when staged after a disease-free interval, and is identified by the "r" prefix: rTNM.
- a prefix** designates the stage determined at autopsy: aTNM.

**Prognostic Indicators (if applicable)**

**Notes**

**Additional Descriptors**

**Lymphatic Vessel Invasion (L)**

LX Lymphatic vessel invasion cannot be assessed

L0 No lymphatic vessel invasion

L1 Lymphatic vessel invasion

**Venous Invasion (V)**

VX Venous invasion cannot be assessed

V0 No venous invasion

V1 Microscopic venous invasion

V2 Macroscopic venous invasion

Physician's Signature \_\_\_\_\_ Date \_\_\_\_\_

## Stomach

(*Lymphomas, sarcomas, and carcinoid tumors are not included.*)

C16.0 Cardia, NOS  
C16.1 Fundus of stomach  
C16.2 Body of stomach  
C16.3 Gastric antrum

C16.4 Pylorus  
C16.5 Lesser curvature of stomach,  
NOS

C16.8 Greater curvature of stomach,  
NOS  
C16.8 Overlapping lesion of stomach  
C16.9 Stomach, NOS

### SUMMARY OF CHANGES

- T2 lesions have been divided into T2a and T2b.
- T2a is defined as a tumor that invades the muscularis propria.
- T2b is defined as a tumor that invades into subserosa.

### INTRODUCTION

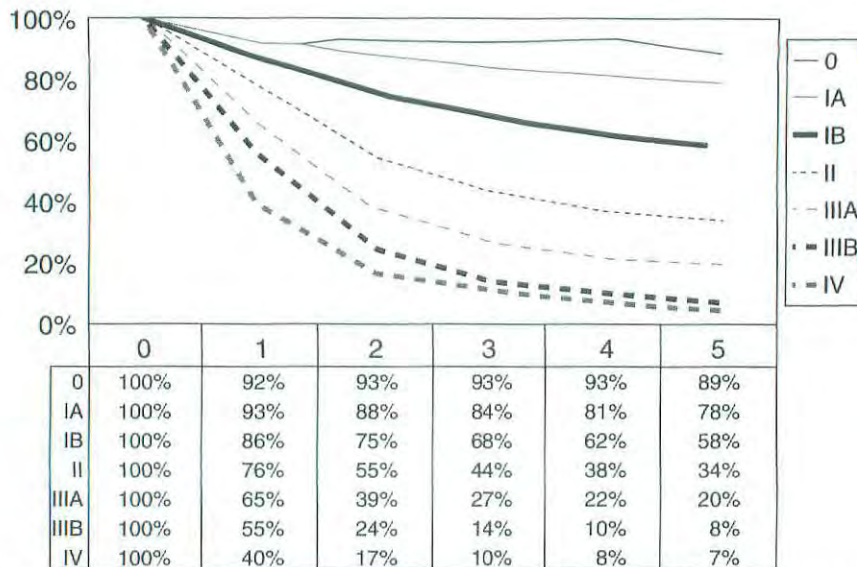
Gastric adenocarcinoma has declined significantly in the United States over the past 70 years, but even so, during the early 21st century, an estimated 22,000 patients develop the disease each year. Of these patients, 13,000 will die, mainly because of nodal and metastatic disease present at the time of initial diagnosis. When worldwide figures are analyzed, the United States ranks 44th in both males and females dying from gastric adenocarcinoma. The highest rates of this disease continue to be in areas of Asia and Russia. Trends in survival rates from the 1970s to the 1990s have unfortunately shown very little improvement. During the 1990s, 20% of gastric carcinoma cases were diagnosed while localized to the gastric wall, whereas 30% had evidence of regional nodal disease. Disease resulting from metastasis to other solid organs within the abdomen, as well as to extra-abdominal sites, represents 35% of all cases. Although overall 5-year survival is approximately 15–20%, the 5-year survival is approximately 55% when disease is localized to the stomach (Fig. 10.1). The involvement of regional nodes reduces the 5-year survival to approximately 20%.

A notable shift in the site of gastric cancer reflects a proportionate increase in disease of the proximal stomach over the past several decades. Previously, there was a predominance of distal gastric cancers presenting as mass lesions or ulceration. Although other malignancies occur in the stomach, approximately 90% of all gastric neoplasms are adenocarcinomas. Tumors of the gastroesophageal (GE) junction may be difficult to stage as either a gastric or an esophageal

primary, especially in view of the increased incidence of adenocarcinoma in the esophagus that presumably results from acid reflux disease. By convention, if more than 50% of the cancer involves the esophagus, the cancer is classified as esophageal. Similarly, if more than 50% of the tumor is below the GE junction, it is classified as gastric in origin. If the tumor is located equally above and below the GE junction, the histology determines the origin of the primary—squamous cell, small cell, and undifferentiated carcinomas are classified as esophageal, and adenocarcinoma and signet ring cell carcinomas are classified as gastric. When Barrett's esophagus (intestinal metaplasia) is present, adenocarcinoma in both the gastric cardia and lower esophagus is most likely to be esophageal in origin.

### ANATOMY

**Primary Site.** The stomach is the first division of the abdominal portion of the alimentary tract, beginning at the gastroesophageal junction and extending to the pylorus. The proximal stomach is located immediately below the diaphragm and is termed the cardia. The remaining portions are the fundus (body) of the stomach and the distal portion of the stomach known as the antrum. The pylorus is a muscular ring that controls the flow of food content from the stomach into the first portion of the duodenum. The medial and lateral curvatures of the stomach are known as the lesser and greater curvatures, respectively. Histologically, the wall



**FIG. 10.1.** One-year through 5-year survival rates of gastrectomy patients. Number of patients by stage group: Stage 0 (322), Stage IA (2,905), Stage IB (4,658), Stage II (6,541), Stage IIIA (7,481), Stage IIIB (2,330), and Stage IV (8,617). From Hundahl SA, Phillips JL, Menck HR: The National Cancer Data Base report on survival of U.S. gastric carcinoma patients treated with gastrectomy. *Cancer* 88:921-932, 2000. © 2000, American Cancer Society. Reprinted by permission of Wiley-Liss, Inc., a subsidiary of John Wiley & Sons, Inc.

of the stomach has five layers: mucosal, submucosal, muscular, subserosal, and serosal.

Staging of primary gastric adenocarcinoma is dependent on the depth of penetration of the primary tumor. The T2 designation has been subdivided into T2a (invasion of the muscularis propria) and T2b (invasion of the subserosa) in order to discriminate between these intramural locations, even though there is no change in the designation in the stage grouping that involves T2a or T2b lesions.

**Regional Lymph Nodes.** Several groups of regional lymph nodes drain the wall of the stomach. These perigastric nodes are found along the lesser and greater curvatures. Other major nodal groups follow the main arterial and venous vessels from the aorta and the portal circulation. Adequate nodal dissection of these regional nodal areas is important to ensure appropriate designation of the pN determination. Although it is suggested that at least 15 regional nodes be assessed pathologically, a pN0 determination may be assigned on the basis of the actual number of nodes evaluated microscopically.

Involvement of other intra-abdominal lymph nodes, such as the hepatoduodenal, retropancreatic, mesenteric, and para-aortic, is classified as distant metastasis. The specific nodal areas are as follows:

*Greater Curvature of Stomach:*

Greater curvature, greater omental, gastroduodenal, gastropyloric, pyloric, and pancreaticoduodenal

*Pancreatic and Splenic Area:*

Pancreaticocolic, peripancreatic, splenic

*Lesser Curvature of Stomach:*

Lesser curvature, lesser omental, left gastric, cardioesophageal, common hepatic, celiac, and hepatoduodenal

*Distant Nodal Groups:*

Retropancreatic, para-aortic, portal, retroperitoneal, mesenteric

**Metastatic Sites.** The most common metastatic distribution is to the liver, peritoneal surfaces, and nonregional or distant lymph nodes. Central nervous system and pulmonary metastases occur but are less frequent. With large, bulky lesions, direct extension may occur to the liver, transverse colon, pancreas, or undersurface of the diaphragm.

**RULES FOR CLASSIFICATION**

**Clinical Staging.** Designated as cTNM, clinical staging is based on evidence of extent of disease acquired before definitive treatment is instituted. It includes physical examination, radiologic imaging, endoscopy, biopsy, and laboratory findings. All cancers should be confirmed histologically.

**Pathologic Staging.** Pathologic staging depends on data acquired clinically, together with findings on subsequent sur-

gical exploration and examination of the pathologic specimen if resection is accomplished. Pathologic assessment of the regional lymph nodes entails their removal and histologic examination to evaluate the total number, as well as the number that contain metastatic tumor. Metastatic nodules in the fat adjacent to a gastric carcinoma, without evidence of residual lymph node tissue, are considered regional lymph node metastases, but nodules implanted on peritoneal surfaces are considered distant metastasis. If there is uncertainty concerning the appropriate T, N, or M assignment, the lower (less advanced) category should be selected. This will also be reflected in the stage grouping.

## DEFINITION OF TNM

### Primary Tumor (T)

- TX Primary tumor cannot be assessed  
 T0 No evidence of primary tumor  
 Tis Carcinoma *in situ*: intraepithelial tumor without invasion of the lamina propria  
 T1 Tumor invades lamina propria or submucosa  
 T2 Tumor invades muscularis propria or subserosa\*  
 T2a Tumor invades muscularis propria  
 T2b Tumor invades subserosa  
 T3 Tumor penetrates serosa (visceral peritoneum) without invasion of adjacent structures\*\*,\*\*\*  
 T4 Tumor invades adjacent structures\*\*,\*\*\*

\*Note: A tumor may penetrate the muscularis propria with extension into the gastrocolic or gastrohepatic ligaments, or into the greater or lesser omentum, without perforation of the visceral peritoneum covering these structures. In this case, the tumor is classified T2. If there is perforation of the visceral peritoneum covering the gastric ligaments or the omentum, the tumor should be classified T3.

\*\*Note: The adjacent structures of the stomach include the spleen, transverse colon, liver, diaphragm, pancreas, abdominal wall, adrenal gland, kidney, small intestine, and retroperitoneum.

\*\*\*Note: Intramural extension to the duodenum or esophagus is classified by the depth of the greatest invasion in any of these sites, including the stomach.

### Regional Lymph Nodes (N)

- NX Regional lymph node(s) cannot be assessed  
 N0 No regional lymph node metastasis\*  
 N1 Metastasis in 1 to 6 regional lymph nodes  
 N2 Metastasis in 7 to 15 regional lymph nodes  
 N3 Metastasis in more than 15 regional lymph nodes

\*Note: A designation of pN0 should be used if all examined lymph nodes are negative, regardless of the total number removed and examined.

### Distant Metastasis (M)

- MX Distant metastasis cannot be assessed  
 M0 No distant metastasis  
 M1 Distant metastasis

## STAGE GROUPING

Stage 0	Tis	N0	M0
Stage IA	T1	N0	M0
Stage IB	T1	N1	M0
	T2a/b	N0	M0
Stage II	T1	N2	M0
	T2a/b	N1	M0
	T3	N0	M0
Stage IIIA	T2a/b	N2	M0
	T3	N1	M0
	T4	N0	M0
Stage IIIB	T3	N2	M0
Stage IV	T4	N1-3	M0
	T1-3	N3	M0
	Any T	Any N	M1

## HISTOPATHOLOGIC TYPE

The staging recommendations apply only to carcinomas. Lymphomas, sarcomas, and carcinoid tumors are not included. Adenocarcinomas may be divided into the general subtypes listed below. In addition, the histologic terms intestinal, diffuse, and mixed may be applied.

The histologic subtypes are:

- Adenocarcinoma
- Papillary adenocarcinoma
- Tubular adenocarcinoma
- Mucinous adenocarcinoma
- Signet ring cell carcinoma
- Adenosquamous carcinoma
- Squamous cell carcinoma
- Small cell carcinoma
- Undifferentiated carcinoma

## HISTOLOGIC GRADE (G)

- GX Grade cannot be assessed  
 G1 Well differentiated  
 G2 Moderately differentiated  
 G3 Poorly differentiated  
 G4 Undifferentiated

## PROGNOSTIC FACTORS

Treatment is a major prognostic factor for gastric cancer. Patients who are not resected have a poor prognosis, with



survival ranging from 3 to 11 months. For those patients undergoing complete resection, the factors that affect prognosis include the location of the tumor in the stomach and the gross pathologic type, as well as the T and N classification. The prognosis for proximal gastric cancer is less favorable than for distal lesions, and the classic gross pathologic type, as described by Borrmann (I—polypoid, II—ulcerocancer, III—ulcerating and infiltrating, and IV—infiltrating), has prognostic impact. Polypoid and ulcerocancers (I and II) that are resected have a considerably better prognosis than Borrmann III and IV, independent of the presence or absence of regional lymph node involvement.

Depth of invasion into the gastric wall (T) correlates with reduced survival, but regional lymphatic spread is probably the most powerful prognostic factor. The histologic classification of Lauren has some impact on prognosis, but diffuse lesions are more often proximally located and larger than the intestinal-type lesions that generally tend to be distal. Histologic grade is an important prognostic factor. High pre-operative serum levels for tumor markers CEA and CA 19-9 have been associated with a less favorable outcome.

## BIBLIOGRAPHY

Alexander HR, Kelsen DG, Tepper JC: Cancer of the stomach. In DeVita VT, Hellman S, Rosenberg SA (Eds.): Cancer: principles and practice of oncology, 5th ed. Philadelphia: Lippincott-Raven, 1021-1054, 1997

Bonen Kamp JJ, Hermans J, Sasako M, et al: Extended lymph-node dissection for gastric cancer. Dutch Gastric Cancer Group. *N Engl J Med* 340:908-914, 1999

Bunt AM, Hermans J, Smith VT, et al: Surgical/pathologic-stage migration confounds comparisons of gastric cancer survival rates between Japan and Western countries. *J Clin Oncol* 13:19-25, 1995

Greenlee RT, Hill-Harmon M, Murray T, Thun M: Cancer statistics, 2001. *Ca Cancer J Clin* 51:15-36, 2001

Hermanek P. Prognostic factors in stomach cancer surgery. *Eur J Surg Oncol* 12:241-246, 1986

Hermanek P, Wittekind C. Residual tumor (R) classification and prognosis. *Semin Surg Oncol* 10:12-20, 1994

Hochwald SN, Kim S, Klimstra DS, et al: Analysis of 154 actual five-year survivors of gastric cancer. *J Gastrointest Surg* 4:520-525, 2000

Ichikura T, Tomimatsu S, Okusa Y, et al. Comparison of the prognostic significance between the number of metastatic lymph nodes and nodal stage based on their location in patients with gastric cancer. *J Clin Oncol* 11:1894-1900, 1993

Hundahl SA, Phillips JL, Menck HR. The National Cancer Data Base report on survival of U.S. gastric carcinoma patients treated with gastrectomy. *Cancer* 88:921-932, 2000

Kennedy BJ. Gastric cancer staging and natural history. In Wanebo HJ (Ed.): Surgery for gastrointestinal cancer: a multidisciplinary approach. Philadelphia: Lippincott-Raven, 299-303, 1977

Kodera Y, Yamamura Y, Shimizu Y, et al: The number of metastatic lymph nodes: a promising prognosis determinant for gastric carcinoma in the latest edition of the TNM classification. *J Am Coll Surg* 187:597-603, 1998

Lauren P. The two histological main types of gastric carcinoma: diffuse and so-called intestinal-type carcinoma. *Acta Path Microbiol Scand* 64:31-49, 1965

Lawrence W, Menck HR, Steele GD, et al: The National Cancer Data Base report on gastric cancer. *Cancer* 75:1734-1744, 1995

Wittekind C, Henson DE, Hutter RVP, Sobin LH: TNM supplement: a commentary on uniform use. 2nd ed. New York: Wiley-Liss, 2001

## HISTOLOGIES—STOMACH

8010/2	Carcinoma <i>in situ</i> , NOS
8010/3	Carcinoma, NOS
8012/3	Large cell carcinoma, NOS
8013/3	Large cell neuroendocrine carcinoma
8014/3	Large cell carcinoma with rhabdoid phenotype
8020/3	Carcinoma, undifferentiated, NOS
8021/3	Carcinoma, anaplastic, NOS
8022/3	Pleomorphic carcinoma
8030/3	Giant cell and spindle cell carcinoma
8031/3	Giant cell carcinoma
8032/3	Spindle cell carcinoma, NOS
8033/3	Pseudosarcomatous carcinoma
8035/3	Carcinoma with osteoclast-like giant cells
8041/3	Small cell carcinoma, NOS
8042/3	Oat cell carcinoma
8043/3	Small cell carcinoma, fusiform cell
8044/3	Small cell carcinoma, intermediate cell
8045/3	Combined small cell carcinoma
8046/3	Non-small cell carcinoma
8070/2	Squamous cell carcinoma <i>in situ</i> , NOS
8070/3	Squamous cell carcinoma, NOS
8071/3	Squamous cell carcinoma, keratinizing, NOS
8072/3	Squamous cell carcinoma, large cell
8073/3	Squamous cell carcinoma, small cell, non-keratinizing
8074/3	Squamous cell carcinoma, spindle cell
8075/3	Squamous cell carcinoma, adenoid
8076/2	Squamous cell carcinoma <i>in situ</i> with questionable stromal invasion
8076/3	Squamous cell carcinoma, microinvasive
8082/3	Lymphoepithelial carcinoma
8083/3	Basaloid squamous cell carcinoma
8084/3	Squamous cell carcinoma, clear cell type
8140/2	Adenocarcinoma <i>in situ</i> , NOS
8140/3	Adenocarcinoma, NOS
8141/3	Scirrhous adenocarcinoma
8142/3	Linitis plastica
8143/3	Superficial spreading adenocarcinoma
8144/3	Adenocarcinoma, intestinal type
8145/3	Carcinoma, diffuse type
8147/3	Basal cell adenocarcinoma
8148/2	Glandular intraepithelial neoplasia, grade III
8210/2	Adenocarcinoma <i>in situ</i> in adenomatous polyp
8210/3	Adenocarcinoma in adenomatous polyp
8211/3	Tubular adenocarcinoma
8214/3	Parietal cell carcinoma
8221/3	Adenocarcinoma in multiple adenomatous polyps
8230/3	Solid carcinoma, NOS
8244/3	Composite carcinoma

**HISTOLOGIES—STOMACH (CONT.)**

8245/3	Adenocarcinoid tumor	8453/3	Intraductal papillary-mucinous carcinoma, invasive
8246/3	Neuroendocrine carcinoma, NOS	8460/3	Papillary serous cystadenocarcinoma
8255/3	Adenocarcinoma with mixed subtypes	8461/3	Serous surface papillary carcinoma
8260/3	Papillary adenocarcinoma, NOS	8470/2	Mucinous cystadenocarcinoma, non-invasive
8261/2	Adenocarcinoma <i>in situ</i> in villous adenoma	8470/3	Mucinous cystadenocarcinoma, NOS
8261/3	Adenocarcinoma in villous adenoma	8471/3	Papillary mucinous cystadenocarcinoma
8262/3	Villous adenocarcinoma	8480/3	Mucinous adenocarcinoma
8263/2	Adenocarcinoma <i>in situ</i> in tubulovillous adenoma	8481/3	Mucin-producing adenocarcinoma
8263/3	Adenocarcinoma in tubulovillous adenoma	8490/3	Signet ring cell carcinoma
8310/3	Clear cell adenocarcinoma, NOS	8500/2	Intraductal carcinoma, non-infiltrating, NOS
8320/3	Granular cell carcinoma	8503/2	Non-infiltrating intraductal papillary adenocarcinoma
8430/3	Mucoepidermoid carcinoma	8503/3	Intraductal papillary adenocarcinoma with invasion
8440/3	Cystadenocarcinoma, NOS	8550/3	Acinar cell carcinoma
8441/3	Serous cystadenocarcinoma, NOS	8551/3	Acinar cell cystadenocarcinoma
8450/3	Papillary cystadenocarcinoma, NOS	8560/3	Adenosquamous carcinoma
8452/3	Solid pseudopapillary carcinoma	8570/3	Adenocarcinoma with squamous metaplasia
8453/2	Intraductal papillary-mucinous carcinoma, non-invasive	8571/3	Adenocarcinoma with cartilaginous and osseous metaplasia
		8572/3	Adenocarcinoma with spindle cell metaplasia

## STOMACH

Hospital Name/Address
-----------------------

Patient Name/Information
--------------------------

Type of Specimen \_\_\_\_\_

Histopathologic Type \_\_\_\_\_

Tumor Size \_\_\_\_\_

3

### DEFINITIONS

Clinical	Pathologic	Primary Tumor (T)
<input type="checkbox"/>	<input type="checkbox"/>	TX Primary tumor cannot be assessed
<input type="checkbox"/>	<input type="checkbox"/>	T0 No evidence of primary tumor
<input type="checkbox"/>	<input type="checkbox"/>	Tis Carcinoma <i>in situ</i> : intraepithelial tumor without invasion of the lamina propria
<input type="checkbox"/>	<input type="checkbox"/>	T1 Tumor invades lamina propria or submucosa
<input type="checkbox"/>	<input type="checkbox"/>	T2 Tumor invades muscularis propria or subserosa
<input type="checkbox"/>	<input type="checkbox"/>	T2a Tumor invades muscularis propria
<input type="checkbox"/>	<input type="checkbox"/>	T2b Tumor invades subserosa
<input type="checkbox"/>	<input type="checkbox"/>	T3 Tumor penetrates serosa (visceral peritoneum) without invasion of adjacent structures
<input type="checkbox"/>	<input type="checkbox"/>	T4 Tumor invades adjacent structures

Clinical	Pathologic	Regional Lymph Nodes (N)
<input type="checkbox"/>	<input type="checkbox"/>	NX Regional lymph nodes(s) cannot be assessed
<input type="checkbox"/>	<input type="checkbox"/>	N0 No regional lymph node metastasis
<input type="checkbox"/>	<input type="checkbox"/>	N1 Metastasis in 1 to 6 regional lymph nodes
<input type="checkbox"/>	<input type="checkbox"/>	N2 Metastasis in 7 to 15 regional lymph nodes
<input type="checkbox"/>	<input type="checkbox"/>	N3 Metastasis in more than 15 regional lymph nodes
Total nodes examined = _____		

Clinical	Pathologic	Distant Metastasis (M)
<input type="checkbox"/>	<input type="checkbox"/>	MX Distant metastasis cannot be assessed
<input type="checkbox"/>	<input type="checkbox"/>	M0 No distant metastasis
<input type="checkbox"/>	<input type="checkbox"/>	M1 Distant metastasis
Biopsy of metastatic site performed ..... <input type="checkbox"/> Y..... <input type="checkbox"/> N		
Source of pathologic metastatic specimen _____		

Clinical	Pathologic	Stage Grouping
<input type="checkbox"/>	<input type="checkbox"/>	0 Tis N0 M0
<input type="checkbox"/>	<input type="checkbox"/>	IA T1 N0 M0
<input type="checkbox"/>	<input type="checkbox"/>	IB T1 N1 M0
<input type="checkbox"/>	<input type="checkbox"/>	T2a/b N0 M0
<input type="checkbox"/>	<input type="checkbox"/>	II T1 N2 M0
<input type="checkbox"/>	<input type="checkbox"/>	T2a/b N1 M0
<input type="checkbox"/>	<input type="checkbox"/>	T3 N0 M0
<input type="checkbox"/>	<input type="checkbox"/>	IIIA T2a/b N2 M0
<input type="checkbox"/>	<input type="checkbox"/>	T3 N1 M0
<input type="checkbox"/>	<input type="checkbox"/>	T4 N0 M0
<input type="checkbox"/>	<input type="checkbox"/>	IIIB T3 N2 M0
<input type="checkbox"/>	<input type="checkbox"/>	IV T4 N1-3 M0
<input type="checkbox"/>	<input type="checkbox"/>	T1-3 N3 M0
<input type="checkbox"/>	<input type="checkbox"/>	Any T Any N M1

(continued on reverse side)

**Histologic Grade (G)**

- GX Grade cannot be assessed
- G1 Well differentiated
- G2 Moderately differentiated
- G3 Poorly differentiated
- G4 Undifferentiated

**Residual Tumor (R)**

- RX Presence of residual tumor cannot be assessed
- R0 No residual tumor
- R1 Microscopic residual tumor
- R2 Macroscopic residual tumor

**Additional Descriptors**

For identification of special cases of TNM or pTNM classifications, the “m” suffix and “y,” “r,” and “a” prefixes are used. Although they do not affect the stage grouping, they indicate cases needing separate analysis.

- m suffix** indicates the presence of multiple primary tumors in a single site and is recorded in parentheses: pT(m)NM.
- y prefix** indicates those cases in which classification is performed during or following initial multimodality therapy. The cTNM or pTNM category is identified by a “y” prefix. The ycTNM or ypTNM categorizes the extent of tumor actually present at the time of that examination. The “y” categorization is not an estimate of tumor prior to multimodality therapy.
- r prefix** indicates a recurrent tumor when staged after a disease-free interval, and is identified by the “r” prefix: rTNM.
- a prefix** designates the stage determined at autopsy: aTNM.

**Prognostic Indicators (if applicable)**

**Notes**

**Additional Descriptors**

**Lymphatic Vessel Invasion (L)**  
LX Lymphatic vessel invasion cannot be assessed

L0 No lymphatic vessel invasion

L1 Lymphatic vessel invasion

**Venous Invasion (V)**

VX Venous invasion cannot be assessed

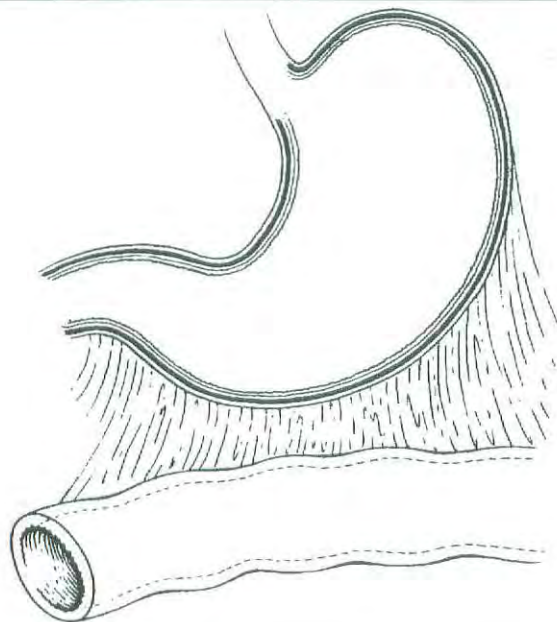
V0 No venous invasion

V1 Microscopic venous invasion

V2 Macroscopic venous invasion

**ILLUSTRATION**

Indicate on diagram primary tumor and regional nodes involved.



Physician's Signature \_\_\_\_\_ Date \_\_\_\_\_

## Small Intestine

(Lymphomas, carcinoid tumors, and visceral sarcomas are not included.)

C17.0 Duodenum  
C17.1 Jejunum  
C17.2 Ileum

C17.8 Overlapping lesion of small intestine

C17.9 Small intestine, NOS

### SUMMARY OF CHANGES

- The definition of TNM and the Stage Grouping for this chapter have not changed from the Fifth Edition.

### INTRODUCTION

Although the small intestine accounts for one of the largest surface areas in the human body, less than 2% of all malignant tumors of the gastrointestinal tract actually occur in the small bowel. Most cancers occur in the first or second portion of the duodenum and represent adenocarcinomas. A variety of tumors occur in the small intestine, approximately 50% of the primary malignant tumors being adenocarcinomas. An increased incidence of second malignancies has been noted in patients with primary small bowel adenocarcinoma. At the beginning of the 21st century, approximately 5,000 new cases of cancer involving the small intestine are seen annually in the United States. The 1,200 deaths predicted to occur from small intestinal cancer are divided equally between men and women. The patterns of local, regional, and metastatic spread for adenocarcinomas of the small intestine are comparable to those of similar histologic malignancies in other areas of the gastrointestinal tract. The classification and stage grouping described in this chapter are used for both clinical and pathologic staging of carcinomas of the small bowel and do not apply to other types of malignant small bowel tumors. Although small bowel carcinoid tumors are not traditionally staged using the TNM system, reports from the United States and throughout the world attempt to stage these neuroendocrine tumors using the TNM system.

### ANATOMY

**Primary Site.** This classification applies to carcinomas arising in the duodenum, jejunum, and ileum. It does not apply to carcinomas arising in the ileocecal valve or to car-

cinomas that may arise in Meckel's diverticulum. Carcinomas arising in the ampulla of Vater are staged according to the system described in Chapter 17.

**Duodenum.** About 25 cm in length, the duodenum extends from the pyloric sphincter of the stomach to the jejunum. It is usually divided anatomically into four parts, with the common bile duct and pancreatic duct opening into the second part at the ampulla of Vater.

**Jejunum and Ileum.** The jejunum (8 feet in length) and ileum (12 feet in length) extend from the junction with the duodenum proximally to the ileocecal valve distally. The division point between the jejunum and the ileum is arbitrary. As a general rule, the jejunum includes the proximal 40% and the ileum includes the distal 60% of the small intestine, exclusive of the duodenum.

**General.** The jejunal and ileal portions of the small intestine are supported by a fold of the peritoneum containing the blood supply and the regional lymph nodes, the mesentery. The shortest segment, the duodenum, has no real mesentery and is covered only by peritoneum anteriorly. The wall of all parts of the small intestine has five layers: mucosal, submucosal, muscular, subserosal, and serosal. A very thin layer of smooth muscle cells, the muscularis mucosae, separates the mucosa from the submucosa. The small intestine is entirely ensheathed by peritoneum, except for a narrow strip of bowel that is attached to the mesentery and that part of the duodenum that is located retroperitoneally.

**Regional Lymph Nodes.** For pN, histologic examination of a regional lymphadenectomy specimen will ordinarily

include a representative number of lymph nodes distributed along the mesenteric vessels extending to the base of the mesentery.

**Duodenum:**

- Duodenal
- Hepatic
- Pancreaticoduodenal
- Infrapyloric
- Gastroduodenal
- Pyloric
- Superior mesenteric
- Pericholedochal
- Regional lymph nodes, NOS

**Ileum and Jejunum:**

- Posterior cecal (terminal ileum only)
- Ileocolic (terminal ileum only)
- Superior mesenteric
- Mesenteric, NOS
- Regional lymph nodes, NOS

**Metastatic Sites.** Cancers of the small intestine can metastasize to most organs, especially the liver, or to the peritoneal surfaces. Involvement of regional lymph nodes and invasion of adjacent structures are most common. Involvement of the celiac nodes is considered M1 disease for carcinomas of the duodenum, jejunum, and ileum. The presence of distant metastases and the presence of residual disease (R) have the most influence on survival.

**RULES FOR CLASSIFICATION**

**Clinical Staging.** Imaging studies such as CT and MRI play a major role in clinical staging. Metastatic disease is assessed by routine chest films and chest CT. Intraoperative assessment plays a role in clinical evaluation, especially when tumor cannot be resected. Metastatic involvement of the liver may be evaluated by intraoperative ultrasonography.

**Pathologic Staging.** The primary tumor is staged according to its depth of penetration and the involvement of adjacent structures or distant sites. Lateral spread within the duodenum, jejunum, or ileum is not considered in this classification. Only the depth of tumor penetration in the bowel wall defines the pT stage.

Although the two are similar, differences between this staging system and that of the colon should be noted. In the colon, pTis applies to intraepithelial (*in situ*) as well as to intramucosal lesions. In the small intestine, intramucosal spread is listed as pT1 instead of pTis. In this regard, the pT1 definition for the small bowel is essentially the same as the pT1 defined for stomach lesions. Invasion through the wall is staged the same as for colon cancer. Discontinuous hematogenous metastases or peritoneal metastases are coded as

M1. In addition, there is no subdivision within the N category based on the number of nodes involved with tumor.

**DEFINITION OF TNM**

**Primary Tumor (T)**

- TX Primary tumor cannot be assessed
- T0 No evidence of primary tumor
- Tis Carcinoma *in situ*
- T1 Tumor invades lamina propria or submucosa
- T2 Tumor invades muscularis propria
- T3 Tumor invades through the muscularis propria into the subserosa or into the nonperitonealized perimuscular tissue (mesentery or retroperitoneum) with extension 2 cm or less\*
- T4 Tumor perforates the visceral peritoneum or directly invades other organs or structures (includes other loops of small intestine, mesentery, or retroperitoneum more than 2 cm, and abdominal wall by way of serosa; for duodenum only, invasion of pancreas)

\*Note: The nonperitonealized perimuscular tissue is, for jejunum and ileum, part of the mesentery and, for duodenum in areas where serosa is lacking, part of the retroperitoneum.

**Regional Lymph Nodes (N)**

- NX Regional lymph nodes cannot be assessed
- N0 No regional lymph node metastasis
- N1 Regional lymph node metastasis

**Distant Metastasis (M)**

- MX Distant metastasis cannot be assessed
- M0 No distant metastasis
- M1 Distant metastasis

**STAGE GROUPING**

Stage 0	Tis	N0	M0
Stage I	T1	N0	M0
	T2	N0	M0
Stage II	T3	N0	M0
	T4	N0	M0
Stage III	Any T	N1	M0
Stage IV	Any T	Any N	M1

**HISTOPATHOLOGIC TYPE**

This staging classification applies only to carcinomas arising in the small intestine. Lymphomas, carcinoid tumors, and visceral sarcomas are not included. The three major histopathologic types are carcinomas (such as adenocarcinoma), carcinoid tumors, and lymphomas (extranodal). Primary lymphomas are staged as extranodal lymphomas. Carcinoid

tumors of the small intestine have no staging system, but size, depth of invasion, regional lymph node status, and distant metastasis are considered significant prognostic factors. Less common malignant tumors include leiomyosarcoma, although leiomyomas are plentiful. An increase in gastrointestinal stromal tumors (GIST) has occurred because of reclassification of stromal tumors of the gut wall into this category. The malignant GIST lesions are not classified using TNM nomenclature, but they should be denoted in registry data as localized or metastatic, which includes nodal or visceral metastases. Although carcinoid and GIST lesions are currently not staged in the TNM system, these lesions may be placed in appropriate TNM stage groupings in order to collect data sets that will enhance staging strategies according to outcomes.

### HISTOLOGIC GRADE (G)

- GX Grade cannot be assessed
- G1 Well differentiated
- G2 Moderately differentiated
- G3 Poorly differentiated
- G4 Undifferentiated

### PROGNOSTIC FACTORS

Small bowel carcinoma is rare, so various clinical prognostic factors such as age, gender, and ethnic origin are impossible to assess. The anatomic extent of the tumor is the strongest indicator of outcome when the tumor can be resected. Prognosis after incomplete removal is poor.

The pathologic extent of tumor, in terms of the depth of invasion through the bowel wall, is a significant prognostic factor, as is regional lymphatic spread. Prognosis is also influenced by histologic grade. There are insufficient data to assess the impact of other more sophisticated pathologic factors and serum tumor markers, but it is logical to believe that the effect of those factors would be similar to that observed with colorectal cancer.

### BIBLIOGRAPHY

Brucher BL, Roder JD, Fink U, et al: Prognostic factors in resected primary small bowel tumors. *Dig Surg* 15:42–51, 1998

Coit D: Cancer of the small intestine. In DeVita VT, Hellman S, Rosenberg SA (Eds.): *Cancer—principles and practice of oncology*. Philadelphia: Lippincott-Raven, 1128–1143, 1997

Crosby JA, Catton CN, Davis A, et al: Malignant gastrointestinal stromal tumors of the small intestine: a review of 50 cases from a prospective database. *Ann Surg Oncol* 8:50–59, 2001

Greenlee RT, Hill-Harmon M, Murray T, Thun M: *Cancer statistics, 2001*. *Ca Cancer J Clin* 51:15–37, 2001

Ludwig DJ, Traverso LW: Gut stromal tumors and their clinical behavior. *Am J Surg* 173:390–394, 1997

Minardi AJ Jr, Zibari GB, Aultman DF, et al: Small-bowel tumors. *J Am Coll Surg* 186:664–668, 1998

Naef M, Buhlmann M, Baer HU: Small bowel tumors: diagnosis, therapy and prognostic factors. *Lang Arch Surg* 384:176–180, 1999

Negri E, Bosetti C, LaVecchia C, et al: Risk factors for adenocarcinoma of the small intestine. *Int J Ca* 82:171–174, 1999

Neugut AI, Jacobson JS, Suh S, et al: The epidemiology of cancer of the small bowel. *Ca Epidemiol Bio Prev* 7:243–51, 1998

Ripley D, Weinerman BH: Increased incidence of second malignancies associated with small bowel adenocarcinoma. *Canad J Gastroenterol* 11:65–68, 1997

### HISTOLOGIES—SMALL INTESTINE

- 8010/2 Carcinoma *in situ*, NOS
- 8010/3 Carcinoma, NOS
- 8012/3 Large cell carcinoma, NOS
- 8013/3 Large cell neuroendocrine carcinoma
- 8014/3 Large cell carcinoma with rhabdoid phenotype
- 8020/3 Carcinoma, undifferentiated, NOS
- 8021/3 Carcinoma, anaplastic, NOS
- 8022/3 Pleomorphic carcinoma
- 8030/3 Giant cell and spindle cell carcinoma
- 8031/3 Giant cell carcinoma
- 8032/3 Spindle cell carcinoma, NOS
- 8033/3 Pseudosarcomatous carcinoma
- 8035/3 Carcinoma with osteoclast-like giant cells
- 8041/3 Small cell carcinoma, NOS
- 8042/3 Oat cell carcinoma
- 8043/3 Small cell carcinoma, fusiform cell
- 8044/3 Small cell carcinoma, intermediate cell
- 8045/3 Combined small cell carcinoma
- 8046/3 Non-small cell carcinoma
- 8070/2 Squamous cell carcinoma *in situ*, NOS
- 8070/3 Squamous cell carcinoma, NOS
- 8071/3 Squamous cell carcinoma, keratinizing, NOS
- 8072/3 Squamous cell carcinoma, large cell
- 8073/3 Squamous cell carcinoma, small cell, non-keratinizing
- 8074/3 Squamous cell carcinoma, spindle cell
- 8075/3 Squamous cell carcinoma, adenoid
- 8076/2 Squamous cell carcinoma *in situ* with questionable stromal invasion
- 8076/3 Squamous cell carcinoma, microinvasive
- 8082/3 Lymphoepithelial carcinoma
- 8083/3 Basaloid squamous cell carcinoma
- 8084/3 Squamous cell carcinoma, clear cell type
- 8140/2 Adenocarcinoma *in situ*, NOS
- 8140/3 Adenocarcinoma, NOS
- 8141/3 Scirrhous adenocarcinoma
- 8142/3 Linitis plastica
- 8143/3 Superficial spreading adenocarcinoma
- 8144/3 Adenocarcinoma, intestinal type
- 8145/3 Carcinoma, diffuse type
- 8147/3 Basal cell adenocarcinoma
- 8148/2 Glandular intraepithelial neoplasia, grade III
- 8210/2 Adenocarcinoma *in situ* in adenomatous polyp
- 8210/3 Adenocarcinoma in adenomatous polyp
- 8211/3 Tubular adenocarcinoma
- 8214/3 Parietal cell carcinoma
- 8221/3 Adenocarcinoma in multiple adenomatous polyps
- 8230/3 Solid carcinoma, NOS
- 8244/3 Composite carcinoid

## HISTOLOGIES—SMALL INTESTINE (CONT.)

8245/3	Adenocarcinoid tumor	8453/3	Intraductal papillary-mucinous carcinoma, invasive
8246/3	Neuroendocrine carcinoma, NOS	8460/3	Papillary serous cystadenocarcinoma
8255/3	Adenocarcinoma with mixed subtypes	8461/3	Serous surface papillary carcinoma
8260/3	Papillary adenocarcinoma, NOS	8470/2	Mucinous cystadenocarcinoma, non-invasive
8261/2	Adenocarcinoma <i>in situ</i> in villous adenoma	8470/3	Mucinous cystadenocarcinoma, NOS
8261/3	Adenocarcinoma in villous adenoma	8471/3	Papillary mucinous cystadenocarcinoma
8262/3	Villous adenocarcinoma	8480/3	Mucinous adenocarcinoma
8263/2	Adenocarcinoma <i>in situ</i> in tubulovillous adenoma	8481/3	Mucin-producing adenocarcinoma
8263/3	Adenocarcinoma in tubulovillous adenoma	8490/3	Signet ring cell carcinoma
8310/3	Clear cell adenocarcinoma, NOS	8500/2	Intraductal carcinoma, non-infiltrating, NOS
8320/3	Granular cell carcinoma	8503/2	Non-infiltrating intraductal papillary adenocarcinoma
8430/3	Mucoepidermoid carcinoma	8503/3	Intraductal papillary adenocarcinoma with invasion
8440/3	Cystadenocarcinoma, NOS	8550/3	Acinar cell carcinoma
8441/3	Serous cystadenocarcinoma, NOS	8551/3	Acinar cell cystadenocarcinoma
8450/3	Papillary cystadenocarcinoma, NOS	8560/3	Adenosquamous carcinoma
8452/3	Solid pseudopapillary carcinoma	8570/3	Adenocarcinoma with squamous metaplasia
8453/2	Intraductal papillary-mucinous carcinoma, non-invasive	8571/3	Adenocarcinoma with cartilaginous and osseous metaplasia
		8572/3	Adenocarcinoma with spindle cell metaplasia



## SMALL INTESTINE

Hospital Name/Address
-----------------------

Patient Name/Information
--------------------------

Type of Specimen \_\_\_\_\_

Histopathologic Type \_\_\_\_\_

Tumor Size \_\_\_\_\_

3

### DEFINITIONS

Clinical	Pathologic	<b>Primary Tumor (T)</b>	
<input type="checkbox"/>	<input type="checkbox"/>	TX	Primary tumor cannot be assessed
<input type="checkbox"/>	<input type="checkbox"/>	T0	No evidence of primary tumor
<input type="checkbox"/>	<input type="checkbox"/>	Tis	Carcinoma <i>in situ</i>
<input type="checkbox"/>	<input type="checkbox"/>	T1	Tumor invades lamina propria or submucosa
<input type="checkbox"/>	<input type="checkbox"/>	T2	Tumor invades muscularis propria
<input type="checkbox"/>	<input type="checkbox"/>	T3	Tumor invades through the muscularis propria into the subserosa or into the nonperitonealized perimuscular tissue (mesentery or retroperitoneum) with extension 2 cm or less <sup>1)</sup>
<input type="checkbox"/>	<input type="checkbox"/>	T4	Tumor perforates the visceral peritoneum or directly invades other organs or structures (includes other loops of small intestine, mesentery, or retroperitoneum more than 2 cm, and abdominal wall by way of serosa; for duodenum only, invasion of pancreas)

#### Notes

1. The nonperitonealized perimuscular tissue is, for jejunum and ileum, part of the mesentery and, for duodenum in areas where serosa is lacking, part of the retroperitoneum.

Clinical	Pathologic	<b>Regional Lymph Nodes (N)</b>	
<input type="checkbox"/>	<input type="checkbox"/>	NX	Regional lymph nodes cannot be assessed
<input type="checkbox"/>	<input type="checkbox"/>	N0	No regional lymph node metastasis
<input type="checkbox"/>	<input type="checkbox"/>	N1	Regional lymph node metastasis

Clinical	Pathologic	<b>Distant Metastasis (M)</b>	
<input type="checkbox"/>	<input type="checkbox"/>	MX	Distant metastasis cannot be assessed
<input type="checkbox"/>	<input type="checkbox"/>	M0	No distant metastasis
<input type="checkbox"/>	<input type="checkbox"/>	M1	Distant metastasis

Biopsy of metastatic site performed .... Y..... N

Source of pathologic metastatic specimen \_\_\_\_\_

Clinical	Pathologic	<b>Stage Grouping</b>			
<input type="checkbox"/>	<input type="checkbox"/>	0	Tis	N0	M0
<input type="checkbox"/>	<input type="checkbox"/>	I	T1	N0	M0
			T2	N0	M0
<input type="checkbox"/>	<input type="checkbox"/>	II	T3	N0	M0
			T4	N0	M0
<input type="checkbox"/>	<input type="checkbox"/>	III	Any T	N1	M0
<input type="checkbox"/>	<input type="checkbox"/>	IV	Any T	Any N	M1

(continued on reverse side)

**Histologic Grade (G)**

- GX Grade cannot be assessed
- G1 Well differentiated
- G2 Moderately differentiated
- G3 Poorly differentiated
- G4 Undifferentiated

**Residual Tumor (R)**

- RX Presence of residual tumor cannot be assessed
- R0 No residual tumor
- R1 Microscopic residual tumor
- R2 Macroscopic residual tumor

**Additional Descriptors**

For identification of special cases of TNM or pTNM classifications, the “m” suffix and “y,” “r,” and “a” prefixes are used. Although they do not affect the stage grouping, they indicate cases needing separate analysis.

- m suffix** indicates the presence of multiple primary tumors in a single site and is recorded in parentheses: pT(m)NM.
- y prefix** indicates those cases in which classification is performed during or following initial multimodality therapy. The cTNM or pTNM category is identified by a “y” prefix. The ycTNM or ypTNM categorizes the extent of tumor actually present at the time of that examination. The “y” categorization is not an estimate of tumor prior to multimodality therapy.
- r prefix** indicates a recurrent tumor when staged after a disease-free interval, and is identified by the “r” prefix: rTNM.
- a prefix** designates the stage determined at autopsy: aTNM.

**Prognostic Indicators (if applicable)**

**Notes**

**Additional Descriptors**

**Lymphatic Vessel Invasion (L)**  
LX Lymphatic vessel invasion cannot be assessed

L0 No lymphatic vessel invasion

L1 Lymphatic vessel invasion

**Venous Invasion (V)**

VX Venous invasion cannot be assessed

V0 No venous invasion

V1 Microscopic venous invasion

V2 Macroscopic venous invasion

Physician's Signature \_\_\_\_\_ Date \_\_\_\_\_

## Colon and Rectum

*(Sarcomas, lymphomas, and carcinoid tumors of the large intestine or appendix are not included.)*

C18.0 Cecum	C18.4 Transverse colon	C18.8 Overlapping lesion of colon
C18.1 Appendix	C18.5 Splenic flexure of colon	C18.9 Colon, NOS
C18.2 Ascending colon	C18.6 Descending colon	C19.9 Rectosigmoid junction
C18.3 Hepatic flexure of colon	C18.7 Sigmoid colon	C20.9 Rectum, NOS

### SUMMARY OF CHANGES

- A revised description of the anatomy of the colon and rectum better delineates the data concerning the boundaries between colon, rectum, and anal canal. Adenocarcinomas of the vermiform appendix are classified according to the TNM staging system but should be recorded separately, whereas cancers that occur in the anal canal are staged according to the classification used for the anus.
- Smooth metastatic nodules in the pericolic or perirectal fat are considered lymph node metastases and will be counted in the N staging. In contrast, irregularly contoured metastatic nodules in the peritumoral fat are considered vascular invasion and will be coded as an extension of the T category as either a V1 (microscopic vascular invasion) if only microscopically visible or a V2 (macroscopic vascular invasion) if grossly visible.
- Stage Group II is subdivided into IIA and IIB on the basis of whether the primary tumor is T3 or T4, respectively.
- Stage Group III is subdivided into IIIA (T1–2N1M0), IIIB (T3–4N1M0) or IIIC (any TN2M0).

The TNM classification for carcinomas of the colon and rectum provides more detail than other staging systems. Compatible with the Dukes' system, the TNM adds greater precision in the identification of prognostic subgroups. TNM staging is based on the depth of tumor invasion into the wall of the intestine (T), extension to adjacent structures (T), the number of regional lymph nodes involved (N), and the presence or absence of distant metastasis (M). The TNM classification applies to both clinical and pathologic staging. However, most cancers of the colon or rectum are staged after pathologic examination of the resected specimen. This staging system applies to all carcinomas arising in the colon or rectum. Adenocarcinomas of the vermiform appendix are classified according to the TNM staging system but should be recorded separately, whereas cancers that occur in the anal canal are staged according to the classification used for the anus (see Chapter 13).

### ANATOMY

The divisions of the colon and rectum are as follows:

Cecum  
 Ascending colon  
 Hepatic flexure  
 Transverse colon  
 Splenic flexure  
 Descending colon  
 Sigmoid colon  
 Rectosigmoid junction  
 Rectum

**Primary Site.** The large intestine (colorectum) extends from the terminal ileum to the anal canal. Excluding the rectum and vermiform appendix, the colon is divided into

four parts: the right or ascending colon, the middle or transverse colon, the left or descending colon, and the sigmoid colon. The sigmoid is continuous with the rectum which terminates at the anal canal.

The cecum is a large, blind pouch that arises from the proximal segment of the right colon. It measures 6 cm by 9 cm and is covered with peritoneum. The ascending colon measures 15–20 cm in length. The posterior surface of the ascending (and descending) colon lacks peritoneum and thus is in direct contact with the retroperitoneum. In contrast, the anterior and lateral surfaces of the ascending (and descending) colon have serosa and are intraperitoneal. The hepatic flexure connects the ascending colon with the transverse colon, passing just inferior to the liver and anterior to the duodenum.

The transverse colon is entirely intraperitoneal, supported on a long mesentery that is attached to the pancreas. Anteriorly, its serosa is continuous with the gastrocolic ligament. The splenic flexure connects the transverse colon to the descending colon, passing inferior to the spleen and anterior to the tail of the pancreas. As noted above, the posterior aspect of the descending colon lacks serosa and is in direct contact with the retroperitoneum, whereas the lateral and anterior surfaces have serosa and are intraperitoneal. The descending colon measures 10–15 cm in length. The colon becomes completely intraperitoneal once again at the sigmoid colon, where the mesentery develops at the medial border of the left posterior major psoas muscle and extends to the rectum. The transition from sigmoid colon to rectum is marked by the fusion of the tenia of the sigmoid colon to the circumferential longitudinal muscle of the rectum. This occurs roughly 12–15 cm from the dentate line.

Approximately 12 cm in length, the rectum extends from the fusion of the tenia to the puborectalis ring. The rectum is covered by peritoneum in front and on both sides in its upper third and only on the anterior wall in its middle third. The peritoneum is reflected laterally from the rectum to form the perirectal fossa and, anteriorly, the uterine or rectovesical fold. There is no peritoneal covering in the lower third, which is often known as the rectal ampulla. The anal canal, which measures 3 to 5 cm in length, extends from the puborectalis sling to the anal verge.

**Regional Lymph Nodes.** Regional nodes are located (1) along the course of the major vessels supplying the colon and rectum, (2) along the vascular arcades of the marginal artery, and (3) adjacent to the colon—that is, located along the mesocolic border of the colon. Specifically, the regional lymph nodes are the pericolic and perirectal nodes and those found along the ileocolic, right colic, middle colic, left colic, inferior mesenteric artery, superior rectal (hemorrhoidal), and internal iliac arteries.

For pN, the number of lymph nodes sampled should be recorded. The number of nodes examined from an operative specimen has been reported to be associated with improved survival, possibly because of increased accuracy in staging. It is important to obtain at least 7–14 lymph nodes in radical

colon and rectum resections; however, in cases in which tumor is resected for palliation or in patients who have received preoperative radiation, only a few lymph nodes may be present. A pN0 determination may be assessed when these nodes are histologically negative, even though fewer than the recommended number of nodes have been analyzed.

The regional lymph nodes for each segment of the large bowel are designated as follows:

<i>Segment</i>	<i>Regional Lymph Nodes</i>
Cecum	Pericolic, anterior cecal, posterior cecal, ileocolic, right colic
Ascending colon	Pericolic, ileocolic, right colic, middle colic
Hepatic flexure	Pericolic, middle colic, right colic
Transverse colon	Pericolic, middle colic
Splenic flexure	Pericolic, middle colic, left colic, inferior mesenteric
Descending colon	Pericolic, left colic, inferior mesenteric, sigmoid
Sigmoid colon	Pericolic, inferior mesenteric, superior rectal (hemorrhoidal), sigmoidal, sigmoid mesenteric
Rectosigmoid	Pericolic, perirectal, left colic, sigmoid mesenteric, sigmoidal, inferior mesenteric, superior rectal (hemorrhoidal), middle rectal (hemorrhoidal)
Rectum	Perirectal, sigmoid mesenteric, inferior mesenteric, lateral sacral presacral, internal iliac, sacral promontory (Gerota's), internal iliac, superior rectal (hemorrhoidal), middle rectal (hemorrhoidal), inferior rectal (hemorrhoidal)

**Metastatic Sites.** Although carcinomas of the colon and rectum can metastasize to almost any organ, the liver and lungs are the most common sites. Seeding of other segments of the colon, small intestine, or peritoneum can also occur.

## RULES FOR CLASSIFICATION

**Clinical Staging.** Clinical assessment is based on medical history, physical examination, sigmoidoscopy, and colonoscopy with biopsy. Special examinations designed to demonstrate the presence of extracolonic metastasis, such as chest films, computerized tomography, and PET scans, may be performed.

**Pathologic Staging.** Colorectal cancers are usually staged after surgical exploration of the abdomen and pathologic examination of the resected specimen. The definition of *in situ* carcinoma—pTis—includes cancer cells confined within the glandular basement membrane (intraepithelial) or lamina propria (intramucosal) with no extension through the

muscularis mucosae into the submucosa. Neither intraepithelial nor intramucosal carcinomas of the large intestine have a significant potential for metastasis.

Tumor that invades the stalk of a polyp is classified according to the pT definitions adopted for colorectal carcinomas. For instance, tumor that is limited to the lamina propria is listed as pTis, whereas tumor that has invaded the muscularis mucosae and entered the submucosa of the stalk is classified pT1.

Lymph nodes are classified N1 or N2 according to the number involved with metastatic tumor. Involvement of 1 to 3 nodes is pN1, and the presence of 4 or more nodes involved with tumor metastasis is considered pN2.

Patients with tumor located on the serosal surface as a result of direct extension through the wall of the colon or proximal rectum are assigned T4, as are those with lesions that directly invade other organs or structures. Seeding of abdominal organs—for instance, the distal ileum from a carcinoma of the transverse colon—is considered discontinuous metastasis and should be recorded as M1. Metastatic nodules or foci found in the pericolic or perirectal fat or in adjacent mesentery (mesocolic fat) without evidence of residual lymph node tissue are considered equivalent to regional lymph node metastasis if the nodule has the form and smooth contour of a lymph node. If the nodule has an irregular contour, it should be classified in the T category and also coded as V1 (microscopic venous invasion) or V2 (if it was grossly evident), because of the likelihood that it represents venous invasion. Multiple metastatic foci seen microscopically only in the pericolic fat should be considered lymph node metastases for classification.

Metastasis in the external iliac or common iliac lymph nodes is classified M1.

If the tumor recurs at the site of surgery, it is anatomically assigned to the proximal segment of the anastomosis and restaged by the TNM classification, using the r prefix for the recurrent tumor stage (rTNM).

**Radial Margins.** It is important that accurate pathologic evaluation of the radial margin be performed. The radial margin is that surgically dissected surface adjacent to the deepest point of tumor invasion beyond the wall of the large bowel. The surgeon is encouraged to mark the area of deepest tumor penetration so that the pathologist may most directly evaluate the radial margin. This margin may reflect invasion either through the peritoneum covering the intraabdominal colon in which the lesion was adherent to an unresected structure or organ, or into retroperitoneal or infraperitoneal fat. The completeness of resection is dependent in large part on this radial margin, and the resection (R) codes should be given for each procedure: R0—complete tumor resection with all margins negative; R1—incomplete tumor resection with microscopic involvement of a margin (gross total marginal resection), and R2—incomplete tumor resection with gross residual tumor that was not resected.

## DEFINITION OF TNM

The same classification is used for both clinical and pathologic staging.

### Primary Tumor (T)

TX	Primary tumor cannot be assessed
T0	No evidence of primary tumor
Tis	Carcinoma <i>in situ</i> : intraepithelial or invasion of lamina propria*
T1	Tumor invades submucosa
T2	Tumor invades muscularis propria
T3	Tumor invades through the muscularis propria into the subserosa, or into non-peritonealized pericolic or perirectal tissues
T4	Tumor directly invades other organs or structures, and/or perforates visceral peritoneum**,***

\*Note: Tis includes cancer cells confined within the glandular basement membrane (intraepithelial) or lamina propria (intramucosal) with no extension through the muscularis mucosae into the submucosa.

\*\*Note: Direct invasion in T4 includes invasion of other segments of the colorectum by way of the serosa; for example, invasion of the sigmoid colon by a carcinoma of the cecum.

\*\*\*Tumor that is adherent to other organs or structures, macroscopically, is classified T4. However, if no tumor is present in the adhesion, microscopically, the classification should be pT3. The V and L substaging should be used to identify the presence or absence of vascular or lymphatic invasion.

### Regional Lymph Nodes (N)

NX	Regional lymph nodes cannot be assessed
N0	No regional lymph node metastasis
N1	Metastasis in 1 to 3 regional lymph nodes
N2	Metastasis in 4 or more regional lymph nodes

Note: A tumor nodule in the pericorectal adipose tissue of a primary carcinoma without histologic evidence of residual lymph node in the nodule is classified in the pN category as a regional lymph node metastasis if the nodule has the form and smooth contour of a lymph node. If the nodule has an irregular contour, it should be classified in the T category and also coded as V1 (microscopic venous invasion) or as V2 (if it was grossly evident), because there is a strong likelihood that it represents venous invasion.

### Distant Metastasis (M)

MX	Distant metastasis cannot be assessed
M0	No distant metastasis
M1	Distant metastasis

## STAGE GROUPING

Stage	T	N	M	Dukes*	MAC*
0	Tis	N0	M0	-	-
I	T1	N0	M0	A	A
	T2	N0	M0	A	B1
IIA	T3	N0	M0	B	B2
IIB	T4	N0	M0	B	B3
IIIA	T1-T2	N1	M0	C	C1
IIIB	T3-T4	N1	M0	C	C2/C3
IIIC	Any T	N2	M0	C	C1/C2/C3
IV	Any T	Any N	M1	-	D

\*Dukes B is a composite of better (T3 N0 M0) and worse (T4 N0 M0) prognostic groups, as is Dukes C (Any TN1 M0 and Any T N2 M0). MAC is the modified Astler-Coller classification.

Note: The y prefix is to be used for those cancers that are classified after pretreatment, whereas the r prefix is to be used for those cancers that have recurred.

## HISTOPATHOLOGIC TYPE

This staging classification applies to carcinomas that arise in the colon or rectum. The classification does not apply to sarcomas, to lymphomas, or to carcinoid tumors of the large intestine or appendix. The histologic types include:

Adenocarcinoma *in situ*\*

Adenocarcinoma

Medullary carcinoma

Mucinous carcinoma (colloid type) (greater than 50% mucinous carcinoma)

Signet ring cell carcinoma (greater than 50% signet ring cell)

Squamous cell (epidermoid) carcinoma

Adenosquamous carcinoma

Small cell carcinoma

Undifferentiated carcinoma

Carcinoma, NOS

\*The terms "high grade dysplasia" and "severe dysplasia" may be used as synonyms for *in situ* adenocarcinoma and *in situ* carcinoma. These cases should be assigned pTis.

## HISTOLOGIC GRADE (G)

GX Grade cannot be assessed

G1 Well differentiated

G2 Moderately differentiated

G3 Poorly differentiated

G4 Undifferentiated

It is recommended that the terms "low-grade" (G1–G2) and "high-grade" (G3–G4) be applied, because data indicate that low and high grade may be associated with outcome independently of TNM stage group for both colon and rectum adenocarcinoma. Some authors suggest that G4 lesions be identified separately because they may represent a small subgroup of carcinomas that are very aggressive.

## RESIDUAL TUMOR (R)

R0 Complete resection, margins histologically negative, no residual tumor left after resection

R1 Incomplete resection, margins histologically involved, microscopic tumor remains after resection of gross disease

R2 Incomplete resection, margins involved or gross disease remains after resection

## PROGNOSTIC FACTORS

In addition to the TNM, independent prognostic factors that are generally used in patient management and are well supported in the literature include residual disease, histologic type, histologic grade, serum carcinoembryonic antigen and cytokine levels, extramural venous invasion, and submucosal vascular invasion by carcinomas arising in adenomas. Small cell carcinomas, signet ring cell carcinomas, and undifferentiated carcinomas have a less favorable outcome than other histologic types. Submucosal vascular invasion by carcinomas arising in adenomas is associated with a greater risk of regional lymph node involvement. In the future, the intratumoral expression of specific molecules (e.g., Deleted in Colorectal Cancer (DCC), p27<sup>Kip1</sup>, DNA microsatellite instability, thymidylate synthase) may be proven to be associated either with prognosis or response to therapy and yet be independent of TNM stage group or histologic grade. These molecular markers are currently not part of the staging system, but it is recommended that they be recorded if available and studied within the context of a clinical trial.

## BIBLIOGRAPHY

Adam JJ, Mohamdee MO, Martin IG, et al: Role of circumferential margin involvement in the local recurrence of rectal cancer. *Lancet* 344:707–711, 1994

Astler VB, Collier FA: The prognostic significance of direct extension of carcinoma of the colon and rectum. *Ann Surg* 139:846–852, 1954

Bast RC, Desch CE, Ravdin P, et al: Clinical practice guidelines for the use of tumor markers in breast and colorectal cancer: report of the American Society of Clinical Oncology Expert Panel. *J Clin Oncol* 14:2843–2877, 1996

Bauer K, Bagwell C, Giaretti W, et al: Consensus review of the clinical utility of DNA flow cytometry in colorectal cancer. *Cytometry* 14:486–491, 1993

Belluco C, Esposito G, Bertorelle R, et al: Absence of the cell cycle inhibitor p27Kip1 protein predicts poor outcome in

patients with stage I-III colorectal cancer. *Ann Surg Oncol* 6:19-25, 1999

Belluco C, Frantz M, Carnio S, et al: IL-6 blood level is associated with circulating CEA and prognosis in patients with colorectal cancer. *Ann Surg Oncol* 7:133-138, 2000

Butch RJ, Stark DD, Wittenberg J, et al: Staging rectal cancer by MR and CT. *Am J Roentgenol* 146:1155-1160, 1986

Caplin S, Cerottini JP, Bosman FT, et al: For patients with Dukes' B (TNM Stage II) colorectal carcinoma, examination of six or fewer lymph nodes is related to poor prognosis. *Cancer* 83:666-672, 1998

Chapuis PH, Fisher R, Dent DF, et al: The relationship between different staging methods and survival in colorectal carcinoma. *Dis Colon Rectum* 28:158-161, 1985

Coia LR, Gunderson LL, Haller D, et al: Outcomes of patients receiving radiation for carcinoma of the rectum. Results of the 1988-1989 patterns of care study. *Cancer* 86:1952-1958, 1999

Compton CC: Updated protocol for the examination of specimens removed from patients with colorectal carcinoma. *Arch Pathol Lab Med* 124:1016-1025, 2000

Compton CC, Fenoglio-Prieser CM, Pettigrew N, Fielding LP: American Joint Committee on Cancer Prognostic Factors Consensus Conference: Colorectal Working Group. *Cancer* 88:1739-1757, 2000

Compton CC, Fielding LP, Burgart LJ, et al: Prognostic factors in colorectal cancer: College of American Pathologists Consensus Statement 1999. *Arch Pathol Lab Med* 124:979-994, 2000

Copeland EM, Miller LD, Jones RS: Prognostic factors in carcinoma of the colon and rectum. *Am J Surg* 116:875-881, 1968

Dukes CE: Cancer of the rectum: an analysis of 1000 cases. *J Pathol Bacteriol* 50:527-539, 1940

Fenoglio-Prieser CM, Hutter RVP: Colorectal polyps: pathologic diagnosis and clinical significance. *Cancer J Clin* 35:322-344, 1985

Fielding LP, Arsenault PA, Chapuis PH, et al: Clinicopathological staging for colorectal cancer: an International Documentation System (IDS) and an International Comprehensive Anatomical Terminology (ICAT). *Gastroenterol Hepatol* 6:325-344, 1991

Fielding LP, Pettigrew N: College of American Pathologists Conference XXVI on clinical relevance of prognostic markers in solid tumors: report of the Colorectal Working Group. *Arch Pathol Lab Med* 119:1115-1121, 1995

Fielding LP, Phillips RK, Frey JS, et al: The prediction of outcome after curative resection for large bowel cancer. *Lancet* 2:904-907, 1986

Fielding LP, Phillips RK, Hittinger R: Factors influencing mortality after curative resection for large bowel cancer in elderly patients. *Lancet* 1:595-597, 1989

Gilbert SG: Symptomatic local tumor failure following abdomino-perineal resection. *Int J Radiat Oncol Biol Phys* 4:801-807, 1978

Goldstein NS, Turner JR: Pericolonic tumor deposits in patients with T3N+M0 colon adenocarcinomas: a marker for reduced disease-free survival and intra-abdominal metastasis. *Cancer* 88:2228-2238, 2000

Griffin MR, Bergstralh EJ, Coffey RJ, et al: Predictors of survival after curative resection of carcinoma of the colon and rectum. *Cancer* 60:2318-2324, 1987

Gunderson LL, Sosin H: Areas of failure found at reoperation (second or symptomatic look) following "curative surgery" for adenocarcinoma of the rectum. Clinicopathologic correlation and implications for adjuvant therapy. *Cancer* 34:1278-1292, 1974

Hall NR, Finan PJ, al-Jaberi T, et al: Circumferential margin involvement after mesorectal excision of rectal cancer with curative intent: predictor of survival but not local recurrence? *Dis Colon Rectum* 41:979-983, 1998

Halling KC, French AJ, McDonnell SK, et al: Microsatellite imbalance in stage B2 and C colorectal cancers. *J Natl Cancer Inst* 91:1295-1303, 1999

Harrison JC, Dean PJ, El-Zeky F, Vander Zwaag R: From Dukes through Jass. Pathological prognostic indicators in rectal cancer. *Hum Pathol* 25:498-505, 1994

Harrison JC, Dean PJ, El-Zeky F, Vander Zwaag R: Impact of the Crohn's-like lymphoid reaction on staging of right-sided colon cancer: results of a multivariate analysis. *Hum Pathol* 26:31-38, 1995

Hermanek P: Colorectal carcinoma. Histopathological diagnosis and staging. *Baillieres Clin Gastroenterol* 3:511-529, 1989

Hermanek P: Problems of pTNM classification of carcinoma of the stomach, colorectum and anal margin. *Pathol Res Pract* 181:296-300, 1986

Hermanek P, Gall FP: Early (microinvasive) colorectal carcinoma: pathology, diagnosis, surgical treatment. *Int J Colorectal Dis* 1:79-84, 1986

Hermanek P, Giedl J, Dworak O: Two programs for examination of regional lymph nodes in colorectal carcinoma with regard to the new pN classification. *Pathol Res Pract* 185:867-873, 1989

Hermanek P, Guggenmoos-Holzmann I, Gall FP: Prognostic factors in rectal carcinoma: a contribution to the further development of tumor classification. *Dis Colon Rectum* 32:593-599, 1989

Hermanek P, Henson DE, Hutter RVP, Sobin LH: TNM Supplement 1993: a commentary on uniform use. Berlin: Springer-Verlag, 1993

Hermanek P, Sobin LH: Colorectal carcinoma. In Hermanek P, Gospodarowicz MK, Henson DE, et al (Eds.): Prognostic factors in cancer. Berlin: Springer-Verlag, 1995

Herrera-Ornelas L, Justiniano J, Castillo N, et al: Metastases in small lymph nodes from colon cancer. *Arch Surg* 122:1253-1256, 1987

Hoskins RB, Gunderson LL, Dosoretz DE, et al: Adjuvant post-operative radiotherapy in carcinoma of the rectum and rectosigmoid. *Cancer* 55:61-71, 1985

Jass JR, Atkin WS, Cuzick J, et al: The grading of rectal cancer: historical perspectives and a multivariate analysis of 447 cases. *Histopathology* 10:437-459, 1986

Jass JR, Love SB, Northover JMA: A new prognostic classification of rectal cancer. *Lancet* 1:1303-1306, 1987

Jass JR, Mukawa K, Goh HS, et al: Clinical importance of DNA content in rectal cancer measured by flow cytometry. *J Clin Pathol* 42:254-259, 1989

Jass JR, Sobin LH: Histological typing of intestinal tumours. In WHO international histological classification of tumours, 2nd ed. Berlin-New York: Springer-Verlag, 1989

Jen J, Kim H, Piantadosi S, et al: Allelic loss of chromosome 18q and prognosis in colorectal cancer. *N Eng J Med* 331:213-221, 1994

- Kokal W, Sheibani K, Terz J, et al: Tumor DNA content in the prognosis of colorectal carcinoma. *JAMA* 255:3123–3127, 1986
- Kotanagi H, Fukuoka T, Shibata Y, et al: Blood vessel invasions in metastatic nodes for development of liver metastasis in colorectal cancer. *Hepato-Gastroenterol* 42:771–774, 1995
- Lindmark G, Gerdin B, Sundberg C, et al: Prognostic significance of the microvascular count in colorectal cancer. *J Clin Oncol* 14:461–466, 1996
- Lipper S, Kahn LB, Ackerman LV: The significance of microscopic invasive cancer in endoscopically removed polyps of the large bowel: a clinicopathologic study of 51 cases. *Cancer* 52:1691, 1983
- Loda M, Cukor B, Tam SW, et al: Increased proteasome-dependent degradation of the cyclin-dependent kinase inhibitor p27 in aggressive colorectal carcinomas. *Nature Medicine* 3:231–234, 1997
- Minsky BD, Mies C, Rich TA, et al: Lymphatic vessel invasion is an independent prognostic factor for survival in colorectal cancer. *Int J Radiat Oncol* 17:311–318, 1989
- Newland RC, Chapuis PH, Pheils MT, et al: The relationship of survival to staging and grading of colorectal carcinoma: a prospective study of 503 cases. *Cancer* 47:1424–1429, 1981
- Ondero H, Maetani S, Nishikawa T, et al: The reappraisal of prognostic classifications for colorectal cancer. *Dis Colon Rectum* 32:609–614, 1989
- Phillips RKS, Hittinger R, Blesovsky L, et al: Large bowel cancer: surgical pathology and its relationship to survival. *Br J Surg* 71:604–610, 1984
- Pocard M, Panis Y, Malassagne B, et al: Assessing the effectiveness of mesorectal excision in rectal cancer: prognostic value of the number of lymph nodes found in resected specimens. *Dis Colon Rectum* 41:839–845, 1998
- Qizilbash AH: Pathologic studies in colorectal cancer: a guide to the surgical pathology examination of colorectal specimens and review of features of prognostic significance. *Pathol Annu* 17(1):1–46, 1982
- Ratto C, Sofo L, Ippoliti M, et al: Accurate lymph-node detection in colorectal specimens resected for cancer is of prognostic significance. *Dis Colon Rectum* 42:143–154, 1999
- Rich T, Gunderson LL, Lew R, et al: Patterns of recurrence of rectal cancer after potentially curative surgery. *Cancer* 52:1317–1329, 1983
- Schild SE, Martenson JA Jr, Gunderson LL, et al: Postoperative adjuvant therapy of rectal cancer: an analysis of disease control, survival, and prognostic factors. *Int J Radiat Oncol Biol Phys.* 17:55–62, 1989
- Scott KWM, Grace RH: Detection of lymph node metastases in colorectal carcinoma before and after fat clearance. *Br J Surg* 76:1165–1167, 1989
- Scott NA, Rainwater LM, Wieland HS, et al: The relative prognostic value of flow cytometric DNA analysis and conventional clinicopathologic criteria in patients with operative rectal carcinoma. *Dis Colon Rectum* 30:513–520, 1987
- Shepherd NA, Saraga EP, Love SB, et al: Prognostic factors in colonic cancer. *Histopathology* 14:613–620, 1989
- Shibata D, Reale MA, Lavin P, et al: The DCC protein and prognosis in colorectal cancer. *N Engl J Med* 335:1727–1732, 1996
- Steinberg SM, Barkin JS, Kaplan RS, et al: Prognostic indicators of colon tumors: the gastrointestinal tumor study group experience. *Cancer* 57:1866–1870, 1986
- Talbot IC, Ritchie S, Leighton MH, et al: The clinical significance of invasion of veins by rectal cancer. *Br J Surg* 67:439–442, 1980
- Talbot IC, Ritchie S, Leighton MH, et al: Spread of rectal cancer within veins: histologic features and clinical significance. *Am J Surg* 141:15–17, 1981
- Tepper JE, Cohen AM, Wood WC, et al: Postoperative radiation therapy of rectal cancer. *Int J Radiat Oncol Biol Phys* 13:5–10, 1987
- Tepper JE, O'Connell MJ, Niedzwiecki D, et al: Impact of number of nodes retrieved on outcome in patients with rectal cancer. *J Clin Oncol* 19:157–163, 2001
- Willett CG, Tepper JE, Kaufman DS, et al: Adjuvant postoperative radiation therapy for rectal adenocarcinoma. *Am J Clin Oncol* 15:371–375, 1992
- Williams NS, Durdey P, Qwihe P, et al: Pre-operative staging of rectal neoplasm and its impact on clinical management. *Br J Surg* 72:868–874, 1985
- Wolmark N, Fisher B, Wieand HS: The prognostic value of the modifications of the Dukes C class of colorectal cancer: an analysis of the NSABP clinical trials. *Ann Surg* 203:115–122, 1986
- Wolmark N, Fisher ER, Wieand HS, et al: The relationship of depth of penetration and tumor size to the number of positive nodes in Dukes C colorectal cancer. *Cancer* 53:2707–2712, 1984
- Wong JH, Severino R, Honnebler MB, et al: Number of nodes examined and staging accuracy in colorectal carcinoma. *J Clin Oncol* 17:2896–2900, 1999
- Wright CM, Dent OF, Barker M, et al: Prognostic significance of extensive microsatellite instability in sporadic clinicopathological stage C colorectal cancer. *Brit J Surg* 87:1197–1202, 2000

## HISTOLOGIES—COLON AND RECTUM

8000/3	Neoplasm, malignant
8001/3	Tumor cells, malignant
8002/3	Malignant tumor, small cell type
8004/3	Malignant tumor, spindle cell type
8005/3	Malignant tumor, clear cell type
8010/2	Carcinoma <i>in situ</i> , NOS
8010/3	Carcinoma, NOS
8012/3	Large cell carcinoma, NOS
8013/3	Large cell neuroendocrine carcinoma
8020/3	Carcinoma, undifferentiated, NOS
8021/3	Carcinoma, anaplastic, NOS
8032/3	Spindle cell carcinoma, NOS
8041/3	Small cell carcinoma, NOS
8042/3	Oat cell carcinoma
8043/3	Small cell carcinoma, fusiform cell
8044/3	Small cell carcinoma, intermediate cell
8045/3	Combined small cell carcinoma
8050/3	Papillary carcinoma
8070/3	Squamous cell carcinoma, NOS
8140/2	Adenocarcinoma <i>in situ</i> , NOS
8140/3	Adenocarcinoma, NOS
8141/3	Scirrhous adenocarcinoma
8210/2	Adenocarcinoma <i>in situ</i> in adenomatous polyp
8210/3	Adenocarcinoma in adenomatous polyp
8211/3	Tubular adenocarcinoma
8214/3	Parietal cell carcinoma



**HISTOLOGIES—COLON AND RECTUM (CONT.)**

8215/3	Adenocarcinoma of anal glands	8262/3	Villous adenocarcinoma
8220/3	Adenocarcinoma in adenomatous polyposis coli	8263/2	Adenocarcinoma <i>in situ</i> in tubulovillous adenoma
8221/3	Adenocarcinoma in multiple adenomatous polyps	8263/3	Adenocarcinoma in tubulovillous adenoma
8230/2	Ductal carcinoma <i>in situ</i> , solid type	8480/3	Mucinous adenocarcinoma
8230/3	Solid carcinoma, NOS	8481/3	Mucin-producing adenocarcinoma
8240/3	Carcinoid tumor, NOS	8490/3	Signet ring cell carcinoma
8244/3	Composite carcinoid	8510/3	Medullary carcinoma, NOS
8245/3	Adenocarcinoid tumor	8560/3	Adenosquamous carcinoma
8246/3	Neuroendocrine carcinoma, NOS	8570/3	Adenocarcinoma with squamous metaplasia
8249/3	Atypical carcinoid tumor	8571/3	Adenocarcinoma with cartilaginous and osseous metaplasia
8261/2	Adenocarcinoma <i>in situ</i> in villous adenoma	8935/3	Stromal sarcoma, NOS
8261/3	Adenocarcinoma in villous adenoma	8936/3	Gastrointestinal stromal sarcoma

## COLON AND RECTUM

<b>Hospital Name/Address</b>
------------------------------

<b>Patient Name/Information</b>
---------------------------------

Type of Specimen \_\_\_\_\_

Histopathologic Type \_\_\_\_\_

Tumor Size \_\_\_\_\_

### DEFINITIONS

Clinical	Pathologic	Primary Tumor (T)	
<input type="checkbox"/>	<input type="checkbox"/>	TX	Primary tumor cannot be assessed
<input type="checkbox"/>	<input type="checkbox"/>	T0	No evidence of primary tumor
<input type="checkbox"/>	<input type="checkbox"/>	Tis	Carcinoma <i>in situ</i> : intraepithelial or invasion of lamina propria <sup>(1-3)</sup>
<input type="checkbox"/>	<input type="checkbox"/>	T1	Tumor invades submucosa
<input type="checkbox"/>	<input type="checkbox"/>	T2	Tumor invades muscularis propria
<input type="checkbox"/>	<input type="checkbox"/>	T3	Tumor invades through the muscularis propria into the subserosa, or into non-peritonealized pericolic or perirectal tissues
<input type="checkbox"/>	<input type="checkbox"/>	T4	Tumor directly invades other organs or structures, and/or perforates visceral peritoneum <sup>(2-3)</sup>

Clinical	Pathologic	Regional Lymph Nodes (N)	
<input type="checkbox"/>	<input type="checkbox"/>	NX	Regional lymph nodes cannot be assessed <sup>(4)</sup>
<input type="checkbox"/>	<input type="checkbox"/>	N0	No regional lymph node metastasis
<input type="checkbox"/>	<input type="checkbox"/>	N1	Metastasis in 1 to 3 regional lymph nodes
<input type="checkbox"/>	<input type="checkbox"/>	N2	Metastasis in 4 or more regional lymph nodes

Clinical	Pathologic	Distant Metastasis (M)	
<input type="checkbox"/>	<input type="checkbox"/>	MX	Distant metastasis cannot be assessed
<input type="checkbox"/>	<input type="checkbox"/>	M0	No distant metastasis
<input type="checkbox"/>	<input type="checkbox"/>	M1	Distant metastasis

Biopsy of metastatic site performed..... Y ..... N

Source of pathologic metastatic specimen \_\_\_\_\_

Clinical	Pathologic	Stage Grouping						
Stage	T	N	M	Dukes	MAC			
<input type="checkbox"/>	<input type="checkbox"/>	0	Tis	N0	M0	-	-	
<input type="checkbox"/>	<input type="checkbox"/>	I	T1	N0	M0	A	A	
<input type="checkbox"/>	<input type="checkbox"/>		T2	N0	M0	A	B1	
<input type="checkbox"/>	<input type="checkbox"/>	IIA	T3	N0	M0	B	B2	
<input type="checkbox"/>	<input type="checkbox"/>	IIB	T4	N0	M0	B	B3	
<input type="checkbox"/>	<input type="checkbox"/>	IIIA	T1-T2	N1	M0	C	C1	
<input type="checkbox"/>	<input type="checkbox"/>	IIIB	T3-T4	N1	M0	C	C2/C3	
<input type="checkbox"/>	<input type="checkbox"/>	IIIC	Any T	N2	M0	C	C1/C2/C3	
<input type="checkbox"/>	<input type="checkbox"/>	IV	Any T	Any N	M1	-	D	

### Notes

1. Tis includes cancer cells confined within the glandular basement membrane (intraepithelial) or lamina propria (intramucosal) with no extension through the muscularis mucosae into the submucosa.

2. Direct invasion in T4 includes invasion of other segments of the colorectum by way of the serosa; for example, invasion of the sigmoid colon by a carcinoma of the cecum.

3. Tumor that is adherent to other organs or structures, macroscopically, is classified T4. However, if no tumor is present in the adhesion, microscopically, the classification should be pT3. The V and L substaging should be used to identify the presence or absence of vascular or lymphatic invasion.

4. A tumor nodule in the pericolic/rectal adipose tissue of a primary carcinoma without histologic evidence of residual lymph node in the nodule is classified in the pN category as a regional lymph node metastasis if the nodule has the form and smooth contour of a lymph node. If the nodule has an irregular contour, it should be classified in the T category and also coded as V1 (microscopic venous invasion) or as V2 (if it was grossly evident), because there is a strong likelihood that it represents venous invasion.

(continued on reverse side)

**Histologic Grade (G)**

- GX Grade cannot be assessed
- G1 Well differentiated
- G2 Moderately differentiated
- G3 Poorly differentiated
- G4 Undifferentiated

**Residual Tumor (R)**

- R0 Complete resection, margins histologically negative, no residual tumor left after resection
- R1 Incomplete resection, margins histologically involved, microscopic tumor remains after resection of gross disease
- R2 Incomplete resection, margins involved or gross disease remains after subtotal resection

**Additional Descriptors**

For identification of special cases of TNM or pTNM classifications, the "m" suffix and "y," "r," and "a" prefixes are used. Although they do not affect the stage grouping, they indicate cases needing separate analysis.

**m suffix** indicates the presence of multiple primary tumors in a single site and is recorded in parentheses: pT(m)NM.

**y prefix** indicates those cases in which classification is performed during or following initial multimodality therapy. The cTNM or pTNM category is identified by a "y" prefix. The ycTNM or ypTNM categorizes the extent of tumor actually present at the time of that examination. The "y" categorization is not an estimate of tumor prior to multimodality therapy.

**r prefix** indicates a recurrent tumor when staged after a disease-free interval, and is identified by the "r" prefix: rTNM.

**a prefix** designates the stage determined at autopsy: aTNM.

**Prognostic Indicators**

For CRC

CEA level: \_\_\_\_\_ ng/ml

**Notes**

**Additional Descriptors**

**Lymphatic Vessel Invasion (L)**

LX Lymphatic vessel invasion cannot be assessed

L0 No lymphatic vessel invasion

L1 Lymphatic vessel invasion

**Venous Invasion (V)**

VX Venous invasion cannot be assessed

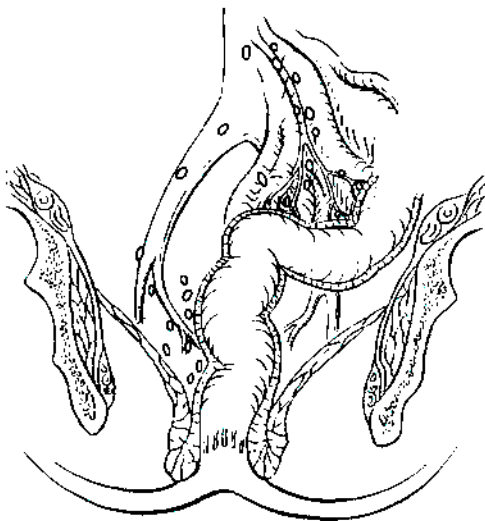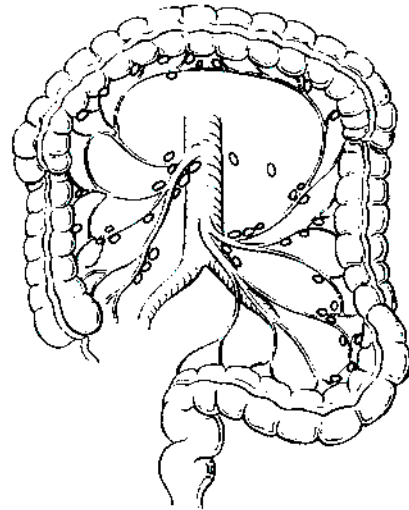
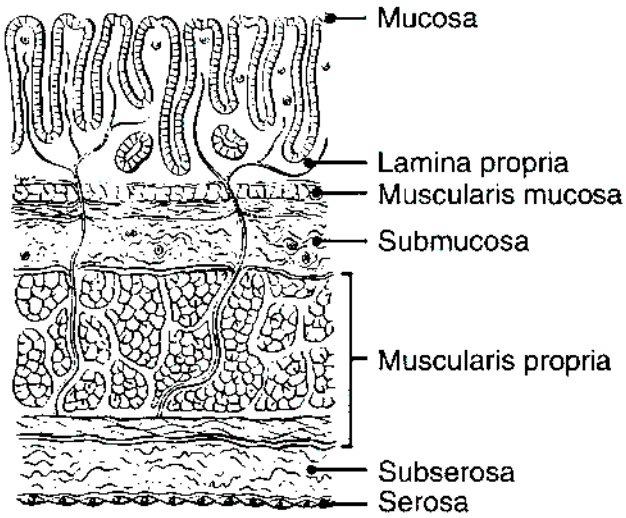
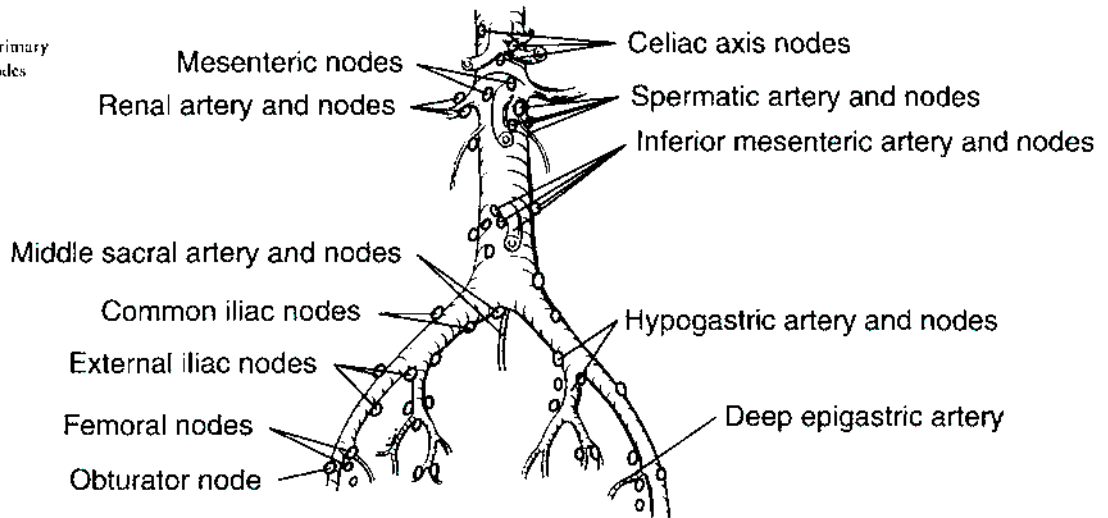
V0 No venous invasion

V1 Microscopic venous invasion

V2 Macroscopic venous invasion

**ILLUSTRATION**

Indicate on diagram primary tumor and regional nodes involved.



Physician's Signature \_\_\_\_\_ Date \_\_\_\_\_

## Anal Canal

*(The classification applies to carcinomas only; melanomas, carcinoid tumors, and sarcomas are not included.)*

C21.0 Anus, NOS  
C21.1 Anal canal

C21.2 Cloacogenic zone

C21.8 Overlapping lesion of rectum, anus, and anal canal

### SUMMARY OF CHANGES

- The definition of TNM and the Stage Grouping for this chapter have not changed from the Fifth Edition.

### INTRODUCTION

The proximal region of the anus encompasses true mucosa of three different histologic types: glandular, transitional, and squamous (proximal to distal, respectively). Distally, the squamous mucosa merges with the perianal skin (true epidermis). This mucocutaneous junction historically has been called the anal verge or margin. Thus, two distinct categories of tumors arise in the anal region. Tumors that develop from mucosa (of any of the three types) are termed anal canal cancers, whereas those that arise within skin at or distal to the squamous mucocutaneous junction are termed anal margin tumors. The proximal boundary of the anal margin is indistinct on macroscopic examination and, anatomically, may vary with the patient's body habitus. A proximal boundary located 5–6 cm from the squamous mucocutaneous junction applies in the majority of adults.

Anal canal tumors are staged using the classification system described herein. Anal margin tumors are biologically comparable to other skin tumors and therefore are classified by the schema presented in Chapter 23. However, the regional nodal drainage (relevant to the N category) of the skin of the anal margin is uniquely specific to this anatomic site, as outlined in this section.

Because the primary management of carcinomas of the anal canal has shifted from surgical resection to non-surgical treatment, they are typically staged clinically according to the size and extent of the primary tumor. Thus, patients with cancer of the anal canal may be staged at the time of presentation by inspection, palpation and biopsy of the mass, palpation (and biopsy as needed) of regional lymph nodes, and radiologic imaging of chest, abdomen, and pelvis.

### ANATOMY

**Primary site.** The anal canal begins where the rectum enters the puborectalis sling at the apex of the anal sphincter complex (palpable as the anorectal ring on digital exam) and ends at the squamous mucocutaneous junction with the perianal skin. The most proximal aspect of the anal canal is lined by colorectal mucosa, and at the dentate line, a narrow zone of transitional mucosa that is similar to urothelium is variably present. This proximal zone (from the top of the puborectalis to the dentate line, including the transitional zone) measures approximately 1–2 cm. In the region of the dentate line, anal glands may be found subjacent to the mucosa, often extending across the internal sphincter to the intersphincteric plane. A proximal boundary located distal to the dentate line and extending to the mucocutaneous junction is a non-keratinizing squamous epithelium devoid of skin appendages (hair follicles, apocrine glands, and sweat glands).

Carcinomas that overlap the anorectal junction may be problematic. They should be staged as rectal tumors if their epicenter is located more than 2 cm proximal to the dentate line and as anal tumors if their epicenter is 2 cm or less from the dentate line. However, extension of low rectal tumors beyond the dentate line implies risk of metastatic spread to the superficial inguinal lymph nodes.

**Regional Lymph Nodes.** Lymphatic drainage and nodal involvement of anal cancers depend on the location of the primary tumor. Tumors above the dentate line spread primarily to the anorectal, perirectal, and paravertebral nodes, whereas tumors below the dentate line spread to the superficial inguinal nodes.

The regional lymph nodes are as follows:

- Perirectal
  - Anorectal
  - Perirectal
  - Lateral sacral
- Internal iliac (hyogastric)
- Inguinal
  - Superficial
  - Deep femoral

All other nodal groups represent sites of distant metastasis.

**Metastatic Sites.** Cancers of the anus may metastasize to any organs, but the liver and lungs are the distal organs that are most frequently involved. Involvement of the abdominal cavity is not unusual.

## RULES FOR CLASSIFICATION

**Clinical Staging.** The TNM classification for tumors of the anal canal depends largely on clinical observations. The primary tumor is staged according to its greatest dimension and local extent as determined by clinical and/or pathologic examination. Palpation and radiologic imaging assess extension to the anorectal, perirectal, and superficial inguinal or femoral nodes, as well as to adjacent structures. Metastasis to other nodal groups, such as the inferior mesenteric, may also be assessed radiologically. Tumor may extend to the rectal mucosa or submucosa, subcutaneous perianal tissue, perianal skin, ischioanal fat, and/or local skeletal muscles, such as the external anal sphincter, levator ani, and coccygeus muscles. **Local extension** of tumor may also include the perineum, vulva, prostate gland, urinary bladder, urethra, vagina, cervix uteri, corpus uteri, pelvic peritoneum, and broad ligaments. Organs invaded by tumor should be specified.

**Pathologic Staging.** Surgical excision is infrequently performed for anal carcinoma, so few tumors are staged pathologically. The size of the tumor is assessed by macroscopic examination and confirmed microscopically. Accurate assessment of the involvement of local structures or organs may require specific orientation of the specimen or other identification by the surgeon. Perirectal lymph nodes may be identified within the surgical specimen on pathologic examination, but specific identification of internal iliac and inguinal lymph nodes by the surgeon is required.

## DEFINITION OF TNM

### Primary Tumor (T)

- TX Primary tumor cannot be assessed
- T0 No evidence of primary tumor
- Tis Carcinoma *in situ*
- T1 Tumor 2 cm or less in greatest dimension
- T2 Tumor more than 2 cm but not more than 5 cm in greatest dimension

- T3 Tumor more than 5 cm in greatest dimension
- T4 Tumor of any size invades adjacent organ(s), e.g., vagina, urethra, bladder\*

\*Note: Direct invasion of the rectal wall, perirectal skin, subcutaneous tissue, or the sphincter muscle(s) is not classified as T4.

### Regional Lymph Nodes (N)

- NX Regional lymph nodes cannot be assessed
- N0 No regional lymph node metastasis
- N1 Metastasis in perirectal lymph node(s)
- N2 Metastasis in unilateral internal iliac and/or inguinal lymph node(s)
- N3 Metastasis in perirectal and inguinal lymph nodes and/or bilateral internal iliac and/or inguinal lymph nodes

### Distant Metastasis (M)

- MX Distant metastasis cannot be assessed
- M0 No distant metastasis
- M1 Distant metastasis

## STAGE GROUPING

Stage 0	Tis	N0	M0
Stage I	T1	N0	M0
Stage II	T2	N0	M0
	T3	N0	M0
Stage IIIA	T1	N1	M0
	T2	N1	M0
	T3	N1	M0
	T4	N0	M0
Stage IIIB	T4	N1	M0
	Any T	N2	M0
	Any T	N3	M0
Stage IV	Any T	Any N	M1

## HISTOPATHOLOGIC TYPE

The staging system applies to all carcinomas arising in the anal canal, including carcinomas that arise within anorectal fistulas. Melanomas, carcinoid tumors, and sarcomas are excluded from this staging system. Most carcinomas of the anal canal are squamous cell carcinomas. The WHO classification of the types and subtypes of carcinomas of the anal canal is shown below. The terms *transitional cell* and *cloacogenic carcinoma* have been abandoned, because these tumors are now recognized as non-keratinizing types of squamous cell carcinoma.

## WHO Classification of Carcinoma of the Anal Canal\*

- Squamous cell carcinoma
- Adenocarcinoma
  - Rectal type
  - Of anal glands
  - Within anorectal fistula
- Mucinous adenocarcinoma
- Small cell carcinoma
- Undifferentiated carcinoma

\*Note: The term *carcinoma, NOS* (not otherwise specified) is not part of the WHO classification.

Perianal skin and anal margin (junction of squamous mucosa and skin) tumor types include squamous cell carcinoma, giant condyloma (verrucous carcinoma), basal cell carcinoma, Bowen's disease, and Paget's disease. These tumors are staged as skin cancers according to the system outlined in Chapter 23.

## HISTOLOGIC GRADE (G)

- GX Grade cannot be assessed
- G1 Well differentiated
- G2 Moderately differentiated
- G3 Poorly differentiated
- G4 Undifferentiated

## PROGNOSTIC FACTORS

Because of the infrequent occurrence of carcinomas of the anal canal, the definitive identification of prognostic factors is problematic. However, poor histologic grade or histologic types that are categorized by convention as high-grade, such as small cell carcinoma, have been shown to be adverse prognostic factors.

## BIBLIOGRAPHY

- Boman BM, Moertel CG, O'Connell MJ, et al: Carcinoma of the anal canal: a clinical and pathologic study of 188 cases. *Cancer* 54:114–125, 1984
- Cummings BJ: Anal canal carcinoma. In Hermanek P, Gospodarowicz MK, Henson DE, et al (Eds.): *Prognostic factors in cancer*. Berlin: Springer-Verlag, 1995
- Dean GT, McAleer JJA, Spence RAJ: Malignant anal tumors. *Br J Surg* 81:500–508, 1994
- Fenger C, Frisch M, Marti MC, Parc R: Tumors of the anal canal. In Hamilton SR, Aaltonen LA (Eds): *World Health Organization classification of tumors: pathology and genetics of tumors of the digestive system*. Lyon: IARC Press, 146, 2000
- Flam MS, John M, Lovalvo LJ, et al: Definitive nonsurgical therapy of epithelial malignancies of the anal canal. *Cancer* 51:1378–1387, 1983
- Longo WE, Vernava AM III, Wade TP, et al: Recurrent squamous cell carcinoma of the anal canal: predictors of initial

treatment failure and results of salvage therapy. *Ann Surg* 220:40–49, 1994

- Nigro ND: An evaluation of combined therapy for squamous cell cancer of the anal canal. *Dis Colon Rectum* 27:763–766, 1984
- Nigro ND, Vaitkevicius VK, Herskovic AM: Preservation of function in the treatment of cancer of the anus. *Important Adv Oncol* 161–177, 1989
- Paradis P, Douglass HO Jr, Holyoke ED: The clinical implications of a staging system for carcinoma of the anus. *Surg Gynecol Obstet* 141:411–416, 1975
- Pintor MP, Northover JM, Nicholls RJ: Squamous cell carcinoma of the anus at one hospital from 1948. *Br J Surg* 76:806–810, 1989
- Roseau G, Palazzo L, Colardelle P, et al: Endoscopic ultrasonography in the staging and follow-up of epidermoid carcinoma of the anal canal. *Gastrointest Endosc* 40:447–450, 1994
- Ryan DP, Compton CC, Mayer RJ: Carcinoma of the anal canal. *NEJM* 342(11):792–800, 2000
- Shepherd NA, Scholefield JH, Love SB, et al: Prognostic factors in anal squamous carcinoma: a multivariate analysis of clinical, pathological and flow cytometric parameters in 235 cases. *Histopathology* 16:545–555, 1990

## HISTOLOGIES—ANAL CANAL

- 8000/3 Neoplasm, malignant
- 8001/3 Tumor cells, malignant
- 8002/3 Malignant tumor, small cell type
- 8004/3 Malignant tumor, spindle cell type
- 8005/3 Malignant tumor, clear cell type
- 8010/2 Carcinoma *in situ*, NOS
- 8010/3 Carcinoma, NOS
- 8020/3 Carcinoma, undifferentiated, NOS
- 8021/3 Carcinoma, anaplastic, NOS
- 8032/3 Spindle cell carcinoma, NOS
- 8033/3 Pseudosarcomatous carcinoma
- 8041/3 Small cell carcinoma, NOS
- 8042/3 Oat cell carcinoma
- 8045/3 Combined small cell carcinoma
- 8051/3 Verrucous carcinoma, NOS
- 8070/2 Squamous cell carcinoma *in situ*, NOS
- 8070/3 Squamous cell carcinoma, NOS
- 8071/3 Squamous cell carcinoma, keratinizing, NOS
- 8072/3 Squamous cell carcinoma, large cell, non-keratinizing, NOS
- 8073/3 Squamous cell carcinoma, small cell, non-keratinizing
- 8074/3 Squamous cell carcinoma, spindle cell
- 8076/2 Squamous cell carcinoma *in situ* with questionable stromal invasion
- 8076/3 Squamous cell carcinoma, microinvasive
- 8083/3 Basaloid squamous cell carcinoma
- 8084/3 Squamous cell carcinoma, clear cell type
- 8123/3 Basaloid carcinoma
- 8124/3 Cloacogenic carcinoma
- 8140/2 Adenocarcinoma *in situ*, NOS
- 8140/3 Adenocarcinoma, NOS
- 8141/3 Scirrhous adenocarcinoma
- 8210/2 Adenocarcinoma *in situ* in adenomatous polyp
- 8210/3 Adenocarcinoma in adenomatous polyp

**HISTOLOGIES—ANAL CANAL (CONT.)**

8215/3 Adenocarcinoma of anal glands  
8244/3 Composite carcinoid  
8245/3 Adenocarcinoid tumor  
8246/3 Neuroendocrine carcinoma, NOS  
8249/3 Atypical carcinoid tumor  
8255/3 Adenocarcinoma with mixed subtypes

8310/3 Clear cell adenocarcinoma, NOS  
8480/3 Mucinous adenocarcinoma  
8481/3 Mucin-producing adenocarcinoma  
8490/3 Signet ring cell carcinoma  
8510/3 Medullary carcinoma, NOS  
8560/3 Adenosquamous carcinoma  
8933/3 Adenosarcoma



## ANAL CANAL

**Hospital Name/Address**

---



---



---

**Patient Name/Information**

---



---



---

Type of Specimen \_\_\_\_\_

Histopathologic Type \_\_\_\_\_

Tumor Size \_\_\_\_\_

### DEFINITIONS

<i>Clinical</i>	<i>Pathologic</i>	<b>Primary Tumor (T)</b>	
<input type="checkbox"/>	<input type="checkbox"/>	TX	Primary tumor cannot be assessed
<input type="checkbox"/>	<input type="checkbox"/>	T0	No evidence of primary tumor
<input type="checkbox"/>	<input type="checkbox"/>	Tis	Carcinoma <i>in situ</i>
<input type="checkbox"/>	<input type="checkbox"/>	T1	Tumor 2 cm or less in greatest dimension
<input type="checkbox"/>	<input type="checkbox"/>	T2	Tumor more than 2 cm but not more than 5 cm in greatest dimension
<input type="checkbox"/>	<input type="checkbox"/>	T3	Tumor more than 5 cm in greatest dimension
<input type="checkbox"/>	<input type="checkbox"/>	T4	Tumor of any size invades adjacent organ(s), e.g., vagina, urethra, bladder <sup>(1)</sup>

**Notes**

1. Direct invasion of the rectal wall, perirectal skin, subcutaneous tissue, or the sphincter muscle(s) is not classified as T4.

<i>Clinical</i>	<i>Pathologic</i>	<b>Regional Lymph Nodes (N)</b>	
<input type="checkbox"/>	<input type="checkbox"/>	NX	Regional lymph nodes cannot be assessed
<input type="checkbox"/>	<input type="checkbox"/>	N0	No regional lymph node metastasis
<input type="checkbox"/>	<input type="checkbox"/>	N1	Metastasis in perirectal lymph node(s)
<input type="checkbox"/>	<input type="checkbox"/>	N2	Metastasis in unilateral internal iliac and/or inguinal lymph node(s)
<input type="checkbox"/>	<input type="checkbox"/>	N3	Metastasis in perirectal and inguinal lymph nodes and/or bilateral internal iliac and/or inguinal lymph nodes

<i>Clinical</i>	<i>Pathologic</i>	<b>Distant Metastasis (M)</b>	
<input type="checkbox"/>	<input type="checkbox"/>	MX	Distant metastasis cannot be assessed
<input type="checkbox"/>	<input type="checkbox"/>	M0	No distant metastasis
<input type="checkbox"/>	<input type="checkbox"/>	M1	Distant metastasis

Biopsy of metastatic site performed .....  Y .....  N

Source of pathologic metastatic specimen \_\_\_\_\_

<i>Clinical</i>	<i>Pathologic</i>	<b>Stage Grouping</b>			
<input type="checkbox"/>	<input type="checkbox"/>	0	Tis	N0	M0
<input type="checkbox"/>	<input type="checkbox"/>	I	T1	N0	M0
<input type="checkbox"/>	<input type="checkbox"/>	II	T2	N0	M0
<input type="checkbox"/>	<input type="checkbox"/>		T3	N0	M0
<input type="checkbox"/>	<input type="checkbox"/>	IIIA	T1	N1	M0
<input type="checkbox"/>	<input type="checkbox"/>		T2	N1	M0
<input type="checkbox"/>	<input type="checkbox"/>		T3	N1	M0
<input type="checkbox"/>	<input type="checkbox"/>		T4	N0	M0
<input type="checkbox"/>	<input type="checkbox"/>	IIIB	T4	N1	M0
<input type="checkbox"/>	<input type="checkbox"/>		Any T	N2	M0
<input type="checkbox"/>	<input type="checkbox"/>		Any T	N3	M0
<input type="checkbox"/>	<input type="checkbox"/>	IV	Any T	Any N	M1

(continued on reverse side)

**Histologic Grade (G)**

- GX Grade cannot be assessed
- G1 Well differentiated
- G2 Moderately differentiated
- G3 Poorly differentiated
- G4 Undifferentiated

**Residual Tumor (R)**

- RX Presence of residual tumor cannot be assessed
- R0 No residual tumor
- R1 Microscopic residual tumor
- R2 Macroscopic residual tumor

**Additional Descriptors**

For identification of special cases of TNM or pTNM classifications, the “m” suffix and “y,” “r,” and “a” prefixes are used. Although they do not affect the stage grouping, they indicate cases needing separate analysis.

- m suffix** indicates the presence of multiple primary tumors in a single site and is recorded in parentheses: pT(m)NM.
- y prefix** indicates those cases in which classification is performed during or following initial multimodality therapy. The cTNM or pTNM category is identified by a “y” prefix. The ycTNM or ypTNM categorizes the extent of tumor actually present at the time of that examination. The “y” categorization is not an estimate of tumor prior to multimodality therapy.
- r prefix** indicates a recurrent tumor when staged after a disease-free interval, and is identified by the “r” prefix: rTNM.
- a prefix** designates the stage determined at autopsy: aTNM.

**Prognostic Indicators**

Poor histologic grade or histologic types that are categorized by convention as high-grade, such as small cell carcinoma, have been shown to be adverse prognostic factors.

**Notes**

**Additional Descriptors**

**Lymphatic Vessel Invasion (L)**  
LX Lymphatic vessel invasion cannot be assessed

L0 No lymphatic vessel invasion

L1 Lymphatic vessel invasion

**Venous Invasion (V)**

VX Venous invasion cannot be assessed

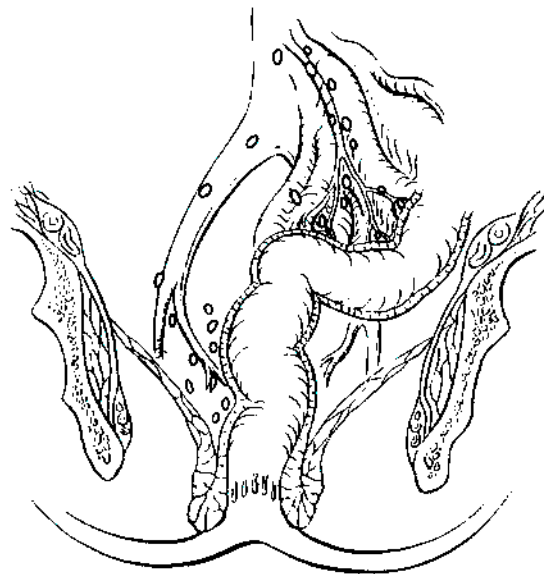
V0 No venous invasion

V1 Microscopic venous invasion

V2 Macroscopic venous invasion

**ILLUSTRATION**

Indicate on diagram primary tumor and regional nodes involved.



Physician's Signature \_\_\_\_\_ Date \_\_\_\_\_

## Liver (Including Intrahepatic Bile Ducts)

*(Sarcomas and tumors metastatic to the liver are not included.)*

C22.0 Liver

C22.1 Intrahepatic bile duct

### SUMMARY OF CHANGES

- The T categories in this edition have been redefined and simplified.
- All solitary tumors without vascular invasion, regardless of size, are classified as T1 because of similar prognosis.
- All solitary tumors with vascular invasion (again regardless of size) are combined with multiple tumors  $\leq 5$  cm and classified as T2 because of similar prognosis.
- Multiple tumors  $> 5$  cm and tumors with evidence of major vascular invasion are combined and classified as T3 because of similarly poor prognosis.
- Tumor(s) with direct invasion of adjacent organs other than the gallbladder or with perforation of visceral peritoneum are classified separately as T4.
- The separate subcategory for multiple bilobar tumors has been eliminated because of a lack of distinct prognostic value.
- T3 N0 tumors and tumors with lymph node involvement are combined into Stage III because of similar prognosis.
- Stage IV defines metastatic disease only. The subcategories IVA and IVB have been eliminated.

### INTRODUCTION

Primary malignancies of the liver include tumors arising from the hepatocytes (hepatocellular carcinoma), intrahepatic bile ducts (intrahepatic cholangiocarcinoma and cystadenocarcinoma), and mesenchymal elements (primary sarcomas, not covered in this chapter). Hepatocellular carcinoma is the most common primary cancer of the liver and is a leading cause of death from cancer worldwide. Although it is uncommon in the United States, its incidence is rising. The majority of hepatocellular carcinomas arise in a background of chronic liver disease due to viral hepatitis (B or C) or ethanol abuse. Cirrhosis may dominate the clinical picture and determine the prognosis. Other important indicators of the outcome of he-

patocellular carcinoma are resectability for cure and the extent of vascular invasion.

### ANATOMY

**Primary Site.** The liver has a dual blood supply: the hepatic artery, which branches from the celiac artery, and the portal vein, which drains the intestine. Blood from the liver passes through the hepatic vein and enters the inferior vena cava. The liver is divided into right and left lobes by a plane (Cantlie's line) projecting between the gallbladder fossa and the vena cava and defined by the middle hepatic vein. Couinaud refined knowledge about the functional anatomy

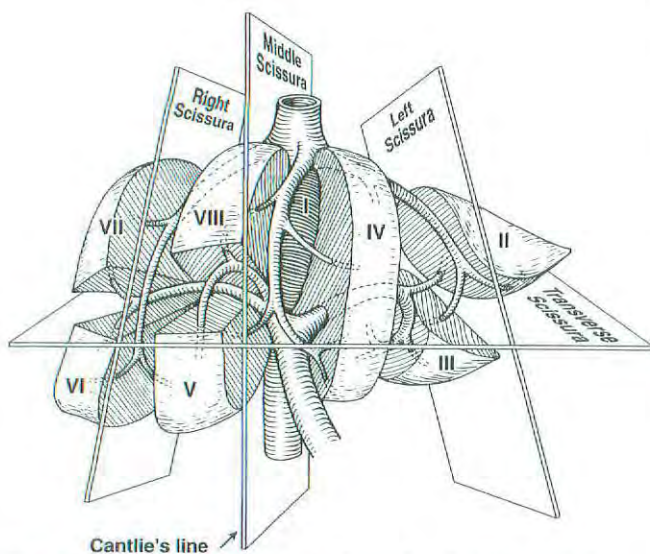
of the liver and proposed division of the liver into four sectors (formerly called segments) and eight segments. In this nomenclature, the liver is divided by vertical and oblique planes or scissurae defined by the three main hepatic veins and a transverse plane or scissura that follows a line drawn through the right and left portal branches. Thus, the four traditional segments (right anterior, right posterior, left medial, and left lateral) are replaced by sectors (right anterior, right posterior, left anterior, and left posterior), and these sectors are divided into segments by the transverse scissura (Fig. 14.1). The eight segments are numbered clockwise in a frontal plane. Recent advances in hepatic surgery have made possible anatomic (also called typical) resections along these planes.

Histologically, the liver is divided into lobules with central veins draining each lobule. The portal spaces between the lobules contain the intrahepatic bile ducts and the blood supply, which consists of small branches of the hepatic artery and portal vein (portal triads).

**Regional Lymph Nodes.** The regional lymph nodes are the hilar, hepatoduodenal ligament lymph nodes, and caval lymph nodes, among which the most prominent are the hepatic artery and portal vein lymph nodes. Histologic examination of a regional lymphadenectomy specimen will ordinarily include a minimum of three lymph nodes.

Nodal involvement beyond these lymph nodes is considered distant metastasis and should be coded as M1. Involvement of the inferior phrenic lymph nodes should also be considered M1.

**Metastatic Sites.** The main mode of dissemination of liver carcinomas is via the portal veins (intrahepatic) and hepatic veins. Intrahepatic venous dissemination cannot be differentiated from satellitosis or multifocal tumors and is classified as multiple tumors. The most common sites of extrahepatic dissemination are the lungs and bones. Tumors



**Fig. 14.1.** Anatomy of the liver. (Reproduced with permission from JN Vauthey. Liver imaging. *Radiol Clin North Am* 1998; 36(2):445.)

may extend through the liver capsule to adjacent organs (adrenal, diaphragm, and colon) or may rupture, causing acute hemorrhage and peritoneal carcinomatosis.

## RULES FOR CLASSIFICATION

The T classification is based on the results of multivariate analyses of factors affecting prognosis after resection of liver carcinomas. The classification considers the presence or absence of vascular invasion (as assessed radiographically or pathologically), the number of tumor nodules (single versus multiple), and the size of the largest tumor ( $\leq 5$  cm versus  $> 5$  cm). For pathologic classification, vascular invasion includes gross as well as microscopic involvement of vessels. Major vascular invasion (T3) is defined as invasion of the branches of the main portal vein (right or left portal vein, this does not include sectoral or segmental branches) or as invasion of one or more of the three hepatic veins (right, middle, or left). Multiple tumors include satellitosis, multifocal tumors, and intrahepatic metastases. Invasion of adjacent organs other than the gallbladder or with perforation of the visceral peritoneum is considered T4.

**Clinical Staging.** Clinical staging depends on imaging procedures designed to demonstrate the size of the primary tumor and vascular invasion. Surgical exploration is not carried out if imaging shows that complete resection is not possible or if the hepatic reserve is deemed insufficient for safe resection. In the presence of cirrhosis, the Child-Pugh class should be recorded using a point system. When advanced underlying liver disease (cirrhosis) dominates the prognosis, primary tumor factors (T stage) may become irrelevant in terms of prognosis. In these instances, another clinical staging system (Okuda staging, Cancer of the Liver Italian Program [CLIP] score, or Barcelona Clinic Liver Cancer [BCLC] staging) that combines the evaluation of liver disease and hepatocellular carcinoma may be helpful.

**Pathologic Staging.** Complete pathologic staging consists of evaluation of the primary tumor, including histologic grade; regional lymph nodes; and underlying liver disease. Regional lymph node involvement is rare (5%) except in the fibrolamellar variant of hepatocellular carcinoma. Tumors with positive lymph nodes are classified as Stage III because they carry the same prognosis as multiple tumors  $> 5$  cm and tumors with evidence of major vascular invasion. The grade is based on the cytopathologic study of nuclear pleomorphism as described by Edmonson and Steiner. Because of the prognostic significance of underlying liver disease in hepatocellular carcinoma, it is recommended that the results of the histopathologic analysis of the adjacent (non-tumorous) liver be reported. Severe fibrosis/cirrhosis (F1; Ishak score of 5–6) is associated with a worse prognosis than is no or moderate fibrosis (F0; Ishak score of 0–4). Although grade and underlying liver disease have prognostic significance, they are not included in the current staging system.

## DEFINITION OF TNM

### Primary Tumor (T)

- TX Primary tumor cannot be assessed
- T0 No evidence of primary tumor
- T1 Solitary tumor without vascular invasion
- T2 Solitary tumor with vascular invasion or multiple tumors none more than 5 cm
- T3 Multiple tumors more than 5 cm or tumor involving a major branch of the portal or hepatic vein(s)
- T4 Tumor(s) with direct invasion of adjacent organs other than the gallbladder or with perforation of visceral peritoneum.

### Regional Lymph Nodes (N)

- NX Regional lymph nodes cannot be assessed
- N0 No regional lymph node metastasis
- N1 Regional lymph node metastasis

### Distant Metastasis (M)

- MX Distant metastasis cannot be assessed
- M0 No distant metastasis
- M1 Distant metastasis

### STAGE GROUPING

Stage I	T1	N0	M0
Stage II	T2	N0	M0
Stage IIIA	T3	N0	M0
IIIB	T4	N0	M0
IIIC	Any T	N1	M0
Stage IV	Any T	Any N	M1

**Validation.** Validation of T1, T2, and T3 categories of this staging system is based on multivariate analyses of outcome and survival data of single-institution and multi-institution studies of hepatic resection of hepatocellular carcinoma worldwide (totaling 741 patients at seven institutions worldwide). The survival curves obtained from analysis of the database of the International Cooperative Study Group for Hepatocellular Carcinoma are presented in Figures 14.2, 14.3 and 14.4.

## HISTOPATHOLOGIC TYPE

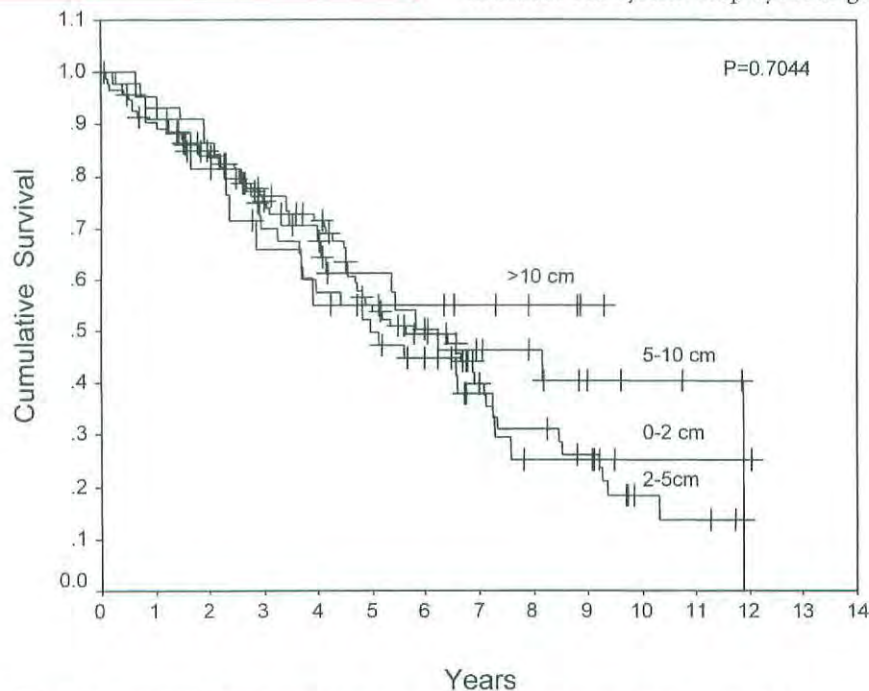
The staging system applies only to primary carcinomas of the liver. These include

- Hepatocellular carcinoma
- Intrahepatic bile duct carcinoma
- Mixed types

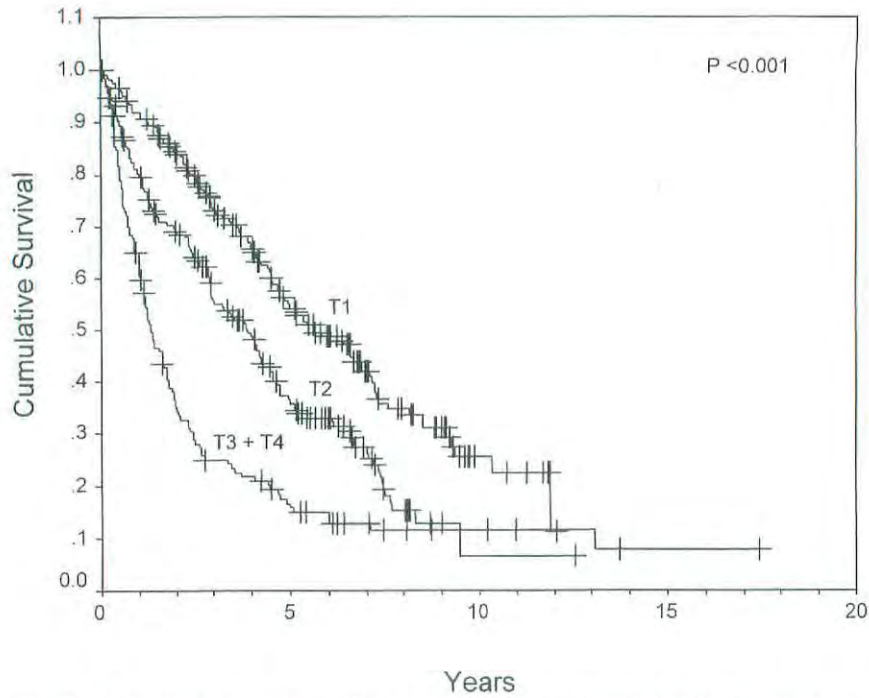
Hepatocellular carcinoma is by far the most common. The classification does not apply to primary sarcomas or metastatic tumors. The histologic type and subtype should be recorded, since they may provide prognostic information.

## HISTOLOGIC GRADE (G)

The grading scheme of Edmondson and Steiner is recommended. The system employs four grades as follows:



**Fig. 14.2.** Survival of patients with T1 tumors (solitary tumor without vascular invasion) stratified by size. Size does not affect prognosis for this category. (Reproduced with permission from Vauthey JN, Lauwers GY, Esnaola N, et al: A simplified staging for hepatocellular carcinoma. *J Clin Oncol* [in press].)

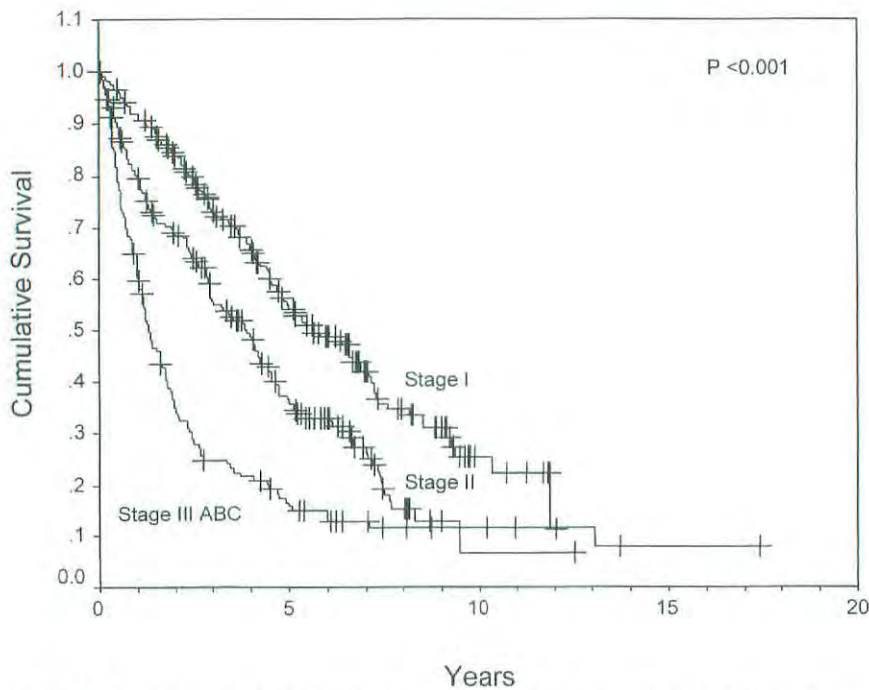


**Fig. 14.3.** Survival stratified according to T classification. (Reproduced with permission from Vauthey JN, Lauwers GY, Esnaola N, et al: A simplified staging for hepatocellular carcinoma. *J Clin Oncol* [in press].)

- G1 Well differentiated
- G2 Moderately differentiated
- G3 Poorly differentiated
- G4 Undifferentiated

### FIBROSIS SCORE (F)

The fibrosis score as defined by Ishak is recommended because of its prognostic value in overall survival. This scoring system uses a 0–6 scale.



**Fig. 14.4.** Survival stratified according to stage grouping. (Reproduced with permission from Vauthey JN, Lauwers GY, Esnaola N, et al: A simplified staging for hepatocellular carcinoma. *J Clin Oncol* [in press].)

- F0 Fibrosis score 0–4 (none to moderate fibrosis)  
 F1 Fibrosis score 5–6 (severe fibrosis or cirrhosis)

## PROGNOSTIC FACTORS

Clinical factors predictive of decreased survival duration include an elevated serum alpha-fetoprotein level and Child-Pugh class B and C liver disease. For patients who undergo tumor resection, the main predictor of poor outcome is a positive surgical margin (grossly or microscopically incomplete resection). The effect of margin size (< 10 mm versus  $\geq$  10 mm) remains controversial. Other prognostic factors associated with decreased survival include major vascular invasion and tumor size > 5 cm in patients with multiple tumors.

Intrahepatic bile duct cancer (cholangiocarcinoma) is currently staged similarly to hepatocellular carcinoma because of limited data regarding the factors that affect prognosis; we anticipate including a separate chapter for the staging of intrahepatic cholangiocarcinoma in the seventh edition of this manual.

## BIBLIOGRAPHY

- Bilimoria MM, Lauwers GY, Nagorney DM, et al: Underlying liver disease but not tumor factors predict long-term survival after hepatic resection of hepatocellular carcinoma. *Arch Surg* 136:528–535, 2001
- Cancer WG, Stewart AK, Menck HR: The National Cancer Data Base report on treatment patterns for hepatocellular carcinomas: improved survival of surgically resected patients, 1985–1996. *Cancer* 88:912–920, 2000
- The Cancer of the Liver Italian Program (CLIP) investigators: Prospective validation of the CLIP score: a new prognostic system for patients with cirrhosis and hepatocellular carcinoma. *Hepatology* 31:840–845, 2000
- Cantlie J: On a new arrangement of the right and left lobes of the liver. *J Anat Physiol* 32:iv–ix, 1897
- Couinaud C: Basic knowledge of interest: the paracaval segments of the liver. *J Hep Bil Pancr Surg* 2:145–151, 1994
- Edmondson HA, Steiner PE: Primary carcinoma of the liver: a study of 100 cases among 48,900 necropsies. *Cancer* 7:462–503, 1954
- El-Serag HB, Mason AC: Rising incidence of hepatocellular carcinoma in the United States. *N Engl J Med* 340:745–750, 1999
- Fong Y, Sun RL, Jarnagin W, et al: An analysis of 412 cases of hepatocellular carcinoma at a western center. *Ann Surg* 229:790–800, 1998
- Ikai I, Yamaoka Y, Yamamoto Y, et al: Surgical intervention for patients with stage IV-A hepatocellular carcinoma without lymph node metastasis: proposal as a standard therapy. *Ann Surg* 227:433–439, 1998
- Ishak K, Baptista A, Bianchi L, et al: Histological grading and staging of chronic hepatitis. *J Hepatol* 22:696–699, 1995
- Izumi R, Shimizu K, Ii T, Yagi M, et al: Prognostic factors of hepatocellular carcinoma in patients undergoing hepatic resection. *Gastroenterology* 106:720–727, 1994
- Jeng KS, Chen BF, Lin HJ: En bloc resection for extensive hepatocellular carcinoma: is it advisable? *World J Surg* 18:834–839, 1994
- Kosuge T, Makuuchi M, Takayama T, et al: Long-term results after resection of hepatocellular carcinoma: experience of 480 cases. *Hepatogastroenterology* 40:328–332, 1993
- Lau WY, Leung KL, Leung TW, et al: Resection of hepatocellular carcinoma with diaphragmatic invasion. *Br J Surg* 82:264–266, 1995
- Lauwers GY, Vauthey JN: Pathological aspects of hepatocellular carcinoma: a critical review of prognostic factors. *Hepatogastroenterology* 45 (Suppl 3):1197–1202, 1998
- Llovet JM, Bru C, Bruix J: Prognosis of hepatocellular carcinoma: the BCLC staging classification. *Semin Liver Dis* 19:329–338, 1999
- Nzeako UC, Goodman ZD, Ishak KG: Hepatocellular carcinoma in cirrhotic and noncirrhotic livers. A clinico-histopathologic study of 804 North American patients. *Am J Clin Pathol* 105:65–75, 1996
- Okuda K, Ohtsuki T, Obata H, et al: Natural history of hepatocellular carcinoma and prognosis in relation to treatment. Study of 850 patients. *Cancer* 56:918–928, 1985
- Poon RT, Fan ST, Ng IO, et al: Significance of resection margin in hepatectomy for hepatocellular carcinoma: a critical reappraisal. *Ann Surg* 231:544–551, 2000
- Pugh RN, Murray-Lyon IM, Dawson JL, et al: Transection of the oesophagus for bleeding oesophageal varices. *Br J Surg* 60:646–649, 1973
- Satoh, S, Ikai, I, Honda, G, et al: Clinicopathologic evaluation of hepatocellular carcinoma with bile duct thrombi. *Surgery* 128:779–783, 2000
- Staudacher C, Chiappa A, Biella F, et al: Validation of the modified TNM-Izumi classification for hepatocellular carcinoma. *Tumori* 86:8–11, 2000
- Tsai TJ, Chau GY, Lui WY, et al: Clinical significance of microscopic tumor venous invasion in patients with resectable hepatocellular carcinoma. *Surgery* 127:603–608, 2000
- Tung WY, Chau GY, Loong CC, et al: Surgical resection of primary hepatocellular carcinoma extending to adjacent organ(s). *Eur J Surg Oncol* 22:516–520, 1996
- Vauthey JN, Klimstra D, Franceschi D, et al: Factors affecting long-term outcome after hepatic resection for hepatocellular carcinoma. *Am J Surg* 169:28–35, 1995
- Vauthey JN, Lauwers GY, Esnaola N, et al: A simplified staging for hepatocellular carcinoma. *J Clin Oncol* (in press)
- Weimann A, Varnholt H, Schlitt HJ, et al: Retrospective analysis of prognostic factors after liver resection and transplantation for cholangiocellular carcinoma. *Br J Surg* 87:1182–1187, 2000
- Wu CC, Ho WL, Lin MC, et al: Hepatic resection for bilobar multicentric hepatocellular carcinoma: is it justified? *Surgery* 123:270–277, 1998
- Zhu LX, Wang GS, Fan, ST: Spontaneous rupture of hepatocellular carcinoma. *Br J Surg* 83:602–607, 2000

## HISTOLOGIES—LIVER

- 8010/3 Carcinoma, NOS  
 8012/3 Large cell carcinoma, NOS  
 8013/3 Large cell neuroendocrine carcinoma  
 8014/3 Large cell carcinoma with rhabdoid phenotype  
 8020/3 Carcinoma, undifferentiated, NOS

## HISTOLOGIES—LIVER (CONT.)

8021/3	Carcinoma, anaplastic, NOS	8180/3	Combined hepatocellular carcinoma and cholangio- carcinoma
8022/3	Pleomorphic carcinoma	8214/3	Parietal cell carcinoma
8030/3	Giant cell and spindle cell carcinoma	8230/3	Solid carcinoma, NOS
8031/3	Giant cell carcinoma	8244/3	Composite carcinoid
8032/3	Spindle cell carcinoma, NOS	8245/3	Adenocarcinoid tumor
8033/3	Pseudosarcomatous carcinoma	8246/3	Neuroendocrine carcinoma, NOS
8035/3	Carcinoma with osteoclast-like giant cells	8255/3	Adenocarcinoma with mixed subtypes
8140/2	Adenocarcinoma <i>in situ</i> , NOS	8260/3	Papillary adenocarcinoma, NOS
8140/3	Adenocarcinoma, NOS	8310/3	Clear cell adenocarcinoma, NOS
8141/3	Scirrhous adenocarcinoma	8320/3	Granular cell carcinoma
8142/3	Linitis plastica	8430/3	Mucoepidermoid carcinoma
8143/3	Superficial spreading adenocarcinoma	8440/3	Cystadenocarcinoma, NOS
8144/3	Adenocarcinoma, intestinal type	8452/3	Solid pseudopapillary carcinoma
8145/3	Carcinoma, diffuse type	8460/3	Papillary serous cystadenocarcinoma
8147/3	Basal cell adenocarcinoma	8461/3	Serous surface papillary carcinoma
8148/2	Glandular intraepithelial neoplasia, grade III	8470/2	Mucinous cystadenocarcinoma, non-invasive
8160/3	Cholangiocarcinoma	8470/3	Mucinous cystadenocarcinoma, NOS
8161/3	Bile duct cystadenocarcinoma	8471/3	Papillary mucinous cystadenocarcinoma
8162/3	Klatskin tumor	8480/3	Mucinous adenocarcinoma
8170/3	Hepatocellular carcinoma	8481/3	Mucin-producing adenocarcinoma
8171/3	Hepatocellular carcinoma, fibrolamellar	8490/3	Signet ring cell carcinoma
8172/3	Hepatocellular carcinoma, scirrhous	8500/2	Intraductal carcinoma, noninfiltrating, NOS
8173/3	Hepatocellular carcinoma, spindle cell variant	8503/2	Noninfiltrating intraductal papillary adenocarcinoma
8174/3	Hepatocellular carcinoma, clear cell type	8503/3	Intraductal papillary adenocarcinoma with invasion
8175/3	Hepatocellular carcinoma, pleomorphic type	8550/3	Acinar cell carcinoma
		8551/3	Acinar cell cystadenocarcinoma



**LIVER (INCLUDING INTRAHEPATIC BILE DUCTS)**

**Hospital Name/Address**

---



---



---

**Patient Name/Information**

---



---



---

Type of Specimen \_\_\_\_\_

Histopathologic Type \_\_\_\_\_

Tumor Size \_\_\_\_\_

**DEFINITIONS**

<i>Clinical</i>	<i>Pathologic</i>		<b>Primary Tumor (T)</b>
<input type="checkbox"/>	<input type="checkbox"/>	TX	Primary tumor cannot be assessed
<input type="checkbox"/>	<input type="checkbox"/>	T0	No evidence of primary tumor
<input type="checkbox"/>	<input type="checkbox"/>	T1	Solitary tumor without vascular invasion
<input type="checkbox"/>	<input type="checkbox"/>	T2	Solitary tumor with vascular invasion or multiple tumors none more than 5 cm
<input type="checkbox"/>	<input type="checkbox"/>	T3	Multiple tumors more than 5 cm or tumor involving a major branch of the portal or hepatic vein(s)
<input type="checkbox"/>	<input type="checkbox"/>	T4	Tumor(s) with direct invasion of adjacent organs other than the gallbladder or with perforation of visceral peritoneum

<i>Clinical</i>	<i>Pathologic</i>		<b>Regional Lymph Nodes (N)</b>
<input type="checkbox"/>	<input type="checkbox"/>	NX	Regional lymph nodes cannot be assessed
<input type="checkbox"/>	<input type="checkbox"/>	N0	No regional lymph node metastasis
<input type="checkbox"/>	<input type="checkbox"/>	N1	Regional lymph node metastasis

<i>Clinical</i>	<i>Pathologic</i>		<b>Distant Metastasis (M)</b>
<input type="checkbox"/>	<input type="checkbox"/>	MX	Distant metastasis cannot be assessed
<input type="checkbox"/>	<input type="checkbox"/>	M0	No distant metastasis
<input type="checkbox"/>	<input type="checkbox"/>	M1	Distant metastasis

Biopsy of metastatic site performed ..... Y ..... N  
 Source of pathologic metastatic specimen \_\_\_\_\_

<i>Clinical</i>	<i>Pathologic</i>	<b>Stage Grouping</b>			
<input type="checkbox"/>	<input type="checkbox"/>	I	T1	N0	M0
<input type="checkbox"/>	<input type="checkbox"/>	II	T2	N0	M0
<input type="checkbox"/>	<input type="checkbox"/>	IIIA	T3	N0	M0
<input type="checkbox"/>	<input type="checkbox"/>	IIIB	T4	N0	M0
<input type="checkbox"/>	<input type="checkbox"/>	IIIC	Any T	N1	M0
<input type="checkbox"/>	<input type="checkbox"/>	IV	Any T	Any N	M1

**Histologic Grade (G)**

*The grading scheme of Edmondson and Steiner is recommended. The system employs four grades.*

- GX Grade cannot be assessed
- G1 Well differentiated
- G2 Moderately differentiated
- G3 Poorly differentiated
- G4 Undifferentiated

**Residual Tumor (R)**

- RX Presence of residual tumor cannot be assessed
- R0 No residual tumor
- R1 Microscopic residual tumor
- R2 Macroscopic residual tumor

*(continued on reverse side)*

**Fibrosis Score (F)**

The fibrosis score as defined by Ishak is recommended because of its prognostic value in overall survival. This scoring system uses a 0-6 scale.

- F0      Fibrosis score 0-4 (none to moderate fibrosis)
- F1      Fibrosis score 5-6 (severe fibrosis or cirrhosis)

**Additional Descriptors**

For identification of special cases of TNM or pTNM classifications, the "m" suffix and "y," "r," and "a" prefixes are used. Although they do not affect the stage grouping, they indicate cases needing separate analysis.

- m suffix** indicates the presence of multiple primary tumors in a single site and is recorded in parentheses: pT(m)NM.
- y prefix** indicates those cases in which classification is performed during or following initial multimodality therapy. The cTNM or pTNM category is identified by a "y" prefix. The ycTNM or ypTNM categorizes the extent of tumor actually present at the time of that examination. The "y" categorization is not an estimate of tumor prior to multimodality therapy.
- r prefix** indicates a recurrent tumor when staged after a disease-free interval, and is identified by the "r" prefix: rTNM.
- a prefix** designates the stage determined at autopsy: aTNM.

**Prognostic Indicators (if applicable)**

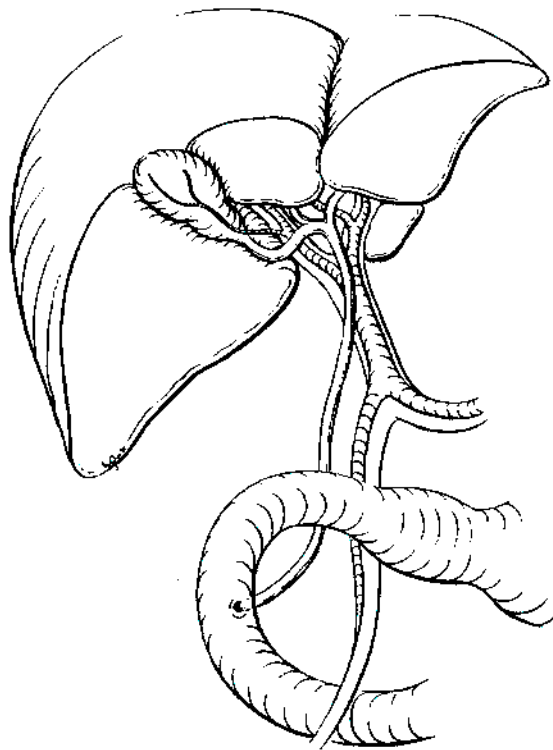
**Notes**

**Additional Descriptors**

- Lymphatic Vessel Invasion (L)**  
 LX Lymphatic vessel invasion cannot be assessed  
 L0 No lymphatic vessel invasion  
 L1 Lymphatic vessel invasion
- Venous Invasion (V)**  
 VX Venous invasion cannot be assessed  
 V0 No venous invasion  
 V1 Microscopic venous invasion  
 V2 Macroscopic venous invasion

**ILLUSTRATION**

Indicate on diagram primary tumor and regional nodes involved.



Physician's Signature \_\_\_\_\_ Date \_\_\_\_\_

# Gallbladder

(Carcinoid tumors and sarcomas are not included.)

C23.9 Gallbladder

3

## SUMMARY OF CHANGES

- The T and N classifications have been simplified in an effort to separate locally invasive tumors into potentially resectable (T3) and unresectable (T4).
- There is no longer a distinction between T3 and T4 based on the depth of liver invasion.
- Lymph node metastasis is now classified as Stage IIB, and Stage IIA is reserved for large, invasive tumors (resectable), without lymph node metastasis.
- Stage grouping has been changed to allow Stage III to signify locally unresectable disease and Stage IV to indicate metastatic disease.

## INTRODUCTION

Cancers of the gallbladder are staged according to their depth of penetration and extent of spread. These cancers frequently spread to the liver, which is involved in 70% of patients at the time of surgical evaluation. Malignant tumors of the gallbladder can also directly invade other adjacent organs, particularly the common bile duct, the duodenum, and the transverse colon. Gallbladder cancers are insidious in their growth, often metastasizing early, before a diagnosis is made. Tumors can also perforate the wall of the gallbladder, eventually causing intra-abdominal metastases, carcinomatosis, and ascites. Because gallbladder cancer is uncommon and is usually diagnosed late, physicians have tended to ignore anatomic staging, even though its importance for survival, management, and prognosis has been emphasized. Many cases are not suspected clinically and are first discovered at laparotomy or incidentally by the pathologist. More than 75% of carcinomas of the gallbladder are associated with cholelithiasis. Survival correlates with the stage of disease.

## ANATOMY

**Primary Site.** The gallbladder is a pear-shaped saccular organ located under the liver in the gallbladder fossa. It has three parts: a fundus, a body, and a neck that tapers into the

cystic duct. The wall of the gallbladder is much thinner than that of the intestine and lacks a circular and transverse muscle layer. The wall has a mucosa (that is, an epithelial lining and lamina propria), a smooth muscle layer analogous to the muscularis propria of the small intestine, perimuscular connective tissue, and serosa. In contrast to the intestine, there is no submucosa. Along the attachment to the liver, no serosa exists, and the perimuscular connective tissue is continuous with the interlobular connective tissue of the liver. Tumors that arise in the cystic duct are classified according to the scheme for the extrahepatic bile ducts.

**Regional Lymph Nodes.** Accurate tumor staging requires that all lymph nodes that are removed be analyzed. Optimal histologic examination of a regional lymphadenectomy specimen should include analysis of a minimum of three lymph nodes. The regional lymph nodes include the following: hilar, celiac, periduodenal, peripancreatic, and superior mesenteric. The hilar nodes include the lymph nodes along the common bile duct, hepatic artery, portal vein, and cystic duct.

Metastatic disease in peripancreatic nodes located along the body and tail of the pancreas are considered sites of distant metastasis.

**Metastatic Sites.** Cancers of the gallbladder usually metastasize to the peritoneum and liver and occasionally to the lungs and pleura.

## RULES FOR CLASSIFICATION

Gallbladder cancers are staged primarily on the basis of surgical exploration or resection. However, because not all patients with gallbladder cancer undergo surgical resection, a single TNM classification must apply to both clinical and pathologic staging. Therefore, in this edition of the *AJCC Cancer Staging Manual*, we have attempted to combine clinical and pathologic staging.

Many *in situ* and early-stage carcinomas are not recognized grossly. They are usually staged pathologically after histologic examination of the resected specimen. The T classification depends on the depth of tumor penetration into the wall of the gallbladder, on the presence or absence of tumor invasion into the liver, hepatic artery, or portal vein, and on the presence or absence of adjacent organ involvement. Direct tumor extension into the liver is not considered a metastatic (M) site. Direct invasion of other adjacent organs, including colon, duodenum, stomach, common bile duct, abdominal wall, and diaphragm, is also not considered a metastasis. Tumor confined to the gallbladder is classified as either T1 or T2, depending on the depth of invasion. It must be noted that because there is no serosa on the gallbladder on the side attached to the liver, a simple cholecystectomy may not completely remove a T2 tumor, even though such tumors are considered to be confined to the gallbladder.

**Clinical Staging.** Clinical evaluation usually depends on the results of ultrasonography and computed tomography. In recent years, magnetic resonance cholangiopancreatography has also proved to be a useful diagnostic and staging modality. Clinical staging may also be based on findings from surgical exploration when the main tumor mass is not resected.

**Pathologic Staging.** Pathologic staging is based on examination of the resected specimen.

*Note:* The extent of resection (R0, complete resection with grossly and microscopically negative margins of resection; R1, grossly negative but microscopically positive margins of resection; R2, grossly and microscopically positive margins of resection) is not part of the TNM staging system but is prognostically of great significance.

## DEFINITION OF TNM

### Primary Tumor (T)

- TX Primary tumor cannot be assessed
- T0 No evidence of primary tumor
- Tis Carcinoma *in situ*
- T1 Tumor invades lamina propria or muscle layer (Fig. 15.1)
- T1a Tumor invades lamina propria
- T1b Tumor invades muscle layer

- T2 Tumor invades perimuscular connective tissue; no extension beyond serosa or into liver (Fig. 15.2)
- T3 Tumor perforates the serosa (visceral peritoneum) and/or directly invades the liver and/or one other adjacent organ or structure, such as the stomach, duodenum, colon, or pancreas, omentum or extrahepatic bile ducts
- T4 Tumor invades main portal vein or hepatic artery or invades multiple extrahepatic organs or structures

### Regional Lymph Nodes (N)

- NX Regional lymph nodes cannot be assessed
- N0 No regional lymph node metastasis
- N1 Regional lymph node metastasis

### Distant Metastasis (M)

- MX Distant metastasis cannot be assessed
- M0 No distant metastasis
- M1 Distant metastasis

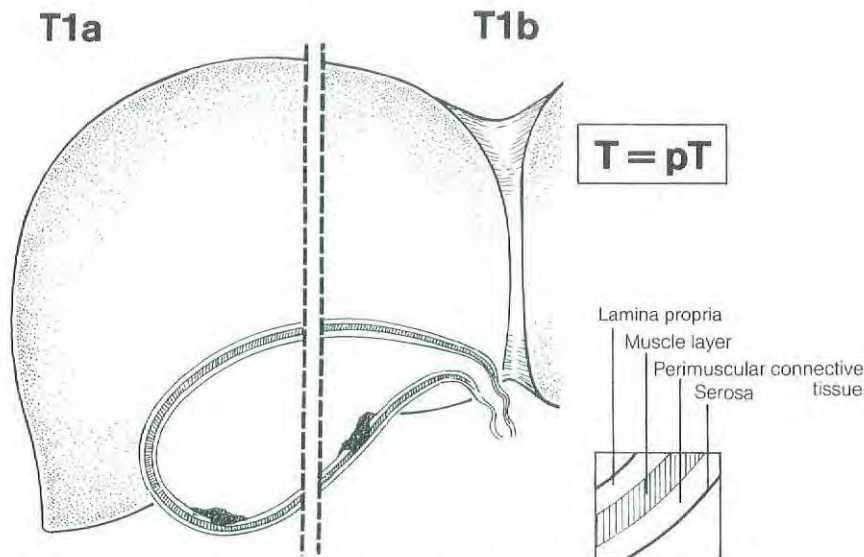
## STAGE GROUPING

Stage 0	Tis	N0	M0
Stage IA	T1	N0	M0
Stage IB	T2	N0	M0
Stage IIA	T3	N0	M0
Stage IIB	T1	N1	M0
	T2	N1	M0
	T3	N1	M0
Stage III	T4	Any N	M0
Stage IV	Any T	Any N	M1

## HISTOPATHOLOGIC TYPE

The staging system applies only to primary carcinomas of the gallbladder. It does not apply to carcinoid tumors or to sarcomas. Adenocarcinomas are the most common histologic type. More than 98% of gallbladder cancers are carcinomas. The carcinomas are listed below.

- Carcinoma *in situ*
- Adenocarcinoma, NOS
- Papillary carcinoma
- Adenocarcinoma, intestinal type
- Clear cell adenocarcinoma
- Mucinous carcinoma
- Signet ring cell carcinoma
- Squamous carcinoma
- Adenosquamous carcinoma
- Small cell carcinoma\*
- Undifferentiated carcinoma\*
  - Spindle and giant cell types
  - Small cell types
- Carcinoma, NOS



**Fig. 15.1.** Schematic representation of T1, showing the tumor invading the lamina propria or muscle layer of the gallbladder.

Carcinosarcoma  
Other (specify)

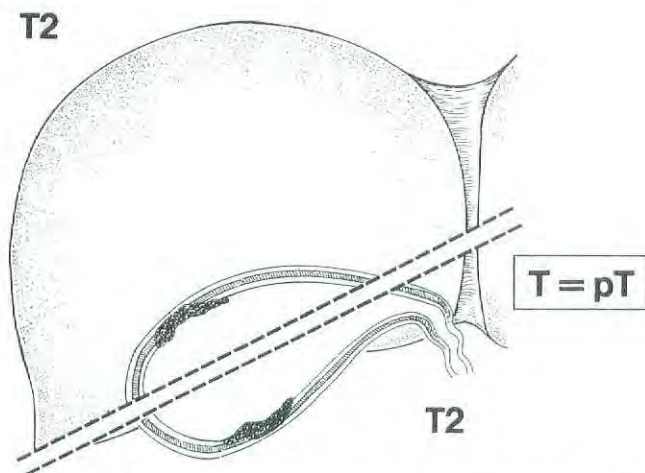
\*Grade 4 by definition

### HISTOLOGIC GRADE (G)

- GX Grade cannot be assessed
- G1 Well differentiated
- G2 Moderately differentiated
- G3 Poorly differentiated
- G4 Undifferentiated

### PROGNOSTIC FACTORS

Many patients' gallbladder malignancies are discovered at pathologic analysis after simple cholecystectomy for pre-



**Fig. 15.2.** Schematic representation of T2, showing the tumor invading perimuscular connective tissue of the gallbladder with no extension of tumor beyond serosa or into the liver.

sumed gallstone disease. Five-year survival is 85–100% for patients with T1 stage tumors. Patients with T2 tumors have a 5-year survival rate of approximately 30–40%, which appears to be improved (to a 5-year survival rate as high as 80–90%) with more radical resection. Patients with lymph node metastases or locally advanced tumors (Stages IIB and III) rarely experience long-term survival. The prognostic factors include histologic type, histologic grade, and vascular invasion. Papillary carcinomas have the most favorable prognosis. Unfavorable histologic types include small cell carcinomas and undifferentiated carcinomas. Lymphatic and/or blood vessel invasion indicates a less favorable outcome. Histologic grade also correlates with outcome.

Patients with T2–3 cancers discovered at pathologic analysis are usually offered a repeat operation for radical resection of residual tumor. There are indications that patients who require such repeat surgery for definitive treatment of gallbladder cancer do worse than patients who undergo only a single radical procedure for tumor resection; the former have higher incidences of peritoneal dissemination and local tumor recurrence. For patients who undergo two operations for treatment of gallbladder cancer, a classification to indicate reoperative therapy should be reported so that comparisons can be made with patients who had a single operation.

### BIBLIOGRAPHY

- Albores-Saavedra J, Henson DE: Tumors of the gallbladder and extrahepatic bile ducts. In *Atlas of tumor pathology*, 2nd series, fascicle 22. Washington, DC: Armed Forces Institute of Pathology, 1986
- Albores-Saavedra J, Henson DE, Sobin LH: Histological typing of tumours of the gallbladder and extrahepatic bile ducts. In *WHO international histological classification of tumours*. Berlin: Springer-Verlag, 1991
- Bergdahl L: Gallbladder carcinoma first diagnosed at micro-

- scopic examination of gallbladders removed for presumed benign disease. *Ann Surg* 191:19–22, 1980
- Bivins BA, Meeker MR, Griffen WO Jr: Importance of histologic classification of carcinoma of the gallbladder. *Am Surg* 41:121–124, 1975
- de Arexabala X, Roa IS, Burgos LA, et al: Curative resection in potentially resectable tumours of the gallbladder. *Euro J Surg* 163:419–426, 1997
- Donohue JH, Nagorney DM, Grant CS, et al: Carcinoma of the gallbladder: does radical resection improve outcome? *Arch Surg* 125:237–241, 1990
- Donohue JH, Stewart AK, Menck HR: The National Cancer Data Base report on carcinoma of the gallbladder, 1989–1995. *Cancer* 83:2618–2628, 1998
- Fahim RB, McDonald JR, Richards JC, et al: Carcinoma of the gallbladder: a study of its modes of spread. *Ann Surg* 156:114–124, 1962
- Fong Y, Brennan MF, Turnbull A, et al: Gallbladder cancers discovered during laparoscopic surgery: potential for iatrogenic tumor dissemination. *Arch Surg* 128:1054–1056, 1993
- Fong Y, Jarnagin W, Blumgart LH: Gallbladder cancer: comparison of patients presenting initially for definitive operation with those presenting after prior noncurative intervention. *Ann Surg* 232:557–569, 2000
- Guo K J, Yamaguchi K, Enjoji M: Undifferentiated carcinoma of the gallbladder. A clinicopathologic, histochemical, and immunohistochemical study of 21 patients with a poor prognosis. *Cancer* 61:1872–1879, 1988
- Henson DE, Albores-Saavedra J, Corle D: Carcinoma of the gallbladder. Histologic types, stage of disease, grade, and survival rates. *Cancer* 70:1493–1497, 1992
- Hisatomi K, Haratake J, Horie A, et al: Relation of histopathological features to prognosis of gallbladder cancer. *Am J Gastroenterol* 85:567–572, 1990
- Jones RS: Carcinoma of the gallbladder [review]. *Surg Clin North Am* 70:1419–1428, 1990
- Nevin JE, Moran TJ, Kay S, et al: Carcinoma of the gallbladder: staging, treatment, and prognosis. *Cancer* 37:141–148, 1976
- Ogura Y, Mizumoto R, Isaji S, et al: Radical operations for carcinoma of the gallbladder: present status in Japan. *World J Surg* 15:337–343, 1991
- Ohtani T, Shirai Y, Tsukada K, et al: Carcinoma of the gallbladder: CT evaluation of lymphatic spread. *Radiology* 189:875–880, 1993
- Ouchi K, Owada Y, Matsuno S, et al: Prognostic factors in the surgical treatment of gallbladder carcinoma. *Surgery* 101:731–737, 1987
- Perpetuo MD, Valdivieso M, Heilbrun LK, et al: Natural history of gallbladder cancer. *Cancer* 42:330–335, 1978
- Shirai Y, Ohtani T, Hatakeyama K: Laparoscopic cholecystectomy may disseminate gallbladder carcinoma. *Hepatogastroenterology* 45:81–82, 1998
- Shirai Y, Tsukada K, Ohtani T, et al: Hepatic metastases from carcinoma of the gallbladder. *Cancer* 75:2063–2068, 1995
- Shirai Y, Yoshida K, Tsukada K, et al: Identification of the regional lymphatic system of the gallbladder by vital staining. *Br J Surg* 79:659–662, 1992
- Todoroki T, Kawamoto T, Takahashi H, et al: Treatment of gallbladder cancer by radical resection. *Br J Surg* 86:622–627, 1999
- Yamamoto M, Nakajo S, Tahara E: Carcinoma of the gallbladder: the correlation between histogenesis and prognosis. *Virchows Archiv A, Pathological Anatomy and Histopathology* 414:83–90, 1989

## HISTOLOGIES—GALLBLADDER

8010/2	Carcinoma <i>in situ</i> , NOS
8010/3	Carcinoma, NOS
8020/3	Undifferentiated carcinoma
8041/3	Small cell carcinoma, NOS
8070/3	Squamous cell carcinoma, NOS
8082/3	Lymphoepithelial carcinoma
8083/3	Basaloid squamous cell carcinoma
8084/3	Squamous cell carcinoma, clear cell type
8140/2	Adenocarcinoma <i>in situ</i> , NOS
8140/3	Adenocarcinoma, NOS
8144/3	Adenocarcinoma, intestinal type
8255/3	Adenocarcinoma with mixed subtypes
8260/3	Papillary adenocarcinoma, NOS
8310/3	Clear cell adenocarcinoma
8480/3	Mucinous adenocarcinoma
8490/3	Signet ring cell carcinoma
8560/3	Adenosquamous carcinoma
8980/3	Carcinosarcoma

## GALLBLADDER

**Hospital Name/Address**

---



---



---

**Patient Name/Information**

---



---



---

Type of Specimen \_\_\_\_\_

Histopathologic Type \_\_\_\_\_

Tumor Size \_\_\_\_\_

3

### DEFINITIONS

<i>Clinical</i>	<i>Pathologic</i>	<b>Primary Tumor (T)</b>	
<input type="checkbox"/>	<input type="checkbox"/>	TX	Primary tumor cannot be assessed
<input type="checkbox"/>	<input type="checkbox"/>	T0	No evidence of primary tumor
<input type="checkbox"/>	<input type="checkbox"/>	Tis	Carcinoma <i>in situ</i>
<input type="checkbox"/>	<input type="checkbox"/>	T1	Tumor invades lamina propria or muscle layer
<input type="checkbox"/>	<input type="checkbox"/>	T1a	Tumor invades lamina propria
<input type="checkbox"/>	<input type="checkbox"/>	T1b	Tumor invades muscle layer
<input type="checkbox"/>	<input type="checkbox"/>	T2	Tumor invades perimuscular connective tissue; no extension beyond serosa or into liver
<input type="checkbox"/>	<input type="checkbox"/>	T3	Tumor perforates the serosa (visceral peritoneum) and/or directly invades the liver and/or one other adjacent organ or structure, such as the stomach, duodenum, colon, pancreas, omentum, or extrahepatic bile ducts
<input type="checkbox"/>	<input type="checkbox"/>	T4	Tumor invades main portal vein or hepatic artery or invades two or more extrahepatic organs or structures

		<b>Regional Lymph Nodes (N)</b>	
<input type="checkbox"/>	<input type="checkbox"/>	NX	Regional lymph nodes cannot be assessed
<input type="checkbox"/>	<input type="checkbox"/>	N0	No regional lymph node metastasis
<input type="checkbox"/>	<input type="checkbox"/>	N1	Regional lymph node metastasis

		<b>Distant Metastasis (M)</b>	
<input type="checkbox"/>	<input type="checkbox"/>	MX	Distant metastasis cannot be assessed
<input type="checkbox"/>	<input type="checkbox"/>	M0	No distant metastasis
<input type="checkbox"/>	<input type="checkbox"/>	M1	Distant metastasis
		Biopsy of metastatic site performed ..... <input type="checkbox"/> Y ..... <input type="checkbox"/> N	
		Source of pathologic metastatic specimen _____	

		<b>Stage Grouping</b>				
<input type="checkbox"/>	<input type="checkbox"/>	0	Tis	N0	M0	
<input type="checkbox"/>	<input type="checkbox"/>	IA	T1	N0	M0	
<input type="checkbox"/>	<input type="checkbox"/>	IB	T2	N0	M0	
<input type="checkbox"/>	<input type="checkbox"/>	IIA	T3	N0	M0	
<input type="checkbox"/>	<input type="checkbox"/>		IIB	T1	N1	M0
<input type="checkbox"/>	<input type="checkbox"/>			T2	N1	M0
<input type="checkbox"/>	<input type="checkbox"/>		T3	N1	M0	
<input type="checkbox"/>	<input type="checkbox"/>	III	T4	Any N	M0	
<input type="checkbox"/>	<input type="checkbox"/>	IV	Any T	Any N	M1	

*(continued on reverse side)*

**Histologic Grade (G)**

- GX Grade cannot be assessed
- G1 Well differentiated
- G2 Moderately differentiated
- G3 Poorly differentiated
- G4 Undifferentiated

**Residual Tumor (R)**

- RX Presence of residual tumor cannot be assessed
- R0 No residual tumor
- R1 Microscopic residual tumor
- R2 Macroscopic residual tumor

**Additional Descriptors**

For identification of special cases of TNM or pTNM classifications, the "m" suffix and "y," "r," and "a" prefixes are used. Although they do not affect the stage grouping, they indicate cases needing separate analysis.

- m suffix** indicates the presence of multiple primary tumors in a single site and is recorded in parentheses: pT(m)NM.
- y prefix** indicates those cases in which classification is performed during or following initial multimodality therapy. The cTNM or pTNM category is identified by a "y" prefix. The ycTNM or ypTNM categorizes the extent of tumor actually present at the time of that examination. The "y" categorization is not an estimate of tumor prior to multimodality therapy.
- r prefix** indicates a recurrent tumor when staged after a disease-free interval, and is identified by the "r" prefix: rTNM.
- a prefix** designates the stage determined at autopsy: aTNM.

**Prognostic Indicators (if applicable)**

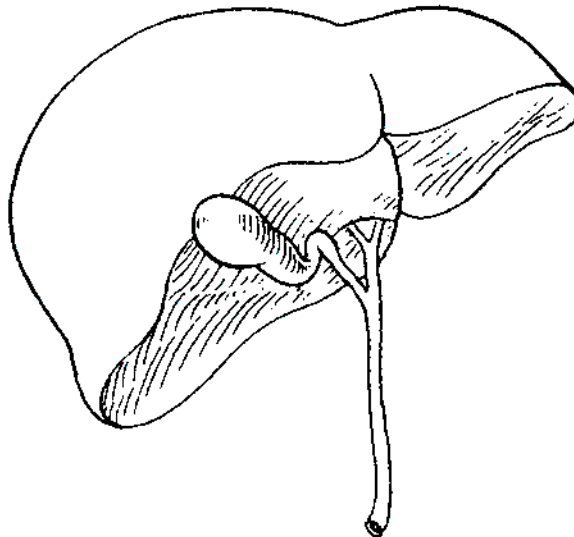
**Notes**

**Additional Descriptors**

- Lymphatic Vessel Invasion (L)**
- L0 Lymphatic vessel invasion cannot be assessed
  - L1 No lymphatic vessel invasion
  - L2 Lymphatic vessel invasion
- Venous Invasion (V)**
- VX Venous invasion cannot be assessed
  - V0 No venous invasion
  - V1 Microscopic venous invasion
  - V2 Macroscopic venous invasion

**ILLUSTRATION**

Indicate on diagram primary tumor and regional nodes involved.



Physician's Signature \_\_\_\_\_ Date \_\_\_\_\_



## Extrahepatic Bile Ducts

*(Sarcomas and carcinoid tumors are not included.)*

C24.0 Extrahepatic bile duct

C24.8 Overlapping lesion of biliary tract

C24.9 Biliary tract, NOS

### SUMMARY OF CHANGES

- The T and N classifications have been redefined and simplified.
- Invasion of the subepithelial fibro (muscular) connective tissue is classified as T1 irrespective of muscular invasion, which cannot always be noted because of the scarcity of muscle fibers in some bile duct segments.
- T2 is defined as invasion beyond the wall of the bile duct.
- The T classification allows one to separate locally invasive tumors into resectable (T3) and unresectable (T4).
- Invasion of branches of the portal vein (right or left), hepatic artery, or liver is classified as T3.
- Invasion of the main portal vein, common hepatic artery, and/or regional organs is classified as T4.
- The stage grouping has been changed to allow Stage III to signify locally unresectable disease and Stage IV to indicate metastatic disease.

### INTRODUCTION

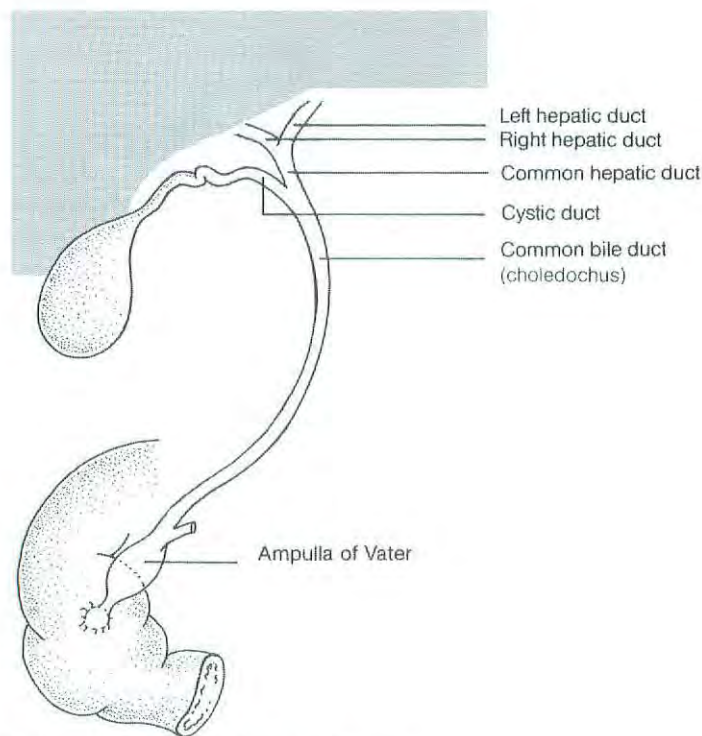
Malignant tumors can develop anywhere along the extrahepatic bile ducts (Fig. 16.1). Of these tumors, 70–80% involve the confluence of the right and left hepatic ducts (hilar carcinomas), and about 20–30% arise more distally. Diffuse involvement of the ducts is rare, occurring in only about 2% of cases. All malignant tumors of the extrahepatic bile ducts inevitably cause partial or complete ductal obstruction. Because the bile ducts have a small diameter, the signs and symptoms of obstruction usually occur while tumors are relatively small. Because of their invasion of major vascular structures and direct extension to the liver, hilar carcinomas are more difficult to resect than those that arise distally and are associated with a worse prognosis (because of the low rate of resectability).

This TNM classification applies only to cancers arising in the extrahepatic bile ducts above the ampulla of Vater. This includes malignant tumors that develop in congenital choledochal cysts and tumors that arise in the intrapancreatic portion of the common bile duct. Patients with advanced (metastatic) disease and a primary tumor in the intrapan-

creatic portion of the common bile duct may be misclassified as having pancreatic cancer if surgical resection is not performed. In such cases, it is often impossible to determine (from radiographic images or endoscopy) whether a tumor arises from the intrapancreatic portion of the bile duct, the ampulla of Vater, or the pancreas. Tumors of the pancreas and ampulla of Vater are classified separately.

### ANATOMY

**Primary Site.** Emerging from the transverse scissura of the liver are the right and left hepatic bile ducts, which join to form the common hepatic duct. The cystic duct, which connects to the gallbladder, joins the common hepatic duct to form the common bile duct, which passes posterior to the first part of the duodenum, traverses the head of the pancreas, and then enters the second part of the duodenum through the ampulla of Vater. Histologically, the bile ducts are lined by a single layer of tall, uniform columnar cells. The mucosa usually forms irregular pleats or small longitudinal



**Fig. 16.1.** Anatomy of the extrahepatic bile ducts.

folks. The walls of the bile ducts have a layer of subepithelial connective tissue and muscle fibers. It should be noted that the muscle fibers are most prominent in the distal segment of the common bile duct. More proximally, the muscle fibers are sparse or absent, and the walls of the bile ducts consist largely of fibrous tissue.

**Regional Lymph Nodes.** Accurate tumor staging requires that all lymph nodes that are removed be analyzed. Optimal histologic examination of a regional lymphadenectomy specimen should include analysis of a minimum of three lymph nodes. The regional lymph nodes are the same as those listed for the gallbladder cancer and include the following: hilar, celiac, periduodenal, peripancreatic, and superior mesenteric. The hilar nodes include the lymph nodes along the common bile duct, hepatic artery, portal vein, and cystic duct.

**Metastatic Sites.** Extrahepatic bile duct carcinomas can extend to the liver, pancreas, ampulla of Vater, duodenum, colon, omentum, stomach, or gallbladder. Tumors arising in the right or left hepatic ducts usually extend proximally into the liver or distally to the common hepatic duct. Neoplasms from the cystic duct invade the gallbladder, common bile duct, or both. Carcinomas that arise in the distal segment of the common bile duct can spread to the pancreas, duodenum, stomach, colon, or omentum. Distant metastases usually occur late in the course of the disease and are most often found in the liver, lungs, and peritoneum.

## RULES FOR CLASSIFICATION

Although for most malignancies, patients are staged following surgery and pathologic examination, this is often not true of patients with carcinoma of the extrahepatic bile ducts. In a third to a half of cases, surgical resection is not attempted because of local/regional extension, and patients are treated without pathologic staging. A single TNM classification must apply to both clinical and pathologic staging. In this edition of the *AJCC Cancer Staging Manual*, we have attempted to combine clinical and pathologic staging. With advances in imaging, integrated radiologic and pathologic staging of patients can be satisfactorily achieved.

**Clinical Staging.** Clinical evaluation usually depends on the results of ultrasonography, computed tomography, and magnetic resonance cholangiopancreatography. Clinical staging may also be based on findings from surgical exploration when the main tumor mass is not resected.

**Pathologic Staging.** Pathologic staging is based on examination of the resected specimen.

*Note:* The extent of resection (R0, complete resection with grossly and microscopically negative margins of resection; R1, grossly negative but microscopically positive margins of resection; R2, grossly and microscopically positive margins of resection) is not part of the TNM staging system but is prognostically of great significance.

## DEFINITION OF TNM

### Primary Tumor (T)

- TX Primary tumor cannot be assessed  
T0 No evidence of primary tumor  
Tis Carcinoma *in situ*  
T1 Tumor confined to the bile duct histologically  
T2 Tumor invades beyond the wall of the bile duct  
T3 Tumor invades the liver, gallbladder, pancreas, and/or unilateral branches of the portal vein (right or left) or hepatic artery (right or left)  
T4 Tumor invades any of the following: main portal vein or its branches bilaterally, common hepatic artery, or other adjacent structures, such as the colon, stomach, duodenum, or abdominal wall

### Regional Lymph Nodes (N)

- NX Regional lymph nodes cannot be assessed  
N0 No regional lymph node metastasis  
N1 Regional lymph node metastasis

### Distant Metastasis (M)

- MX Distant metastasis cannot be assessed  
M0 No distant metastasis  
M1 Distant metastasis

### STAGE GROUPING

Stage 0	Tis	N0	M0
Stage IA	T1	N0	M0
Stage IB	T2	N0	M0
Stage IIA	T3	N0	M0
Stage IIB	T1	N1	M0
	T2	N1	M0
	T3	N1	M0
Stage III	T4	Any N	M0
Stage IV	Any T	Any N	M1

## HISTOPATHOLOGIC TYPE

The staging system applies to all carcinomas that arise in the extrahepatic bile ducts or in the cystic duct. Sarcomas and carcinoid tumors are excluded. "Adenocarcinoma, NOS" is the most common histologic type. Carcinomas account for more than 98% of cancers of the extrahepatic bile ducts. The histologic types include:

- Carcinomas *in situ*  
Adenocarcinoma, NOS  
Adenocarcinoma, intestinal type  
Clear cell adenocarcinoma  
Mucinous carcinoma  
Signet ring cell carcinoma  
Squamous cell carcinoma  
Adenosquamous carcinoma

- Small cell carcinoma\*  
Undifferentiated carcinoma\*  
Spindle and giant cell types  
Small cell types  
Papillomatosis  
Papillary carcinoma, non-invasive  
Papillary carcinoma, invasive  
Carcinoma, NOS  
Other (specify)

\*Grade 4 by definition

## HISTOLOGIC GRADE (G)

- GX Grade cannot be assessed  
G1 Well differentiated  
G2 Moderately differentiated  
G3 Poorly differentiated  
G4 Undifferentiated

## PROGNOSTIC FACTORS

Patients who undergo surgical resection for localized bile duct adenocarcinoma have a median survival of approximately 2 years and a 5-year survival of 20–40% based on extent of disease at the time of surgery. Several prognostic factors based on the pathologic characteristics of the primary tumor have been reported for carcinomas of the extrahepatic bile ducts. These include histologic type, histologic grade, and vascular, lymphatic, and perineural invasion. Papillary carcinomas have a more favorable outcome than other types of carcinoma. High-grade tumors (grades 3–4) have a less favorable outcome than low-grade tumors (grades 1–2). Positive surgical margins have emerged as a very important prognostic factor. Residual tumor classification (R0, R1, R2) should be reported if the margins are involved.

## BIBLIOGRAPHY

- Albores-Saavedra J, Henson DE: Tumors of the gallbladder and extrahepatic bile ducts. In Atlas of tumor pathology, 2nd series, fascicle 22, Washington, DC: Armed Forces Institute of Pathology, 1986
- Albores-Saavedra J, Henson DE, Sobin LH: Histological typing of tumours of the gallbladder and extrahepatic bile ducts. In WHO international histological classification of tumors. Berlin: Springer-Verlag, 1991
- Bhuiya MMR, Nimura Y, Kamiya J, et al: Clinicopathologic factors influencing survival of patients with bile duct carcinoma: multivariate statistical analysis. *World J Surg* 17:653, 1993
- Bhuiya MMR, Nimura Y, Kamiya J, et al: Clinicopathologic studies on perineural invasion of bile duct carcinoma. *Ann Surg* 215:344–349, 1992
- Braasch JW, Warren KW, Kune GA: Malignant neoplasms of the bile ducts. *Surg Clin North Am* 47:627–638, 1967

Burke EC, Jarnagin WR, Hochwald SN, et al: Hilar cholangiocarcinoma: patterns of spread, the importance of hepatic resection for curative operation, and a presurgical clinical staging system. *Ann Surg* 228:385–394, 1998

Hayashi S, Miyazaki M, Kondo Y, et al: Invasive growth patterns of hepatic hilar ductal carcinoma: a histologic analysis of 18 surgical cases. *Cancer* 73:2922–2929, 1994

Henson DE, Albores-Saavedra J, Corle D: Carcinoma of the extrahepatic bile ducts: histologic types, stage of disease, grade and survival. *Cancer* 70:1498–1501, 1992

Hong SM, Kang GH, Lee HY: Smooth muscle distribution in the extrahepatic bile duct: histologic and immunohistochemical studies of 122 cases. *Am J Surg Pathol* 24:660–667, 2000

Kayahara M, Nagakawa T, Tsukioka Y, et al: Neural invasion and nodal involvement in distal bile duct cancer. *Hepato-gastroenterology* 41:190–194, 1994

Kayahara M, Nagakawa T, Ueno K, et al: Lymphatic flow in carcinoma of the distal bile duct based on a clinicopathologic study. *Cancer* 72:2112–2117, 1993

Kosuge T, Yamamoto J, Shimada K, et al: Improved surgical results for hilar cholangiocarcinoma with procedures including major hepatic resection. *Ann Surg* 230:663–671, 1999

Longmire WP Jr, McArthur MS, Bastounis EA, et al: Carcinoma of the extrahepatic biliary tract. *Ann Surg* 178:333–345, 1973

Nakeeb A, Pitt HA, Sohn TA, et al: Cholangiocarcinoma. A spectrum of intrahepatic, perihilar, and distal tumors. *Ann Surg* 224:463–475, 1996

Ogura Y, Takahashi K, Tabata M, et al: Clinicopathological study on carcinoma of the extrahepatic bile duct with special focus on cancer invasion on the surgical margins. *World J Surg* 18:778–784, 1994

Ouchi K, Suzuki M, Hashimoto L, et al: Histologic findings and prognostic factors in carcinoma of the upper bile duct. *Am J Surg* 157:552–556, 1989

Suzuki M, Takahashi T, Ouchi K, et al: The development and extension of hepatohilar bile duct carcinoma: a three-dimensional tumor mapping in the intrahepatic biliary tree visualized with the aid of a graphics computer system. *Cancer* 64:658–666, 1989

Tamada K, Ido K, Ueno N, et al: Preoperative staging of extrahepatic bile duct cancer: comparison with pathological staging. *Gastroenterology* 100(pt 1):1351–1361, 1991

Tio TL, Wijers OB, Sars PR, et al: Preoperative TNM classification of proximal extrahepatic bile duct carcinoma by endosonography. *Semin Liver Dis* 10:114–120, 1990

Tompkins RK, Saunders K, Roslyn JJ, et al: Changing patterns in diagnosis and management of bile duct cancer. *Ann Surg* 211:613–620, 1990

Tompkins RK, Thomas D, Wile A, et al: Prognostic factors in bile duct carcinoma. *Ann Surg* 194:447–455, 1981

Tsunodo T, Eto T, Koga M, et al: Early carcinoma of the extrahepatic bile duct. *Jpn J Surg* 19:691–698, 1989

Yamaguchi K: Early bile duct carcinoma. *Aust N Z J Surg* 62:525–529, 1992

## HISTOLOGIES—EXTRAHEPATIC BILE DUCTS

8002/3	Malignant tumor, small cell type
8003/3	Malignant tumor, giant cell type
8005/3	Malignant tumor, clear cell type
8010/2	Carcinoma <i>in situ</i> , NOS
8010/3	Carcinoma, NOS
8020/3	Carcinoma, undifferentiated, NOS
8021/3	Carcinoma, anaplastic, NOS
8022/3	Pleomorphic carcinoma
8030/3	Giant cell and spindle cell carcinoma
8031/3	Giant cell carcinoma
8032/3	Spindle cell carcinoma, NOS
8041/3	Small cell carcinoma, NOS
8042/3	Oat cell carcinoma
8043/3	Small cell carcinoma, fusiform cell
8044/3	Small cell carcinoma, intermediate cell
8045/3	Combined small cell carcinoma
8070/3	Squamous cell carcinoma, NOS
8140/2	Adenocarcinoma <i>in situ</i> , NOS
8140/3	Adenocarcinoma, NOS
8144/3	Adenocarcinoma, intestinal type
8160/3	Cholangiocarcinoma
8161/3	Bile duct cystadenocarcinoma
8162/3	Klatskin tumor
8180/3	Combined hepatocellular carcinoma and cholangiocarcinoma
8260/3	Papillary adenocarcinoma, NOS
8310/3	Clear cell adenocarcinoma
8480/3	Mucinous adenocarcinoma
8490/3	Signet ring cell carcinoma
8560/3	Adenosquamous carcinoma

## EXTRAHEPATIC BILE DUCTS

Hospital Name/Address
-----------------------

Patient Name/Information
--------------------------

Type of Specimen \_\_\_\_\_

Histopathologic Type \_\_\_\_\_

Tumor Size \_\_\_\_\_

3

### DEFINITIONS

Clinical	Pathologic	<b>Primary Tumor (T)</b>	
<input type="checkbox"/>	<input type="checkbox"/>	TX	Primary tumor cannot be assessed
<input type="checkbox"/>	<input type="checkbox"/>	T0	No evidence of primary tumor
<input type="checkbox"/>	<input type="checkbox"/>	Tis	Carcinoma <i>in situ</i>
<input type="checkbox"/>	<input type="checkbox"/>	T1	Tumor confined to the bile duct histologically
<input type="checkbox"/>	<input type="checkbox"/>	T2	Tumor invades beyond the wall of the bile duct
<input type="checkbox"/>	<input type="checkbox"/>	T3	Tumor invades the liver, gallbladder, pancreas, and/or ipsilateral branches of the portal vein (right or left) or hepatic artery (right or left)
<input type="checkbox"/>	<input type="checkbox"/>	T4	Tumor invades any of the following: main portal vein or its branches bilaterally, common hepatic artery, or other adjacent structures, such as the colon, stomach, duodenum, or abdominal wall

		<b>Regional Lymph Nodes (N)</b>	
<input type="checkbox"/>	<input type="checkbox"/>	NX	Regional lymph nodes cannot be assessed
<input type="checkbox"/>	<input type="checkbox"/>	N0	No regional lymph node metastasis
<input type="checkbox"/>	<input type="checkbox"/>	N1	Regional lymph node metastasis

		<b>Distant Metastasis (M)</b>	
<input type="checkbox"/>	<input type="checkbox"/>	MX	Distant metastasis cannot be assessed
<input type="checkbox"/>	<input type="checkbox"/>	M0	No distant metastasis
<input type="checkbox"/>	<input type="checkbox"/>	M1	Distant metastasis
		Biopsy of metastatic site performed ..... <input type="checkbox"/> Y..... <input type="checkbox"/> N	
		Source of pathologic metastatic specimen _____	

		<b>Stage Grouping</b>			
<input type="checkbox"/>	<input type="checkbox"/>	0	Tis	N0	M0
<input type="checkbox"/>	<input type="checkbox"/>	IA	T1	N0	M0
<input type="checkbox"/>	<input type="checkbox"/>	IB	T2	N0	M0
<input type="checkbox"/>	<input type="checkbox"/>	IIA	T3	N0	M0
<input type="checkbox"/>	<input type="checkbox"/>	IIB	T1	N1	M0
			T2	N1	M0
			T3	N1	M0
<input type="checkbox"/>	<input type="checkbox"/>	III	T4	Any N	M0
<input type="checkbox"/>	<input type="checkbox"/>	IV	Any T	Any N	M1

(continued on reverse side)

**Histologic Grade (G)**

- GX Grade cannot be assessed
- G1 Well differentiated
- G2 Moderately differentiated
- G3 Poorly differentiated
- G4 Undifferentiated

**Residual Tumor (R)**

- RX Presence of residual tumor cannot be assessed
- R0 No residual tumor
- R1 Microscopic residual tumor
- R2 Macroscopic residual tumor

**Additional Descriptors**

For identification of special cases of TNM or pTNM classifications, the "m" suffix and "y," "r," and "a" prefixes are used. Although they do not affect the stage grouping, they indicate cases needing separate analysis.

- m suffix** indicates the presence of multiple primary tumors in a single site and is recorded in parentheses: pT(m)NM.
- y prefix** indicates those cases in which classification is performed during or following initial multimodality therapy. The cTNM or pTNM category is identified by a "y" prefix. The ycTNM or ypTNM categorizes the extent of tumor actually present at the time of that examination. The "y" categorization is not an estimate of tumor prior to multimodality therapy.
- r prefix** indicates a recurrent tumor when staged after a disease-free interval, and is identified by the "r" prefix: rTNM.
- a prefix** designates the stage determined at autopsy: aTNM.

**Prognostic Indicators (if applicable)**

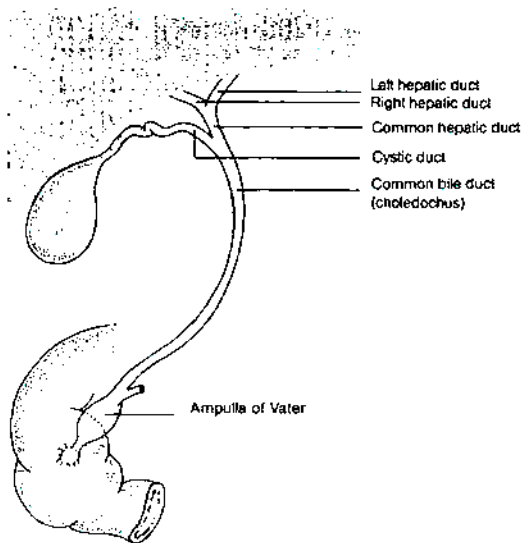
**Notes**

**Additional Descriptors**

- Lymphatic Vessel Invasion (L)**  
 LX Lymphatic vessel invasion cannot be assessed  
 L0 No lymphatic vessel invasion  
 L1 Lymphatic vessel invasion
- Venous Invasion (V)**  
 VX Venous invasion cannot be assessed  
 V0 No venous invasion  
 V1 Microscopic venous invasion  
 V2 Macroscopic venous invasion

**ILLUSTRATION**

Indicate on diagram primary tumor and regional nodes involved.



Physician's Signature \_\_\_\_\_ Date \_\_\_\_\_

## Ampulla of Vater

(Carcinoid tumors and other neuroendocrine tumors are not included.)

C24.1 Ampulla of Vater

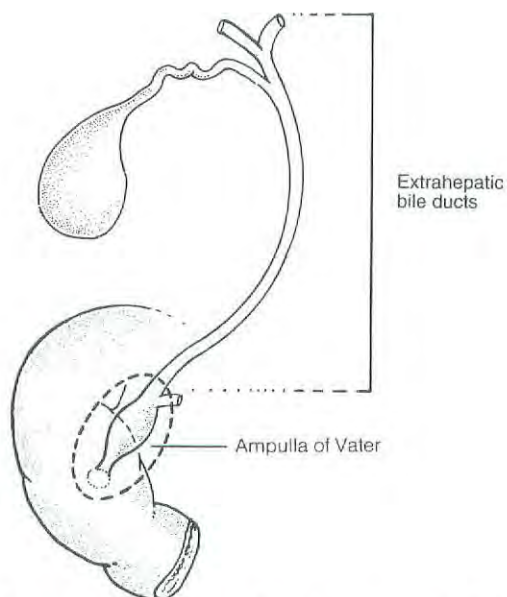
3

### SUMMARY OF CHANGES

- There is no longer a distinction between T3 and T4 on the basis of the depth of pancreatic invasion.
- The stage grouping has been revised.
- Stage I has been replaced with Stage IA and Stage IB.
- Stage II has been replaced with Stage IIA and Stage IIB.
- Node positive disease has been moved to Stage IIB to retain consistency with the staging of tumors of the bile duct and of the pancreas.

### INTRODUCTION

The ampulla of Vater is strategically located at the confluence of the pancreatic and common bile ducts (Fig. 17.1). Most tumors that arise in this small structure will obstruct the



**Fig. 17.1.** Anatomy of the ampulla of Vater, strategically located at the confluence of the pancreatic and common bile ducts.

common bile duct, causing jaundice, abdominal pain, and occasionally pancreatitis. Clinically and pathologically, carcinomas of the ampulla may be difficult to differentiate from those arising in the head of the pancreas or in the distal segment of the common bile duct. Primary cancers of the ampulla are not common, although they constitute a high proportion of malignant tumors occurring in the duodenum. Tumors of the ampulla must be differentiated from those arising in the second part of the duodenum and invading the ampulla. Carcinomas of the ampulla and periampullary region are often associated with the adenomatous polyposis coli syndrome.

### ANATOMY

**Primary Site.** The ampulla is a small dilated duct less than 1.5 cm long, formed in most individuals by the union of the terminal segments of the pancreatic and common bile ducts. In 42% of individuals, however, the ampulla is the termination of the common duct only, the pancreatic duct having its own entrance into the duodenum adjacent to the ampulla. In these individuals, the ampulla may be difficult to locate or even nonexistent. The ampulla opens into the duodenum, usually on the posterior-medial wall, through a small mucosal elevation, the duodenal papilla, which is also called the papilla of Vater. Although carcinomas can arise either in the ampulla or on the papilla, they most commonly arise near

the junction of the mucosa of the ampulla with that of the papilla. Nearly all cancers that arise in this area are well-differentiated adenocarcinomas. They have a variety of designations, including carcinoma of the ampulla of Vater, carcinoma of the periampullary portion of the duodenum, and carcinoma of the peripapillary portion of the duodenum. It may not be possible to determine the exact site of origin for large tumors.

**Regional Lymph Nodes.** A rich lymphatic network surrounds the pancreas and periampullary region, and accurate tumor staging requires that all lymph nodes that are removed be analyzed. Optimal histologic examination of a pancreaticoduodenectomy specimen should include analysis of a minimum of 10 lymph nodes. The regional lymph nodes are the peripancreatic lymph nodes, which also include the lymph nodes along the hepatic artery, celiac axis, and pyloric regions. Anatomic division of regional lymph nodes is not necessary; however, separately submitted lymph nodes should be reported as submitted.

**Metastatic Sites.** Tumors of the ampulla may infiltrate adjacent structures, such as the wall of the duodenum, the head of the pancreas, and extrahepatic bile ducts. Metastatic disease is most commonly found in the liver and peritoneum and is less commonly seen in the lungs and pleura.

## RULES FOR CLASSIFICATION

Most patients are staged pathologically after examination of the resected specimen. Classification is based primarily on local extension. The T classification depends on extension of the primary tumor through the ampulla of Vater or the sphincter of Oddi into the duodenal wall or beyond into the head of the pancreas or contiguous soft tissue. The designation T4 most commonly refers to local soft tissue invasion. Unlike the case with other solid tumors, even T4 tumors are usually locally resectable.

**Clinical Staging.** Endoscopic ultrasonography and computed tomography are effective in preoperative staging and in evaluating resectability of ampullary carcinomas. Laparoscopy is occasionally performed on patients who are believed to have localized, potentially resectable tumors to exclude peritoneal metastases and small metastases on the surface of the liver.

**Pathologic Staging.** Pathologic staging depends on surgical resection and pathologic examination of the specimen and associated lymph nodes.

*Note:* The extent of resection (R0, complete resection with grossly and microscopically negative margins of resection; R1, grossly negative but microscopically positive margins of resection; R2, grossly and microscopically positive margins

of resection) is not part of the TNM staging system but is prognostically of great significance.

## DEFINITION OF TNM

### Primary Tumor (T)

- TX Primary tumor cannot be assessed
- T0 No evidence of primary tumor
- Tis Carcinoma *in situ*
- T1 Tumor limited to ampulla of Vater or sphincter of Oddi
- T2 Tumor invades duodenal wall
- T3 Tumor invades pancreas
- T4 Tumor invades peripancreatic soft tissues or other adjacent organs or structures

### Regional Lymph Nodes (N)

- NX Regional lymph nodes cannot be assessed
- N0 No regional lymph node metastasis
- N1 Regional lymph node metastasis

### Distant Metastasis (M)

- MX Distant metastasis cannot be assessed
- M0 No distant metastasis
- M1 Distant metastasis

## STAGE GROUPING

Stage 0	Tis	N0	M0
Stage IA	T1	N0	M0
Stage IB	T2	N0	M0
Stage IIA	T3	N0	M0
Stage IIB	T1	N1	M0
	T2	N1	M0
	T3	N1	M0
Stage III	T4	Any N	M0
Stage IV	Any T	Any N	M1

## HISTOPATHOLOGIC TYPE

The staging system applies to all primary carcinomas that arise in the ampulla or on the duodenal papilla. Adenocarcinomas are the most common histologic type. The classification does not apply to carcinoid tumors or to other neuroendocrine tumors. The following histologic types are included:

- Carcinoma *in situ*
- Adenocarcinoma, NOS
- Adenocarcinoma, intestinal type
- Clear cell adenocarcinoma
- Mucinous carcinoma
- Signet ring cell carcinoma
- Squamous cell carcinoma



Adenosquamous carcinoma  
 Small cell carcinoma\*  
 Undifferentiated carcinoma\*  
   Spindle and giant cell types  
   Small cell types  
 Papillomatosis  
 Papillary carcinoma, non-invasive  
 Papillary carcinoma, invasive  
 Carcinoma, NOS  
 Other (specify)

\*Grade 4 by definition

## HISTOLOGIC GRADE (G)

GX Grade cannot be assessed  
 G1 Well differentiated  
 G2 Moderately differentiated  
 G3 Poorly differentiated  
 G4 Undifferentiated

## PROGNOSTIC FACTORS

Patients who undergo pancreaticoduodenectomy for localized periampullary adenocarcinoma of non-pancreatic origin have a superior survival duration compared with similarly treated patients who have adenocarcinoma of pancreatic origin (median survival 3–4 years compared to 18–24 months; 5-year survival 35–45% compared to 10–20%). However, as is true of the natural history of pancreatic adenocarcinoma, extent of disease and the histologic characteristics of the primary tumor predict survival duration. Even in patients who undergo a potentially curative resection, the presence of lymph node metastases, poorly differentiated histology, positive margins of resection, and tumor invasion into the pancreas are associated with a less favorable outcome. Histologic evidence of tumor extension from the ampulla into the pancreatic parenchyma appears to reflect the extent of both local and regional disease. Perineural invasion, ulceration, and high histopathologic grade are also adverse prognostic factors.

Although tumor size is not part of the TNM classification, it has prognostic significance. Tumor involvement (positivity) of resection margins has consistently been demonstrated to be an adverse prognostic factor. The residual tumor classification (R0, R1, or R2) should be reported if the margins are involved.

In contrast to the natural history of adenocarcinoma of pancreatic origin, lymph node metastasis in patients with adenocarcinoma of the ampulla of Vater are not as powerful a predictor of disease recurrence or short survival duration. The actuarial 5-year survival following potentially curative surgery in node-positive patients with pancreatic adenocarcinoma is 0–5%; in those with ampullary adenocarcinoma

it is 15–30%. Tumors with papillary histology have a better outcome than non-papillary tumors.

## BIBLIOGRAPHY

- Allema JH, Reinders ME, van Gulik TM, et al: Prognostic factors for survival after pancreaticoduodenectomy for patients with carcinoma of the pancreatic head region. *Cancer* 75:2069–2076, 1995
- Bakkevold KE, Kambestad B: Long-term survival following radical and palliative treatment of patients with carcinoma of the pancreas and papilla of Vater—the prognostic factors influencing the long-term results: a prospective multicentre study. *Eur J Surg Oncol* 19:147–161, 1993
- Bakkevold KE, Kambestad B: Staging of carcinoma of the pancreas and ampulla of Vater: tumor (T), lymph node (N), and distant metastasis (M) as prognostic factors. *Int J Pancreatol* 17:249–259, 1995
- Beger HG, Treitschke F, Gansauge F, et al: Tumor of the ampulla of Vater. *Arch Surg* 134:526–532, 1999
- Bottger TC, Boddin J, Heintz A, et al: Clinicopathologic study for the assessment of resection for ampullary carcinoma. *World J Surg* 21:379–383, 1997
- Compton CC: Protocol for the examination of specimens from patients with carcinoma of the ampulla of Vater. *Arch Pathol Lab Med*. 121:673–677, 1997
- Cubilla AL, Fitzgerald PJ: Tumors of the exocrine pancreas. In *Atlas of tumor pathology*, 2nd series, fascicle 19, Washington, DC: Armed Forces Institute of Pathology, 1984
- Delcore R Jr, Connor CS, Thomas JH, et al: Significance of tumor spread in adenocarcinoma of the ampulla of Vater. *Am J Surg* 158:593–596, 1989
- Dorandeu A, Raoul J-L, Sisier F, Leclercq-Rioux N, et al: Carcinoma of the ampulla of Vater: prognostic factors after curative surgery: a series of 45 cases. *Gut* 40:350–355, 1997
- Griffanti-Bartoli F, Arnone GB, Ceppa P, et al: Malignant tumors in the head of the pancreas and the periampullary region: diagnostic and prognostic aspects. *Anticancer Res* 14:657–666, 1994
- Harada N, Treitschke F, Imaizumi T, Beger HG: Pancreatic invasion is a prognostic indicator after radical resection for carcinoma of the ampulla of Vater. *J Hep Bil Pancr Surg* 4:215–219, 1997
- Howe JR, Klimstra DS, Moccia RD, et al: Factors predictive of survival in ampullary carcinoma. *Ann Surg* 228:87–94, 1998
- Kayahara M, Nagakawa T, Ohta T, Kitagawa H, Miyazaki I: Surgical strategy for carcinoma of the papilla of Vater on the basis of lymphatic spread and mode of recurrence. *Surgery* 121:611–617, 1997
- Klempnauer J, Ridder GH, Bektas H, et al: Surgery for exocrine pancreatic cancer—who are the 5- and 10-year survivors? *Oncology* 52:353–359, 1995
- Knox RA, Kingston RD: Carcinoma of the ampulla of Vater. *Br J Surg* 73:72–73, 1976
- Lee JH, Whittington R, Williams NN, et al: Outcome of pancreaticoduodenectomy and impact of adjuvant therapy for ampullary carcinomas. *Int J Radiat Oncol Biol Phys* 47:945–953, 2000
- Makipour H, Cooperman A, Danzi JT, et al: Carcinoma of the ampulla of Vater. *Ann Surg* 183:341–344, 1976
- Martin MF, Rossi RL, Dorucci V, et al: Clinical and pathologic correlations in patients with periampullary tumors. *Arch Surg* 125:723–726, 1990

Monson JRT, Donohue JH, McEntee GP, et al: Radical resection for carcinoma of the ampulla of Vater. *Arch Surg* 126:353-357, 1991

Mori K, Ikei S, Yamane T, et al: Pathological factors influencing survival of carcinoma of the ampulla of Vater. *Eur J Surg Oncol* 16:183-188, 1990

Nelptolemos JP, Talbot IC, Shaw DC, et al: Long-term survival after resection of ampullary carcinoma is associated independently with tumor grade and a new staging classification that assesses local invasiveness. *Cancer* 61:1403-1407, 1988

Roberts RH, Krige JE, Bornman PC, Terblanche J. Pancreaticoduodenectomy of ampullary carcinoma. *Am Surg* 65:1043-1048, 1999

Shirai Y, Tsukada K, Ohtani T, et al: Carcinoma of the ampulla of Vater: histopathologic analysis of tumor spread in Whipple pancreatoduodenectomy specimens. *World J Surg* 19:102-107, 1995

Talamini MA, Moesinger RC, Pitt HA, et al: Adenocarcinoma of the ampulla of Vater: a 28-year experience. *Ann Surg* 225:590-600, 1997

Willett CG, Warshaw AL, Convery K, et al: Patterns of failure after pancreaticoduodenectomy for ampullary carcinoma. *Surg Gynecol Obstet* 176:33-38, 1993

Wise L, Pizzimbono C, Dehner IP: Periampullary cancer. *Am J Surg* 131:141-148, 1976

Yamaguchi K, Enjoji M: Carcinoma of the ampulla of Vater: a clinicopathologic study and pathologic staging of 109 cases

of carcinoma and 5 cases of adenoma. *Cancer* 59:506-515, 1987

Yasuda K, Mukai H, Cho E, et al: The use of endoscopic ultrasonography in the diagnosis and staging of carcinoma of the papilla of Vater. *Endoscopy* 20(Suppl):218-222, 1988

### HISTOLOGIES—AMPULLA OF VATER

8010/2	Carcinoma <i>in situ</i> , NOS
8010/3	Carcinoma, NOS
8020/3	Undifferentiated carcinoma
8032/3	Spindle cell carcinoma, NOS
8041/3	Small cell carcinoma, NOS
8042/3	Oat cell carcinoma
8070/3	Squamous cell carcinoma, NOS
8140/2	Adenocarcinoma <i>in situ</i> , NOS
8140/3	Adenocarcinoma, NOS
8144/3	Adenocarcinoma, intestinal type
8210/2	Adenocarcinoma <i>in situ</i> in adenomatous polyp
8210/3	Adenocarcinoma in adenomatous polyp
8255/3	Adenocarcinoma with mixed subtypes
8260/3	Papillary adenocarcinoma, NOS
8261/3	Adenocarcinoma in villous adenoma
8310/3	Clear cell adenocarcinoma, NOS
8480/3	Mucinous adenocarcinoma
8481/3	Mucin-producing adenocarcinoma
8490/3	Signet ring cell carcinoma
8560/3	Adenosquamous carcinoma

**AMPULLA OF VATER**

**Hospital Name/Address**

**Patient Name/Information**

Type of Specimen \_\_\_\_\_

Histopathologic Type \_\_\_\_\_

Tumor Size \_\_\_\_\_

**3**

**DEFINITIONS**

<i>Clinical</i>	<i>Pathologic</i>	<b>Primary Tumor (T)</b>	
<input type="checkbox"/>	<input type="checkbox"/>	TX	Primary tumor cannot be assessed
<input type="checkbox"/>	<input type="checkbox"/>	T0	No evidence of primary tumor
<input type="checkbox"/>	<input type="checkbox"/>	Tis	Carcinoma <i>in situ</i>
<input type="checkbox"/>	<input type="checkbox"/>	T1	Tumor limited to ampulla of Vater or sphincter of Oddi
<input type="checkbox"/>	<input type="checkbox"/>	T2	Tumor invades duodenal wall
<input type="checkbox"/>	<input type="checkbox"/>	T3	Tumor invades pancreas
<input type="checkbox"/>	<input type="checkbox"/>	T4	Tumor invades peripancreatic soft tissues or other adjacent organs or structures

<i>Clinical</i>	<i>Pathologic</i>	<b>Regional Lymph Nodes (N)</b>	
<input type="checkbox"/>	<input type="checkbox"/>	NX	Regional lymph nodes cannot be assessed
<input type="checkbox"/>	<input type="checkbox"/>	N0	No regional lymph node metastasis
<input type="checkbox"/>	<input type="checkbox"/>	N1	Regional lymph node metastasis

<i>Clinical</i>	<i>Pathologic</i>	<b>Distant Metastasis (M)</b>	
<input type="checkbox"/>	<input type="checkbox"/>	MX	Distant metastasis cannot be assessed
<input type="checkbox"/>	<input type="checkbox"/>	M0	No distant metastasis
<input type="checkbox"/>	<input type="checkbox"/>	M1	Distant metastasis

Biopsy of metastatic site performed ..... Y ..... N

Source of pathologic metastatic specimen \_\_\_\_\_

<i>Clinical</i>	<i>Pathologic</i>	<b>Stage Grouping</b>			
<input type="checkbox"/>	<input type="checkbox"/>	0	Tis	N0	M0
<input type="checkbox"/>	<input type="checkbox"/>	IA	T1	N0	M0
<input type="checkbox"/>	<input type="checkbox"/>	IB	T2	N0	M0
<input type="checkbox"/>	<input type="checkbox"/>	IIA	T3	N0	M0
<input type="checkbox"/>	<input type="checkbox"/>	IIB	T1	N1	M0
			T2	N1	M0
			T3	N1	M0
<input type="checkbox"/>	<input type="checkbox"/>	III	T4	Any N	M0
<input type="checkbox"/>	<input type="checkbox"/>	IV	Any T	Any N	M1

*(continued on reverse side)*

**Histologic Grade (G)**

- GX Grade cannot be assessed
- G1 Well differentiated
- G2 Moderately differentiated
- G3 Poorly differentiated
- G4 Undifferentiated

**Residual Tumor (R)**

- RX Presence of residual tumor cannot be assessed
- R0 No residual tumor
- R1 Microscopic residual tumor
- R2 Macroscopic residual tumor

**Additional Descriptors**

For identification of special cases of TNM or pTNM classifications, the "m" suffix and "y," "r," and "a" prefixes are used. Although they do not affect the stage grouping, they indicate cases needing separate analysis.

- m suffix** indicates the presence of multiple primary tumors in a single site and is recorded in parentheses: pT(m)NM.
- y prefix** indicates those cases in which classification is performed during or following initial multimodality therapy. The cTNM or pTNM category is identified by a "y" prefix. The ycTNM or ypTNM categorizes the extent of tumor actually present at the time of that examination. The "y" categorization is not an estimate of tumor prior to multimodality therapy.
- r prefix** indicates a recurrent tumor when staged after a disease-free interval, and is identified by the "r" prefix: rTNM.
- a prefix** designates the stage determined at autopsy: aTNM.

**Prognostic Indicators (if applicable)**

**Notes**

**Additional Descriptors**

**Lymphatic Vessel Invasion (L)**

- LX Lymphatic vessel invasion cannot be assessed
- L0 No lymphatic vessel invasion
- L1 Lymphatic vessel invasion

**Venous Invasion (V)**

- VX Venous invasion cannot be assessed
- V0 No venous invasion
- V1 Microscopic venous invasion
- V2 Macroscopic venous invasion

Physician's Signature \_\_\_\_\_

Date \_\_\_\_\_

## Exocrine Pancreas

*(Endocrine tumors arising from the islets of Langerhans and carcinoid tumors are not included.)*

C25.0 Head of pancreas  
C25.1 Body of pancreas  
C25.2 Tail of pancreas

C25.3 Pancreatic duct  
C25.7 Other specified parts of pancreas

C25.8 Overlapping lesion of pancreas  
C25.9 Pancreas, NOS

### SUMMARY OF CHANGES

- The T classification reflects the distinction between potentially resectable (T3) and locally advanced (T4) primary pancreatic tumors.
- Stage grouping has been changed to allow Stage III to signify unresectable, locally advanced pancreatic cancer, while Stage IV is reserved for patients with metastatic disease.

### INTRODUCTION

In the United States, pancreatic cancer is the second most common malignant tumor of the gastrointestinal tract and the fifth leading cause of cancer-related death in adults. The disease is difficult to diagnose, especially in its early stages. Most pancreatic cancers arise in the head of the pancreas, often causing bile duct obstruction that results in clinically evident jaundice. Cancers that arise in either the body or the tail of the pancreas are insidious in their development and often far advanced when first detected. Most pancreatic cancers are adenocarcinomas, which usually originate from the pancreatic duct cells. Surgical resection remains the only potentially curative approach, although multimodality therapy that includes innovative systemic agents and often radiation therapy is available.

Staging of exocrine pancreatic cancers depends on the size and extent of the primary tumor. This TNM classification does not apply to endocrine tumors.

### ANATOMY

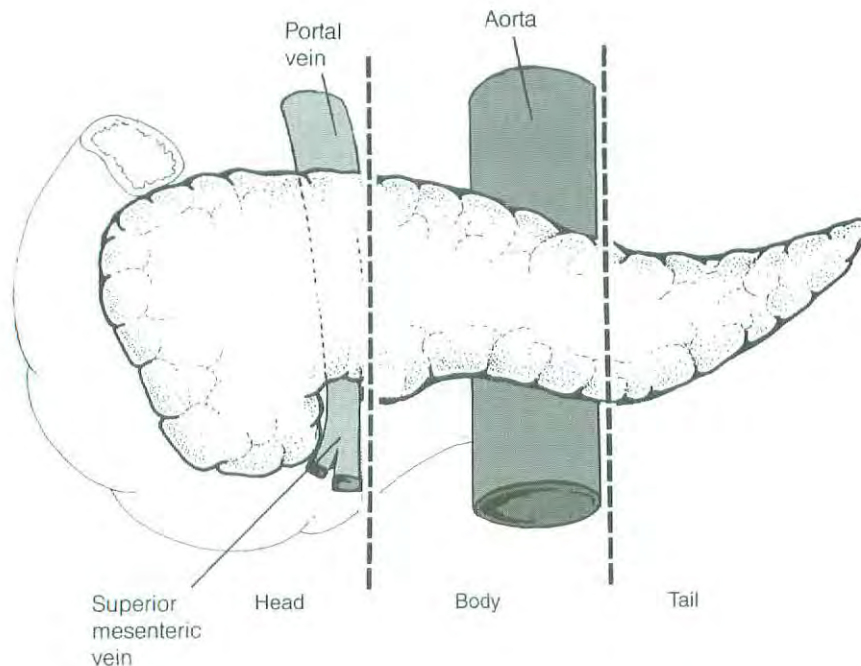
**Primary Site.** The pancreas is a long, coarsely lobulated gland that lies transversely across the posterior abdomen and extends from the duodenum to the splenic hilum. The organ is divided into a head with a small uncinat process, a neck, a body, and a tail. The anterior aspect of the body of the pancreas is in direct contact with the posterior wall of the stomach; posteriorly, the pancreas extends to the aorta, splenic vein, and left kidney.

**Regional Lymph Nodes.** A rich lymphatic network surrounds the pancreas, and accurate tumor staging requires that all lymph nodes that are removed be analyzed. Optimal histologic examination of a pancreaticoduodenectomy specimen should include analysis of a minimum of 10 lymph nodes, although pathologic analysis of at least 10 lymph nodes may still result in a pN0 designation. The regional lymph nodes are the peripancreatic lymph nodes, which also include the lymph nodes along the hepatic artery, the celiac axis, and the pyloric and splenic regions. Anatomic division of regional lymph nodes is not necessary; however, separately submitted lymph nodes should be reported as submitted.

**Metastatic Sites.** Distant spread occurs commonly to the liver, peritoneal cavity, and lungs. Metastases to other sites are uncommon (or rarely detected), possibly because of the short interval from diagnosis of distant metastases to death.

### DEFINITION OF LOCATION

Tumors of the head of the pancreas are those arising to the right of the superior mesenteric–portal vein confluence (Fig. 18.1). The uncinat process is part of the pancreatic head. Tumors of the body of the pancreas are roughly defined as those arising between the superior mesenteric–portal vein confluence and the aorta. Tumors of the tail of the pancreas are those arising between the aorta and the hilum of the spleen.



**Fig. 18.1.** Tumors of the head of the pancreas are those arising to the right of the superior mesenteric–portal vein confluence.

## RULES FOR CLASSIFICATION

Because only a minority of patients with pancreatic cancer undergo surgical resection of the pancreas (and adjacent lymph nodes), a single TNM classification must apply to both clinical and pathologic staging.

## RULES FOR CLASSIFICATION AND CHANGES FROM THE FIFTH EDITION

Since only a minority of patients with pancreatic cancer undergo surgical resection of the pancreas (and adjacent lymph nodes), a single TNM classification must apply to both clinical and pathologic staging. In this edition of the *AJCC Cancer Staging Manual*, the editorial consultants have attempted to combine clinical and pathologic staging to address the following problems presented by previous editions:

1. We have changed the T classification to a more clinically relevant system, based upon both preoperative CT-assessment of resectability and final pathologic evaluation of the resected specimen. It is important to distinguish between resectable (T1, T2, and T3) and locally advanced (T4) primary tumors. Pancreatic tumors are judged unresectable when they cannot be separated (on high-quality CT images) from the adjacent large arterial structures (celiac axis or superior mesenteric artery). It would be unusual for an exocrine pancreatic cancer to exhibit local tumor extension to the retroperitoneum or adjacent structures, which would preclude surgical resection, in the absence of arterial involvement. Tumor involvement of the su-

perior mesenteric or portal veins is classified as T3 in the current AJCC T classification; such tumors are considered resectable in some centers and there are few data on the prognostic value of venous invasion. The distinction between T3 and T4 in this chapter reflects the distinction between potentially resectable (T3) and locally advanced (T4) primary pancreatic tumors, both of which demonstrate radiographic or pathologic evidence of extrapancreatic tumor extension.

2. In the fifth edition, patients with unresectable T3 primary tumors were considered to have stage II disease (the lymph node status was unknown since no surgical resection was performed); in contrast, a patient with a 1-cm primary tumor and 1 positive regional lymph node who had undergone pancreaticoduodenectomy would be classified as having stage III disease. We acknowledge the prognostic importance of positive lymph nodes, but in general, patients with completely resected (R0 or R1; see below) N1 pancreatic cancer have a superior survival duration compared to patients with locally advanced (unresectable) or metastatic disease. Therefore, in the current edition, we reserve stage III for patients with unresectable, locally advanced pancreatic cancer.

It is important to note that the extent of resection (R0, complete resection with grossly and microscopically negative margins of resection; R1, grossly negative but positive microscopically margins of resection; R2, grossly and microscopically positive margins of resection) is not part of the TNM staging system but is prognostically of great significance.

**Clinical Staging.** Information necessary for the clinical staging of exocrine pancreatic cancer can be obtained from a physical examination and high-quality computed tomography (CT) images. The standard imaging procedure for pancreatic neoplasms is contrast-enhanced multislice CT (arterial and venous phases of contrast enhancement). On the basis of the interpretation of CT images and chest radiographs, patients can be classified as having localized resectable (Stage I or II), locally advanced (Stage III), or metastatic (Stage IV) pancreatic cancer. Endoscopic ultrasonography (when done by experienced gastroenterologists) also provides information helpful for clinical staging and is the procedure of choice for performing fine-needle aspiration biopsy of the pancreas. Laparoscopy is commonly performed on patients believed to have localized, potentially resectable tumors to exclude peritoneal metastases and small metastases on the surface of the liver. Laparoscopy will reveal tiny (<1 cm) peritoneal or liver metastases and up-stage (to Stage IV) approximately 10% of patients with tumors in the pancreatic head, and up to 40% of patients with tumors in the body and tail, who had been believed to have Stage I or Stage II disease on the basis of CT alone. Endoscopic retrograde cholangiopancreatography and placement of an endobiliary stent are commonly performed in patients with biliary obstruction.

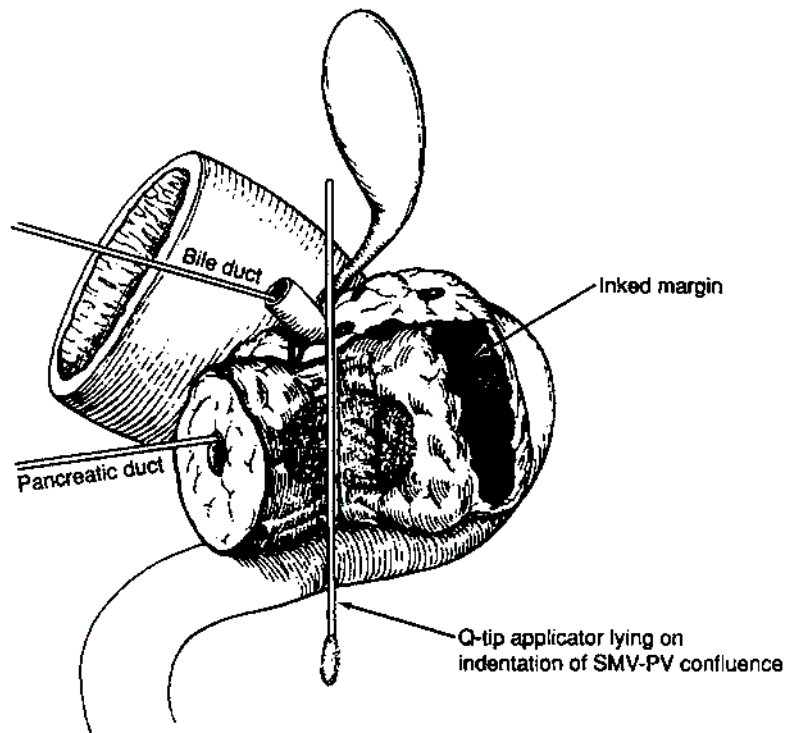
**Pathologic Staging.** Partial resection (pancreaticoduodenectomy or distal pancreatectomy) or complete resection of the pancreas, including the tumor and associated regional

lymph nodes, provides the information necessary for pathologic staging.

In pancreaticoduodenectomy specimens, the bile duct, pancreatic duct, and retroperitoneal margins should be evaluated grossly and microscopically. In total pancreatectomy specimens, the bile duct and retroperitoneal margins should be assessed. Duodenal (with pylorus-preserving pancreaticoduodenectomy) and gastric (with standard pancreaticoduodenectomy) margins are rarely involved, but their status should be included in the surgical pathology report. Reporting of margins may be facilitated by use of the following checklist:

<i>Surgical Margin</i>	<i>Status</i>
Common bile (hepatic) duct	
Pancreatic neck	
Retroperitoneal margin	
Other soft tissue margins (such as posterior pancreatic)	
Duodenum	
Stomach	

Particular attention should be paid to the retroperitoneal (also referred to as the mesenteric or uncinete) pancreatic margin (soft tissue that often contains perineural tissue adjacent to the superior mesenteric artery; see Fig. 18.2)



**Fig. 18.2.** The retroperitoneal (also referred to as the mesenteric or uncinete) pancreatic margin (soft tissue that often contains perineural tissue adjacent to the superior mesenteric artery).

because most local recurrences arise in the pancreatic bed along this critical margin. The soft tissue between the anterior surface of the inferior vena cava and the posterior aspect of the pancreatic head and duodenum is best referred to as the posterior pancreatic margin (not the retroperitoneal margin). The retroperitoneal margin should be inked as part of the gross evaluation of the specimen; the specimen is then cut perpendicular to the inked margin for histologic analysis. The closest microscopic approach of the tumor to the margin should be recorded in millimeters.

Seeding of the peritoneum (even if limited to the lesser sac region) is considered M1. Similarly, peritoneal fluid that contains cytologic (microscopic) evidence of carcinoma is considered M1. In patients without ascites, the implications of positive peritoneal cytology are not clear at this time, although the available data suggest that this finding predicts a short survival. Therefore, positive peritoneal cytology is also considered M1.

*Note:* The extent of resection (R0, complete resection with grossly and microscopically negative margins of resection; R1, grossly negative but microscopically positive margins of resection; R2, grossly and microscopically positive margins of resection) is not part of the TNM staging system but is prognostically of great significance.

## DEFINITION OF TNM

### Primary Tumor (T)

- TX Primary tumor cannot be assessed
- T0 No evidence of primary tumor
- Tis Carcinoma *in situ*\*
- T1 Tumor limited to the pancreas, 2 cm or less in greatest dimension
- T2 Tumor limited to the pancreas, more than 2 cm in greatest dimension
- T3 Tumor extends beyond the pancreas but without involvement of the celiac axis or the superior mesenteric artery
- T4 Tumor involves the celiac axis or the superior mesenteric artery (unresectable primary tumor)

### Regional Lymph Nodes (N)

- NX Regional lymph nodes cannot be assessed
- N0 No regional lymph node metastasis
- N1 Regional lymph node metastasis

### Distant Metastasis (M)

- MX Distant metastasis cannot be assessed
- M0 No distant metastasis
- M1 Distant metastasis

\*This also includes the "PanInIII" classification

## STAGE GROUPING

Stage 0	Tis	N0	M0
Stage IA	T1	N0	M0
Stage IB	T2	N0	M0
Stage IIA	T3	N0	M0
Stage IIB	T1	N1	M0
	T2	N1	M0
	T3	N1	M0
Stage III	T4	Any N	M0
Stage IV	Any T	Any N	M1

## HISTOPATHOLOGIC TYPE

The staging system applies to all exocrine carcinomas that arise in the pancreas. It does not apply to endocrine tumors, which usually arise from the islets of Langerhans. Carcinoid tumors are also excluded. More than 90% of malignant tumors of the pancreas are exocrine carcinomas. The following carcinomas are included:

- Severe ductal dysplasia/carcinoma *in situ* (PanIn III; pancreatic intraepithelial neoplasia)
- Ductal adenocarcinoma
- Mucinous noncystic carcinoma
- Signet ring cell carcinoma
- Adenosquamous carcinoma
- Undifferentiated carcinoma
  - Spindle and giant cell types
  - Small cell types
- Mixed ductal-endocrine carcinoma
- Osteoclast-like giant cell tumor
- Serous cystadenocarcinoma
- Mucinous cystadenocarcinoma
- Intraductal papillary mucinous carcinoma with or without invasion (IPMN)
- Acinar cell carcinoma
- Acinar cell cystadenocarcinoma
- Mixed acinar-endocrine carcinoma
- Pancreaticoblastoma
- Solid pseudopapillary carcinoma
- Borderline (uncertain malignant potential) tumors
  - Mucinous cystic tumor with moderate dysplasia
  - Intraductal papillary-mucinous tumor with moderate dysplasia
  - Solid pseudopapillary tumor
- Other

## HISTOLOGIC GRADE (G)

- GX Grade cannot be assessed
- G1 Well differentiated
- G2 Moderately differentiated
- G3 Poorly differentiated
- G4 Undifferentiated



## PROGNOSTIC FACTORS

Patients who undergo surgical resection for localized non-metastatic adenocarcinoma of the pancreas have a long-term survival rate of approximately 20% and a median survival of 12–20 months. Patients with locally advanced, non-metastatic disease have a median survival of 6–10 months. Patients with metastatic disease have a short survival (3–6 months), the length of which depends on the extent of disease and performance status.

A number of investigators have examined pathologic factors of the resected tumor (in patients with apparently localized, resectable pancreatic cancer) in an effort to establish reliable prognostic variables associated with decreased survival duration. Metastatic disease in regional lymph nodes, poorly differentiated histology, and increased size of the primary tumor have been associated with decreased survival duration. The prognostic factor of greatest significance for decreased survival duration in patients who undergo pancreaticoduodenectomy is incomplete resection. Therefore, margin assessment is of major importance in the gross and microscopic evaluation of the pancreaticoduodenectomy specimen. Retrospective pathologic analysis of archival material does not allow accurate assessment of the margins of resection or of the number of lymph nodes retrieved; this information must be obtained when the specimen is removed and examined in the surgical pathology laboratory. The margin of resection most likely to be positive is the retroperitoneal (or mesenteric) margin along the right lateral border of the superior mesenteric artery. This margin is defined as the soft tissue margin directly adjacent to the proximal 3–4 cm of the superior mesenteric artery and is inked for evaluation of margin status on permanent-section histologic evaluation (see the “Pathologic Staging” section). Incomplete resection resulting in a grossly positive retroperitoneal margin provides no survival advantage from surgical resection (compared to those who receive chemoradiation and no surgery).

## BIBLIOGRAPHY

- Albores-Saavedra J, Heffess C, Hruban RH, et al: Recommendations for the reporting of pancreatic specimens containing malignant tumors. *Am J Clin Pathol* 111:304–307, 1999
- Association of Directors of Anatomic and Surgical Pathology: Recommendations for the reporting of pancreatic specimens containing malignant tumors. *Hum Pathol* 29:893–895, 1998
- Birkmeyer JD, Finlayson SR, Tosteson AN, et al: Effect of hospital volume on in-hospital mortality with pancreaticoduodenectomy. *Surgery* 125:250–256, 1999
- Birkmeyer JD, Warshaw AL, Finlayson SR, et al: Relationship between hospital volume and late survival after pancreaticoduodenectomy. *Surgery* 126:178–183, 1999
- Bold RJ, Charnsangavej C, Cleary KR, et al: Major vascular resection as part of pancreaticoduodenectomy for cancer: radiologic, intraoperative, and pathologic analysis. *J Gastrointest Surg* 3:233–243, 1999
- Compton CC, Henson DE: Protocol for the examination of specimens removed from patients with carcinoma of the exocrine pancreas: a basis for checklists. *Arch Pathol Lab Med* 121:1129–1136, 1997
- Conlon KC, Klimstra DS, Brennan MF: Long-term survival after curative resection for pancreatic ductal adenocarcinoma: clinicopathologic analysis of 5-year survivors. *Ann Surg* 223:273–279, 1996
- Cubilla AL, Fitzgerald PJ: Tumors of the exocrine pancreas. In *Atlas of tumor pathology, 2nd series, fascicle 19*, Washington DC: Armed Forces Institute of Pathology, 1984
- Cubilla AL, Fortner J, Fitzgerald PJ: Lymph node involvement in carcinoma of the head of the pancreas area. *Cancer* 41:880–887, 1978
- Evans DB, Abbruzzese JL, Willett CG: Cancer of the pancreas. In DeVita VT, Hellman S, Rosenberg SA (Eds): *Cancer, principles and practice of oncology*, 6th ed. Philadelphia: J.B. Lippincott, 2002
- Evans DB, Lee JE, Pisters PWT: Pancreaticoduodenectomy (Whipple operation) and total pancreatectomy for cancer. In Nyhus LM, Baker RJ, Fischer JF (Eds.): *Mastery of surgery*, 3rd ed. Boston: Little, Brown, 1233–1249, 1997
- Fuhrman GM, Charnsangavej C, Abbruzzese JL, et al: Thin-section contrast-enhanced computed tomography accurately predicts resectability of malignant pancreatic neoplasms. *Am J Surg* 167:104–111, 1994
- Geer RJ, Brennan MF: Prognostic indicators for survival after resection of pancreatic adenocarcinoma. *Am J Surg* 165:68–72, 1993
- Gold EB, Goldin SB: Epidemiology of and risk factors for pancreatic cancer. *Surg Oncol Clin N Am* 7:67–91, 1998
- Greenlee RT, Murray T, Bolden S, et al: Cancer statistics, 2000. *CA Cancer J Clin* 50:7–13, 2000
- Griffin JF, Smalley SR, Jewell W: Patterns of failure after curative resection of pancreatic carcinoma. *Cancer* 66:56–61, 1990
- Kloppel G, Hruban RH, Longnecker DS, Adler G, Kern SE, Partanen TJ: Ductal adenocarcinoma of the pancreas. In Hamilton SR, Aaltonen LA, eds. *World Health Organization Classification of Tumors: Pathology and Genetics, Tumors of the Digestive System*. Lyon, IARC Press, 2000, pp 221–230.
- Leach SD, Lee JE, Charnsangavej C, et al: Survival following pancreaticoduodenectomy with resection of the superior mesenteric–portal vein confluence for adenocarcinoma of the pancreatic head. *Br J Surg* 85:611–617, 1998
- Millikan KW, Deziel DJ, Silverstein JC, et al: Prognostic factors associated with resectable adenocarcinoma of the head of the pancreas. *Am Surg* 65:618–624, 1999
- Nitecki SS, Sarr MG, Colby TV, et al: Long-term survival after resection for ductal adenocarcinoma of the pancreas: is it really improving? *Ann Surg* 221:59–66, 1995
- Pedrazzoli S, Bger HG, Obertop H, et al: A surgical and pathological based classification of resective treatment of pancreatic cancer. *Dig Surg* 16:337–345, 1999
- Sohn TA, Yeo CJ, Cameron JL, et al: Resected adenocarcinoma of the pancreas—616 patients: results, outcomes, and prognostic indicators. *J Gastrointest Surg* 4:567–579, 2000.
- Staley C, Cleary K, Abbruzzese J, et al: Need for standardized pathologic staging of pancreaticoduodenectomy specimens. *Pancreas* 12:373–380, 1996
- Suits J, Frazee R, Erickson RA: Endoscopic ultrasound and fine-needle aspiration for the valuation of pancreatic masses. *Arch Surg* 134:639–643, 1999
- Traverso LW, Longmire WP Jr: Preservation of the pylorus in pancreaticoduodenectomy. *Surg Gynecol Obstet* 146:959–962, 1978

Tyler DS, Evans DB: Reoperative pancreaticoduodenectomy. *Ann Surg* 219:211–221, 1994

Westerdahl J, Andrén-Sandberg Å, Ihse I: Recurrence of exocrine pancreatic cancer—local or hepatic? *Hepatogastroenterology* 40:384–387, 1993

Whipple AO, Parsons WW, Mullin CR: Treatment of carcinoma of the ampulla of Vater. *Ann Surg* 102:763–269, 1935

Willett CG, Lewandrowski K, Warshaw AL, et al: Resection margins in carcinoma of the head of the pancreas: implications for radiation therapy. *Ann Surg* 217:144–148, 1993

Yeo CJ, Cameron JL, Sohn TA, et al: Six hundred fifty consecutive pancreaticoduodenectomies in the 1990s: pathology, complications, and outcomes. *Ann Surg* 226:248–257, 1997

8044/3 Small cell carcinoma, intermediate cell

8045/3 Combined small cell carcinoma

8046/3 Non-small cell carcinoma

8070/2 Squamous cell carcinoma *in situ*, NOS

8070/3 Squamous cell carcinoma, NOS

8140/3 Adenocarcinoma, NOS

8141/3 Scirrhus adenocarcinoma

8144/3 Adenocarcinoma, intestinal type

8145/3 Carcinoma, diffuse type

8148/2 Glandular intraepithelial neoplasia, grade III

8154/3 Mixed acinar-endocrine carcinoma

8154/3 Mixed ductal-endocrine carcinoma

8214/3 Parietal cell carcinoma

8246/3 Neuroendocrine carcinoma, NOS

8255/3 Adenocarcinoma with mixed subtypes

8260/3 Papillary adenocarcinoma, NOS

8310/3 Clear cell adenocarcinoma, NOS

8320/3 Granular cell carcinoma

8430/3 Mucoepidermoid carcinoma

8441/3 Serous cystadenocarcinoma

8452/3 Solid pseudopapillary carcinoma

8453/2 Intraductal papillary-mucinous carcinoma, non-invasive

8453/3 Intraductal papillary-mucinous carcinoma, invasive

8470/3 Mucinous cystadenocarcinoma

8480/3 Mucinous adenocarcinoma

8481/3 Mucin-producing adenocarcinoma

8490/3 Signet ring cell carcinoma

8500/3 Ductal adenocarcinoma

8550/3 Acinar cell carcinoma

8551/3 Acinar cell cystadenocarcinoma

8560/3 Adenosquamous carcinoma

8971/3 Pancreaticoblastoma

## HISTOLOGIES—EXOCRINE PANCREAS

8010/2 Carcinoma *in situ*, NOS

8010/3 Carcinoma, NOS

8012/3 Large cell carcinoma, NOS

8013/3 Large cell neuroendocrine carcinoma

8014/3 Large cell carcinoma with rhabdoid phenotype

8020/3 Carcinoma, undifferentiated, NOS

8020/3 Undifferentiated carcinoma

8021/3 Carcinoma, anaplastic, NOS

8022/3 Pleomorphic carcinoma

8030/3 Giant cell and spindle cell carcinoma

8031/3 Giant cell carcinoma

8032/3 Spindle cell carcinoma, NOS

8035/3 Osteoclast-like giant cell tumor

8041/3 Small cell carcinoma, NOS

8042/3 Oat cell carcinoma

8043/3 Small cell carcinoma, fusiform cell

## EXOCRINE PANCREAS

Hospital Name/Address
-----------------------

Patient Name/Information
--------------------------

Type of Specimen \_\_\_\_\_  
Tumor Size \_\_\_\_\_

Histopathologic Type \_\_\_\_\_

3

### DEFINITIONS

Clinical	Pathologic	Primary Tumor (T)	
<input type="checkbox"/>	<input type="checkbox"/>	TX	Primary tumor cannot be assessed
<input type="checkbox"/>	<input type="checkbox"/>	T0	No evidence of primary tumor
<input type="checkbox"/>	<input type="checkbox"/>	Tis	Carcinoma <i>in situ</i>
<input type="checkbox"/>	<input type="checkbox"/>	T1	Tumor limited to the pancreas 2 cm or less in greatest dimension
<input type="checkbox"/>	<input type="checkbox"/>	T2	Tumor limited to the pancreas more than 2 cm in greatest dimension
<input type="checkbox"/>	<input type="checkbox"/>	T3	Tumor extends beyond the pancreas but without involvement of the celiac axis or the superior mesenteric artery
<input type="checkbox"/>	<input type="checkbox"/>	T4	Tumor involves the celiac axis or the superior mesenteric artery (unresectable primary tumor)

Clinical	Pathologic	Regional Lymph Nodes (N)	
<input type="checkbox"/>	<input type="checkbox"/>	NX	Regional lymph nodes cannot be assessed
<input type="checkbox"/>	<input type="checkbox"/>	N0	No regional lymph node metastasis
<input type="checkbox"/>	<input type="checkbox"/>	N1	Regional lymph node metastasis

Clinical	Pathologic	Distant Metastasis (M)	
<input type="checkbox"/>	<input type="checkbox"/>	MX	Distant metastasis cannot be assessed
<input type="checkbox"/>	<input type="checkbox"/>	M0	No distant metastasis
<input type="checkbox"/>	<input type="checkbox"/>	M1	Distant metastasis

Biopsy of metastatic site performed .....  Y .....  N

Source of pathologic metastatic specimen \_\_\_\_\_

Clinical	Pathologic	Stage Grouping	
<input type="checkbox"/>	<input type="checkbox"/>	0	Tis      N0      M0
<input type="checkbox"/>	<input type="checkbox"/>	IA	T1      N0      M0
<input type="checkbox"/>	<input type="checkbox"/>	IB	T2      N0      M0
<input type="checkbox"/>	<input type="checkbox"/>	IIA	T3      N0      M0
<input type="checkbox"/>	<input type="checkbox"/>	IIB	T1      N1      M0
			T2      N1      M0
			T3      N1      M0
<input type="checkbox"/>	<input type="checkbox"/>	III	T4      Any N      M0
<input type="checkbox"/>	<input type="checkbox"/>	IV	Any T      Any N      M1

*(continued on reverse side)*

**Histologic Grade (G)**

- GX Grade cannot be assessed
- G1 Well differentiated
- G2 Moderately differentiated
- G3 Poorly differentiated
- G4 Undifferentiated

**Residual Tumor (R)**

- RX Presence of residual tumor cannot be assessed
- R0 No residual tumor
- R1 Microscopic residual tumor
- R2 Macroscopic residual tumor

**Additional Descriptors**

For identification of special cases of TNM or pTNM classifications, the "m" suffix and "y," "r," and "a" prefixes are used. Although they do not affect the stage grouping, they indicate cases needing separate analysis.

- m suffix** indicates the presence of multiple primary tumors in a single site and is recorded in parentheses: pT(m)NM.
- y prefix** indicates those cases in which classification is performed during or following initial multimodality therapy. The cTNM or pTNM category is identified by a "y" prefix. The ycTNM or ypTNM categorizes the extent of tumor actually present at the time of that examination. The "y" categorization is not an estimate of tumor prior to multimodality therapy.
- r prefix** indicates a recurrent tumor when staged after a disease-free interval, and is identified by the "r" prefix: rTNM.
- a prefix** designates the stage determined at autopsy: aTNM.

**Prognostic Indicators (if applicable)**

**Notes**

**Additional Descriptors**

**Lymphatic Vessel Invasion (L)**  
LX Lymphatic vessel invasion cannot be assessed

L0 No lymphatic vessel invasion

L1 Lymphatic vessel invasion

**Venous Invasion (V)**

VX Venous invasion cannot be assessed

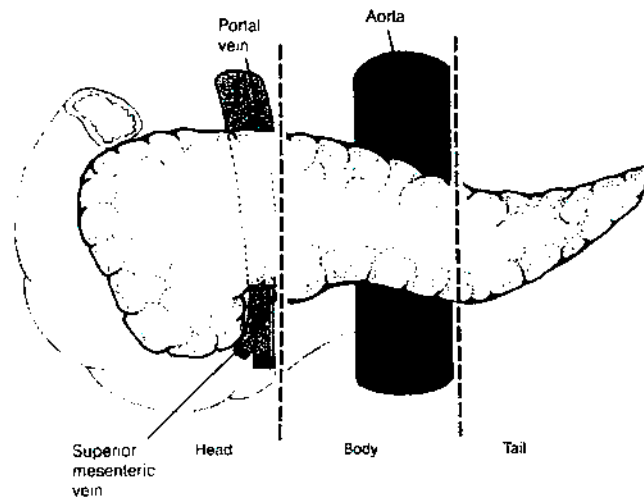
V0 No venous invasion

V1 Microscopic venous invasion

V2 Macroscopic venous invasion

**ILLUSTRATION**

Indicate on diagram primary tumor and regional nodes involved.



Physician's Signature \_\_\_\_\_ Date \_\_\_\_\_



# **PART IV**

## **Thorax**

## Lung

*(Sarcomas and other rare tumors are not included.)*

C34.0 Main bronchus  
C34.1 Upper lobe, lung

C34.2 Middle lobe, lung  
C34.3 Lower lobe, lung

C34.8 Overlapping lesion of lung  
C34.9 Lung, NOS

**SUMMARY OF CHANGES**

- The definition of TNM and the Stage Grouping for this chapter have not changed from the Fifth Edition.

**INTRODUCTION**

Lung cancer is among the most common malignancies in the Western world and is the leading cause of cancer deaths in both men and women. It is one of the few tumors with a known carcinogen, namely tobacco, contributing to its etiology. In recent years we have come to appreciate that the initiation of lung cancer is a complex process that also involves certain biologic factors, such as the body's ability to process carcinogens. This disease is usually not diagnosed early, and therefore the overall 5-year survival rate is approximately 15%. The treatment of lung cancer depends on the extent of disease, the location of the primary tumor, and the presence or absence of medical comorbidities. The assessment of extrapulmonary intrathoracic and extrathoracic metastasis is important for staging and patient evaluation.

**ANATOMY**

**Primary Site.** Carcinomas of the lung arise either from the alveolar lining cells of the pulmonary parenchyma or from the mucosa of the tracheobronchial tree. The trachea, which lies in the middle mediastinum, divides into the right and left main bronchi, which extend into the right and left lungs, respectively. The bronchi then subdivide into the lobar bronchi for the upper, middle, and lower lobes on the right and the upper and lower lobes on the left. The lungs are encased in membranes called the visceral pleura. The inside of the chest cavity is lined by a similar membrane called the parietal pleura. The potential space between these two membranes is the pleural space. The mediastinum contains the heart, thymus, great vessels, and other structures between the lungs.

The great vessels include:

Aorta  
Superior vena cava  
Inferior vena cava  
Main pulmonary artery  
Intrapericardial segments of the trunk of the right and left pulmonary artery  
Intrapericardial segments of the superior and inferior right and left pulmonary veins

**Regional Lymph Nodes.** All regional nodes are above the diaphragm. They include the intrathoracic, scalene, and supraclavicular nodes (Fig. 19.1). For purposes of staging, the intrathoracic nodes include the following:

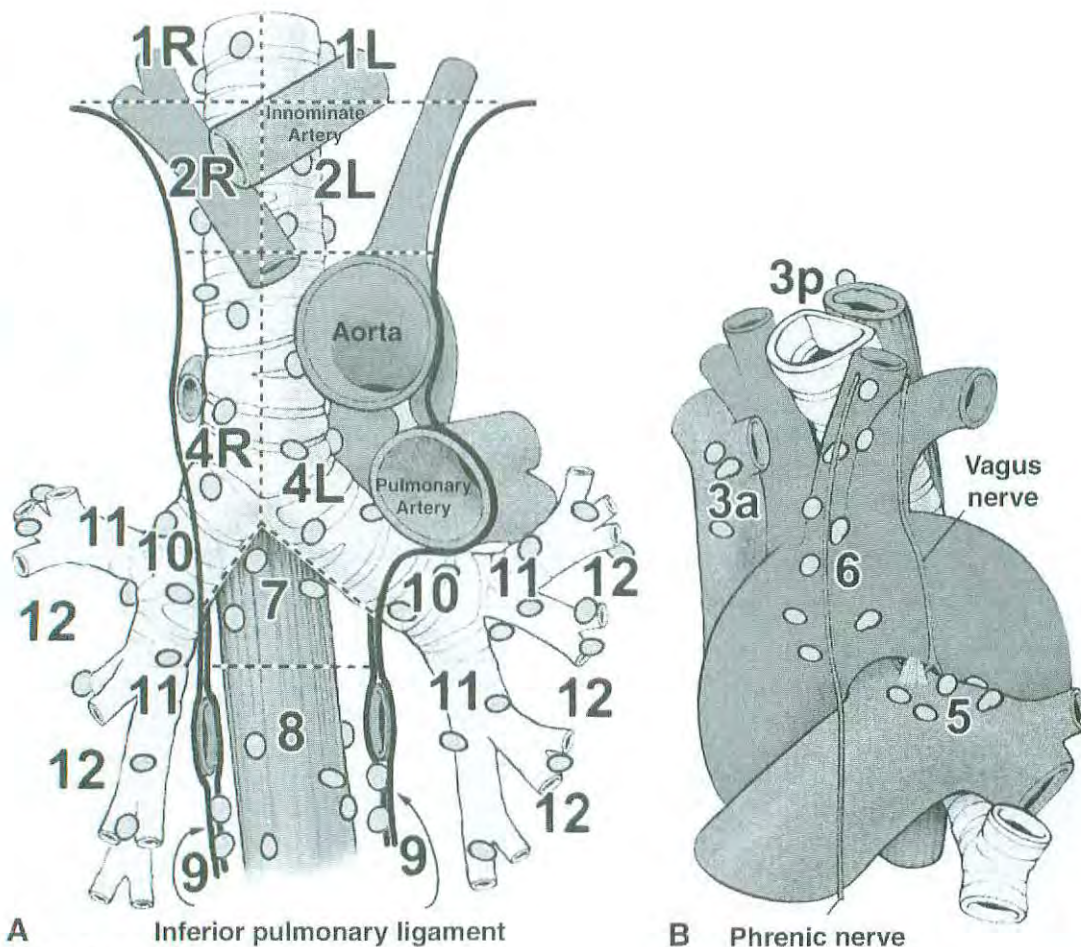
*Mediastinal*

Paratracheal (including those that may be designated tracheobronchial—that is, lower paratracheal, including azygous)  
Pre- and retrotracheal (includes precarinal)  
Aortic (includes aortopulmonary window, periaortic, ascending aortic, and phrenic)  
Subcarinal  
Periesophageal  
Inferior pulmonary ligament

*Intrapulmonary*

Hilar (proximal lobar)  
Peribronchial  
Intrapulmonary (includes interlobar, lobar, and segmental)

**Distant Metastatic Sites.** The most common metastatic sites are the brain, bones, adrenal glands, contralateral lung, liver, pericardium, and kidneys. However, virtually any organ can be a site of metastases.



**Fig. 19.1.** Lymph node maps of lung

N2 nodes: All N2 nodes lie within the mediastinal pleural envelope on the ipsilateral side.

- |   |   |
|---|---|
| 1. Highest mediastinal nodes                | 6. Para-aortic nodes (ascending aorta or phrenic) |
| 2. Upper paratracheal nodes                 | 7. Subcarinal nodes                               |
| 3. Prevascular and retrotracheal nodes      | 8. Paraesophageal nodes (below carina)            |
| 4. Lower paratracheal nodes                 | 9. Pulmonary ligament nodes                       |
| 5. Subaortic nodes (aorto-pulmonary window) |   |

N1 nodes: All N1 nodes lie distal to the mediastinal pleural reflection and *within the visceral pleura*.

- |                         |                        |
|-------------------------|------------------------|
| 10. Hilar nodes         | 13. Segmental nodes    |
| 11. Interlobar nodes    | 14. Subsegmental nodes |
| 12. Lobar nodes bronchi |                        |

Illustration from ACOSOG protocol Z0030, part 1, pp. 12–13. Used by permission of the Mayo Foundation for Medical Education and Research.

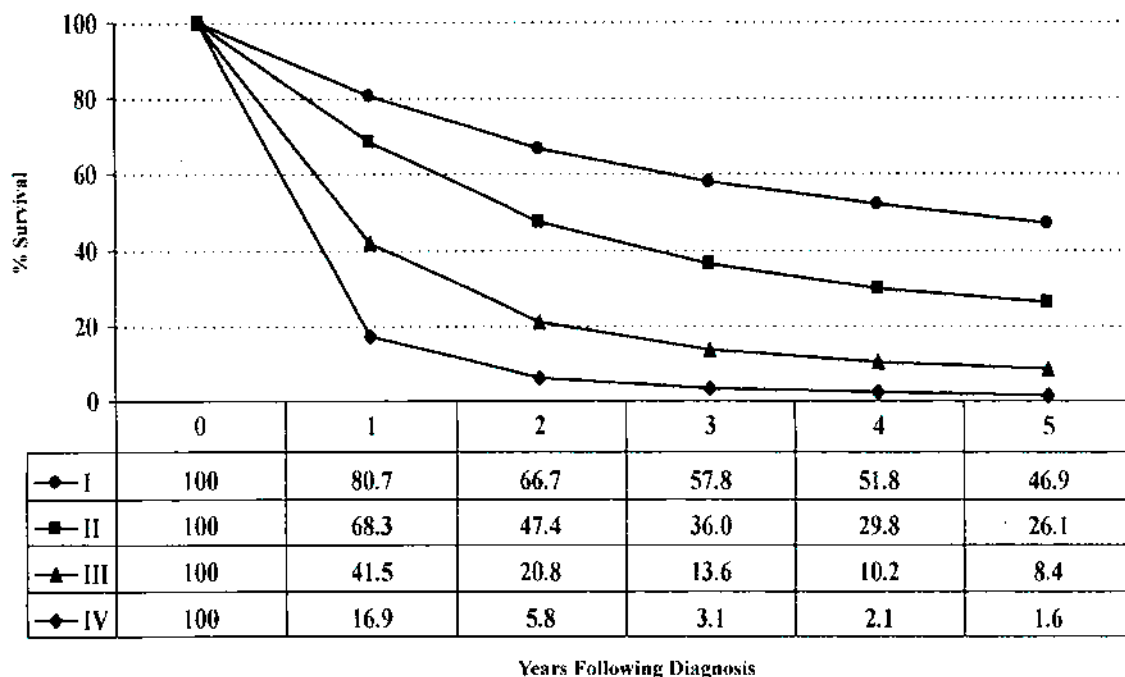
Lymph node classification adapted from Mountain CF, Dresler CM: Regional lymph node classification for lung cancer staging. *Chest* 111:1718–1723, 1977.

## RULES FOR CLASSIFICATION

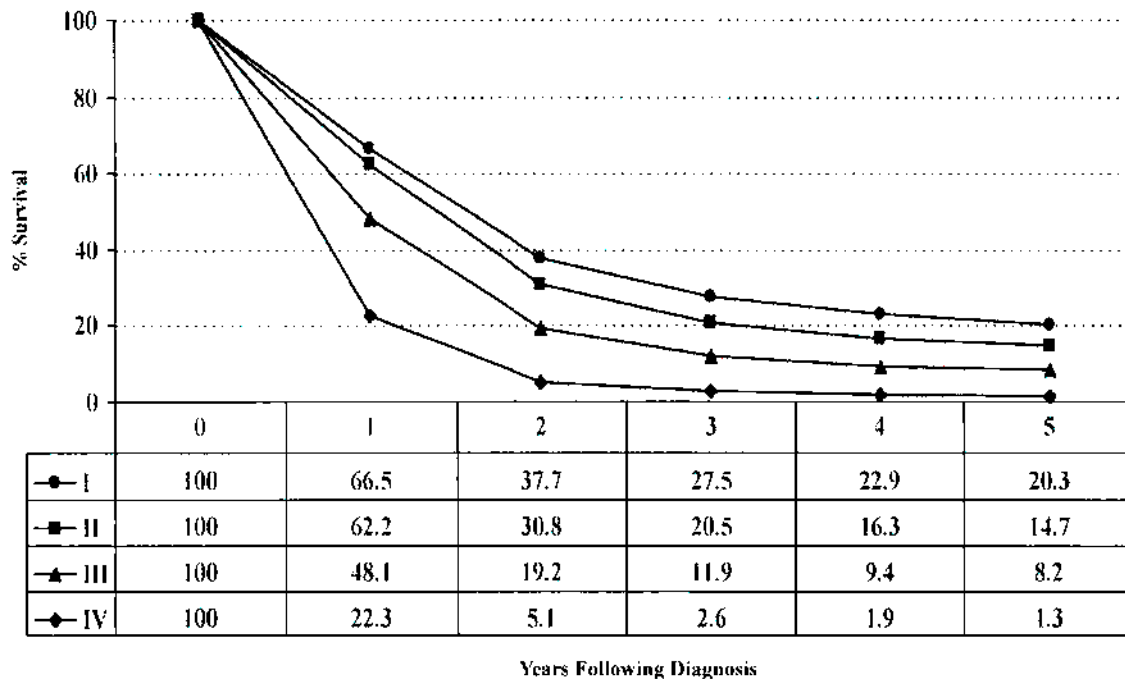
Lung cancers are broadly classified as either non-small cell (80% of tumors) or small cell carcinomas (20% of tumors). This general histologic distinction reflects the clinical and biologic behavior of these two tumor types. Approximately half of all non-small cell lung cancers are either localized or locally advanced at the time of diagnosis and are treated by resection alone or by combined modality therapy with or without resection. By contrast, small cell lung cancers are metastatic in 80% of cases at diagnosis. Even small cell lung

cancers that are initially localized to the hemithorax tend to metastasize early in their course and are managed principally with systemic therapy. Less than 10% of small cell lung cancers are detected at a very early stage when they can be treated by resection and adjuvant chemotherapy.

The TNM staging system described here is used primarily for non-small cell lung cancer. Although it is supposed to be applied also to small cell lung cancers, it is rarely used for the classification of those tumors in routine clinical practice and in most prospective clinical trials. A more common approach is to classify small cell lung cancers as either “limited”



A



B

**Fig. 19.2.** Relative survival rates for non-small cell lung cancer (A) and small cell lung cancer (B) diagnosed in the United States in 1992 and 1993. Cases classified by the current staging classification, where pathologic stage group was used to classify each case when available, and clinical stage group was used otherwise. For non-small cell lung cancer, Stage I includes 30,260 patients, Stage II, 8,893 patients, Stage III 38,498 patients, and Stage IV 44,410 patients. For small cell lung cancer, Stage I includes 2,389 patients, Stage II 1,031 patients, Stage III 8,569 patients, and Stage IV 16,568 patients. Data are from the National Cancer Data Base (Commission on Cancer of the American College of Surgeons and the American Cancer Society).



or “extensive” stage. Limited stage disease is the equivalent of Stages I through IIIB in the TNM staging system, and extensive stage small cell lung cancer is the equivalent of Stage IV disease. However, patients with pleural effusions (previously considered to have T4, Stage IIIB disease) are usually classified as having extensive stage disease. Performance status and biochemical parameters such as LDH are also used to categorize small cell lung cancers into prognostic groups.

Overall survival for small cell lung cancer by TNM staging based on information from the National Cancer Database is shown in Figure 19.2. For the purposes of classifying small cell lung cancers in tumor registries, the TNM system should be used.

**Clinical Staging.** Clinical staging is based on the non-invasive assessment of the extent of disease and typically includes a combination of medical history, physical examination, various imaging procedures (such as computed tomography and positron emission tomography), and laboratory tests. Information from staging procedures such as bronchoscopy, esophagoscopy, mediastinoscopy, mediastinotomy, thoracentesis, and thoracoscopy and information from exploratory thoracotomy are not included in the clinical classification, because these tests generally yield material for pathologic examination. Patients explored and found to have unresectable tumors at thoracotomy should be pathologically staged.

Lung cancer detected by sputum cytology but not seen radiographically or during bronchoscopy is known as “occult” carcinoma and is coded as TX. Occult cancers without evidence of regional lymph node involvement or distant metastasis are coded as TX, N0, M0. Any primary tumor that cannot be assessed—that is, no tumor mass present or evaluable, but lung cancer proven—is designated as TX. T2 is used when there is direct extension into the visceral pleura. T3 is used when the lesion directly invades the parietal pleura covering the mediastinum and pericardium, as well as that lining the chest wall and covering the diaphragm. Invasion of the phrenic nerve by the primary tumor is also classified as T3. Peripheral tumors directly invading the chest wall and ribs are T3 as well.

“Satellite nodules,” defined as additional small tumor nodules in the same lobe as the primary tumor, are classified as T4. These nodules are in the same lobe as the primary tumor but are anatomically distinct from it. The term *satellite nodule* refers to tumor nodules identified by imaging studies such as CT scan or by gross findings at thoracotomy, but not to such nodules detected solely on pathologic examination of a resection specimen.

Pleural tumor foci that are separate from direct pleural invasion by the primary tumor should be listed as T4. A separate lesion outside the parietal pleura, in the chest wall, or in the diaphragm should be designated as M1.

Patients with a malignant pleural effusion—that is, either cytologically positive for cancer cells or clinically related to the underlying malignancy—are coded T4. However, such patients are thought to have a poor prognosis and are usually

treated primarily with chemotherapy as though they had M1 disease. The T4 classification of patients who have pleural metastases requires further study and may be reconsidered in the future.

Pericardial effusion is currently classified as T4 unless clearly of benign etiology (such as viral pericarditis and congestive heart failure). A malignant pericardial effusion usually develops as a result of hematogenous or lymphatic tumor dissemination and is usually associated with a short life expectancy. Like the T4 classification for pleural metastases, the classification of pericardial metastases requires further study and may be reconsidered in the future.

Vocal cord paralysis (resulting from involvement of the recurrent branch of the vagus nerve), superior vena caval obstruction, or compression of the trachea or esophagus may be related to direct extension of the primary tumor or to lymph node involvement. The treatment options and prognosis associated with these manifestations of disease extent fall within the T4-Stage IIIB category; therefore, a classification of T4 is recommended. If the primary tumor is peripheral and clearly unrelated to vocal cord paralysis, vena caval obstruction, or compression of the trachea and esophagus, vocal cord paralysis is usually related to the presence of N2 disease in the aortopulmonary window and should be classified as such.

The designation of “Pancoast” tumors refers to the symptom complex or syndrome caused by a tumor arising in the superior sulcus of the lung that involves the inferior branches of the brachial plexus (C8 and/or T1) and the sympathetic nerve trunks, including the stellate ganglion. Some superior sulcus tumors are more anteriorly located and may cause fewer neurologic symptoms even when they are very locally advanced and encase the subclavian vessels. The extent of disease varies in these tumors, and they should be classified according to the established rules. If there is evidence of invasion of the vertebral body or spinal canal, encasement of the subclavian vessels, or unequivocal involvement of the superior branches of the brachial plexus (C8 or above), then the tumor is classified as T4. If no criteria for T4 disease pertain, the tumor is classified as T3.

Tumors directly invading the diaphragm in the absence of other signs of locally advanced disease are rare, constituting less than 1% of all cases of potentially resectable non-small cell lung cancers. These tumors are considered to be T3, but they appear to have a poor prognosis, even after complete resection and in the absence of N2 disease. The classification of such tumors may need to be re-evaluated in the future as more survival data become available.

**Pathologic Staging.** Pathologic staging is based on the information obtained from clinical staging, a variety of staging procedures including thoracotomy, and from examination of the resected specimen, including lymph nodes. The same classification applies to both clinical and pathologic staging. The histologic type of cancer should be recorded, because it also has a bearing on prognosis.

Multiple synchronous tumors should be considered separate primary lung cancers, and each should be staged separately.

rately. For single-patient data entry, the highest stage of disease should be recorded, with separate coding to identify multiple primary tumors. Synchronous tumors may be identified according to the criteria originally proposed by Martini and Melamed. These include multiple synchronous tumors of different histologic cell types; or two tumors of the same histologic type in separate lobes with no evidence of extrathoracic disease, of mediastinal nodal metastases, or of nodal metastases within a common nodal drainage (for example, involved interlobar nodes with right upper- and lower-lobe tumors of the same histology).

Bronchioloalveolar carcinomas may pose unique problems for staging because of their tendency to form multiple primary tumors, either synchronous or metachronous. Further investigation is required to determine the appropriate classification of multiple synchronous bronchioloalveolar carcinomas. However, at the present time, these tumors should be classified according to the rules of synchronous tumors or metastatic disease that are used for other histologic types.

## DEFINITION OF TNM

### Primary Tumor (T)

- TX Primary tumor cannot be assessed, or tumor proven by the presence of malignant cells in sputum or bronchial washings but not visualized by imaging or bronchoscopy
- T0 No evidence of primary tumor
- Tis Carcinoma *in situ*
- T1 Tumor 3 cm or less in greatest dimension, surrounded by lung or visceral pleura, without bronchoscopic evidence of invasion more proximal than the lobar bronchus,\* (i.e., not in the main bronchus)
- T2 Tumor with any of the following features of size or extent:
  - More than 3 cm in greatest dimension
  - Involves main bronchus, 2 cm or more distal to the carina
  - Invades the visceral pleura
  - Associated with atelectasis or obstructive pneumonitis that extends to the hilar region but does not involve the entire lung
- T3 Tumor of any size that directly invades any of the following: chest wall (including superior sulcus tumors), diaphragm, mediastinal pleura, parietal pericardium; or tumor in the main bronchus less than 2 cm distal to the carina, but without involvement of the carina; or associated atelectasis or obstructive pneumonitis of the entire lung
- T4 Tumor of any size that invades any of the following: mediastinum, heart, great vessels, trachea, esophagus, vertebral body, carina; or separate tumor nodules in the same lobe; or tumor with malignant pleural effusion\*\*

\*Note: The uncommon superficial tumor of any size with its invasive component limited to the bronchial wall, which may extend proximal to the main bronchus, is also classified T1.

\*\*Note: Most pleural effusions associated with lung cancer are due to tumor. However, there are a few patients in whom multiple cytopathologic examinations of pleural fluid are negative for tumor. In these cases, fluid is non-bloody and is not an exudate. Such patients may be further evaluated by videothoracoscopy (VATS) and direct pleural biopsies. When these elements and clinical judgment dictate that the effusion is not related to the tumor, the effusion should be excluded as a staging element and the patient should be staged T1, T2, or T3.

### Regional Lymph Nodes (N)

- NX Regional lymph nodes cannot be assessed
- N0 No regional lymph node metastasis
- N1 Metastasis to ipsilateral peribronchial and/or ipsilateral hilar lymph nodes, and intrapulmonary nodes including involvement by direct extension of the primary tumor
- N2 Metastasis to ipsilateral mediastinal and/or subcarinal lymph nodes(s)
- N3 Metastasis to contralateral mediastinal, contralateral hilar, ipsilateral or contralateral scalene, or supraclavicular lymph nodes(s)

### Distant Metastasis (M)

- MX Distant metastasis cannot be assessed
- M0 No distant metastasis
- M1 Distant metastasis present

Note: M1 includes separate tumor nodule(s) in a different lobe (ipsilateral or contralateral).

STAGE GROUPING			
Occult Carcinoma	TX	N0	M0
Stage 0	Tis	N0	M0
Stage IA	T1	N0	M0
Stage IB	T2	N0	M0
Stage IIA	T1	N1	M0
Stage IIB	T2	N1	M0
	T3	N0	M0
Stage IIIA	T1	N2	M0
	T2	N2	M0
	T3	N1	M0
	T3	N2	M0
Stage IIIB	Any T	N3	M0
	T4	Any N	M0
Stage IV	Any T	Any N	M1

## HISTOPATHOLOGIC TYPE

### Squamous cell carcinoma

Variants: Papillary, clear cell, small cell, basaloid

### Small cell carcinoma

Variant: Combined small cell carcinoma

### Adenocarcinoma

Acinar

Papillary

Bronchioloalveolar carcinoma

Non-mucinous

Mucinous

Mixed mucinous and non-mucinous or indeterminate

Solid adenocarcinoma with mucin formation

### Adenocarcinoma with mixed subtypes

Variants: Well differentiated fetal adenocarcinoma, mucinous (“colloid”) adenocarcinoma, mucinous cystadenocarcinoma, signet ring adenocarcinoma, clear cell adenocarcinoma

### Large cell carcinoma

Variants: Large cell neuroendocrine carcinoma, combined large cell neuroendocrine carcinoma, basaloid carcinoma, lymphoepithelioma-like carcinoma, clear cell carcinoma, large cell carcinoma with rhabdoid phenotype

*Note:* This summarizes the classification of the four major histologic types of lung cancer from the 1999 WHO/IASLC Histologic Typing of Lung and Pleural Tumors. An important change from the previous classifications is that bronchioloalveolar carcinoma is now limited to non-invasive tumors with lepidic spread. If stromal, vascular, or pleural invasion is seen, the tumor is reclassified as adenocarcinoma, mixed subtype, with specification of the subtypes that are present.

## HISTOLOGIC GRADE (G)

GX Grade cannot be assessed

G1 Well differentiated

G2 Moderately differentiated

G3 Poorly differentiated

G4 Undifferentiated

## PROGNOSTIC FACTORS

The prognostic significance of histologic cell type and anatomic extent of disease in lung cancer is generally accepted. Small cell carcinoma, characterized by rapid growth and widespread dissemination, even in clinically “early” disease is recognized as a separate entity from the non-small cell histologies—adenocarcinoma, large cell carcinoma and squamous cell carcinoma. Treatment selection and survival are significantly related to the stage and histologic classification.

It must be kept in mind that the diagnostic process will affect the accuracy of clinical staging. Series of patients in whom mediastinoscopy is required for surgical selection or those in whom a complete lymph node dissection is performed at operation will have fewer errors reported than may be reported for patients in whom these procedures are not performed.

**Clinical Factors.** Performance status and severity of symptoms have prognostic significance in non-small cell carcinoma; these factors may be related either to the spread of the cancer or to associated conditions that limit treatment—for example, the cardiac and pulmonary complications associated with advancing age, as well as with tobacco use. Weight loss (more than 10% of body weight) has an adverse effect on prognosis and is predictive of recurrence in patients who have undergone resection. Differing studies have identified gender, age, and various physiologic components as indicators of a poor outcome; however, most are not reproduced in large-scale studies of well-defined lung cancer populations.

A large number of clinical, laboratory, serologic, paraneoplastic, and immune factors have been investigated for their prognostic influence on specific groups of patients with small cell carcinoma. Lactate dehydrogenase (LDH), alkaline phosphatase, albumin, hemoglobin and white blood count, and specific sites of metastasis have been identified as significant prognostic factors.

**Anatomic Factors.** Each of the staging components—the primary tumor, the regional lymph nodes, and distant metastasis—has a profound effect on prognosis. The most deleterious factor is the presence of distant metastatic disease. Involvement of multiple distant sites has more serious implications than single-site metastasis, which may be responsive to available treatment in a few instances (for example, surgical treatment of solitary brain lesions and response to chemotherapy or combined regimens).

The presence or absence of regional lymph node metastasis has significant bearing on prognosis. When lymph node metastasis has progressed beyond the ipsilateral hemithorax, the outcome is very poor. Less than 3% of patients with clinical evidence of N3 disease are expected to survive 5 years or more. Survival rates for patients with metastasis limited to the ipsilateral mediastinal lymph nodes (N2) are influenced by the number and nodal levels involved (upper mediastinal, lower mediastinal, or both, and extracapsular extension).

The prognostic implications of intrapulmonary lymph node metastasis vary with the location of the nodes and the primary tumor status. Metastasis to the hilar nodes carries worse prognosis than disease limited to the lobar and segmental nodes. Involvement of N1 nodes in the presence of larger, more invasive tumors, T2 or T3, indicates a poorer outcome than expected for T1 tumors.

**Biologic Factors.** Research advances in the field of molecular biology have provided a new understanding of the

genetic background of lung cancer. Knowledge of the role of genetic abnormalities and other biologic aberrations in tumorigenesis is the basis for many investigations of biologic markers as indicators of prognosis. In order to take marker information to clinical practice, the marker must bear a strong relationship to patient prognosis and the factor must provide additional prognostic information beyond that provided by conventional factors. No such markers are used as yet for routine staging or determination of prognosis of lung cancer, and further investigation of this area is needed.

## BIBLIOGRAPHY

- D'Amico TA, Aloia TA, Moore M-BH, et al: Molecular biologic substaging of Stage I lung cancer according to gender and histology. *Ann Thorac Surg* 69:882-886, 2000
- Deschamps C, Pairolero PC, Trastek VF, Payne WS: Multiple primary lung cancers: results of surgical treatment. *J Thorac Cardiovasc Surg* 99:769-778, 1990
- Deslauriers J, Brisson J, Cartier R, et al: Carcinoma of the lung: evaluation of satellite nodules as a factor influencing prognosis after resection. *J Thorac Cardiovasc Surg* 97:504-512, 1989
- Ichinose Y, Yano T, Yokoyama H, Inoue T, Asoh H, Katsuda Y: The correlation between tumor size and lymphatic vessel invasion in resected peripheral stage I non-small-cell lung cancer. A potential risk of limited resection. *J Thorac Cardiovasc Surg* 108:684-686, 1994
- Martini N, Flehinger BJ, Zaman MB, Beattie EJ, Jr.: Results of resection in non-oat cell carcinoma of the lung with mediastinal lymph node metastases. *Ann Surg* 198:386-397, 1983
- Martini N, Melamed MR: Multiple primary lung cancers. *J Thorac Cardiovasc Surg* 70:606-612, 1975
- Martini N, Yellin A, Ginsberg RJ, et al: Management of non-small cell lung cancer with direct mediastinal involvement. *Ann Thorac Surg* 58:1447-1451, 1994
- Patterson GA, Piazza D, Pearson FG, et al: Significance of metastatic disease in subaortic lymph nodes. *Ann Thorac Surg* 43:155-159, 1987
- Pitz CCM, de la Rivière AB, Elbers HRJ, Westermann CJJ, van den Bosch JM: Results of resection of T3 non-small cell lung cancer invading the mediastinum or main bronchus. *Ann Thorac Surg* 62:1016-1020, 1996
- Quraishi MA, Costanzi JJ, Hokanson J: The natural history of lung cancer with pericardial metastases. *Cancer* 51:740-742, 1983
- Sagawa M, Saito Y, Takahashi S, et al: Clinical and prognostic assessment of patients with resected small peripheral lung cancer lesions. *Cancer* 66:2653-2657, 1990
- Sagawa M, Sakurada A, Fujimura S, et al: Five-year survivors with resected pN2 non-small cell lung carcinoma. *Cancer* 85:864-868, 1999
- Saito Y, Nagamoto N, Ota S-I, et al: Results of surgical treatment for roentgenographically occult bronchogenic squamous cell carcinoma. *J Thorac Cardiovasc Surg* 104:401-407, 1992
- Travis WD, Colby TV, Corrin B, et al: Histologic typing of lung and pleural tumors. In World Health Organization Pathology Panel (Ed.): World Health Organization International Histological Classification of Tumors, 3rd ed. Berlin: Springer-Verlag, 5, 1999

- van Velzen E, Snijder RJ, de la Rivière AB, Elbert HJJ, van den Bosch JM: Type of lymph node involvement influences survival rates of T1N1M0 non-small cell lung carcinoma: lymph node involvement by direct extension compared with lobar and hilar node metastases. *Chest* 110:1469-1473, 1996
- Weksler B, Bains M, Burt M, et al: Resection of lung cancer invading the diaphragm. *J Thorac Cardiovasc Surg* 114:500-501, 1997
- Werner-Wasik M, Scott C, Cox JD, et al: Recursive partitioning analysis of 1999 Radiation Therapy Oncology Group (RTOG) patients with locally-advanced non-small cell lung cancer (LA-NSCLC): identification of five groups with different survival. *Int J Radiat Oncol Biol Phys* 48:1475-1482, 2000

## HISTOLOGIES—LUNG

- 8000/3 Neoplasm, malignant
- 8001/3 Tumor cells, malignant
- 8002/3 Malignant tumor, small cell type
- 8003/3 Malignant tumor, giant cell type
- 8004/3 Malignant tumor, spindle cell type
- 8005/3 Malignant tumor, clear cell type
- 8010/2 Carcinoma *in situ*, NOS
- 8010/3 Carcinoma, NOS
- 8011/3 Epithelioma, malignant
- 8012/3 Large cell carcinoma, NOS
- 8013/3 Large cell neuroendocrine carcinoma
- 8014/3 Large cell carcinoma with rhabdoid phenotype
- 8015/3 Glassy cell carcinoma
- 8020/3 Carcinoma, undifferentiated, NOS
- 8021/3 Carcinoma, anaplastic, NOS
- 8022/3 Pleomorphic carcinoma
- 8030/3 Giant cell and spindle cell carcinoma
- 8031/3 Giant cell carcinoma
- 8032/3 Spindle cell carcinoma, NOS
- 8033/3 Pseudosarcomatous carcinoma
- 8034/3 Polygonal cell carcinoma
- 8035/3 Carcinoma with osteoclast-like giant cells
- 8041/3 Small cell carcinoma, NOS
- 8042/3 Oat cell carcinoma
- 8043/3 Small cell carcinoma, fusiform cell
- 8044/3 Small cell carcinoma, intermediate cell
- 8045/3 Combined small cell carcinoma
- 8046/3 Non-small cell carcinoma
- 8050/3 Papillary carcinoma, NOS
- 8051/3 Verrucous carcinoma, NOS
- 8052/2 Papillary squamous cell carcinoma, non-invasive
- 8052/3 Papillary squamous cell carcinoma
- 8070/2 Squamous cell carcinoma *in situ*, NOS
- 8070/3 Squamous cell carcinoma, NOS
- 8071/3 Squamous cell carcinoma, keratinizing, NOS
- 8072/3 Squamous cell carcinoma, large cell, non-keratinizing, NOS
- 8073/3 Squamous cell carcinoma, small cell, non-keratinizing
- 8074/3 Squamous cell carcinoma, spindle cell
- 8075/3 Squamous cell carcinoma, adenoid
- 8076/2 Squamous cell carcinoma *in situ* with questionable stromal invasion
- 8076/3 Squamous cell carcinoma, microinvasive
- 8077/2 Squamous intraepithelial neoplasia, grade III

**HISTOLOGIES—LUNG (CONT.)**

8082/3	Lymphoepithelial carcinoma	8320/3	Granular cell carcinoma
8083/3	Basaloid squamous cell carcinoma	8323/3	Mixed cell adenocarcinoma
8084/3	Squamous cell carcinoma, clear cell type	8333/3	Fetal adenocarcinoma
8090/3	Basal cell carcinoma, NOS	8341/3	Papillary microcarcinoma
8093/3	Basal cell carcinoma, fibroepithelial	8342/3	Papillary carcinoma, oxyphilic cell
8094/3	Basosquamous carcinoma	8343/3	Papillary carcinoma, encapsulated
8097/3	Basal cell carcinoma, nodular	8430/3	Mucoepidermoid carcinoma
8120/3	Transitional cell carcinoma, NOS	8440/3	Cystadenocarcinoma, NOS
8122/3	Transitional cell carcinoma, spindle cell	8441/3	Serous cystadenocarcinoma, NOS
8123/3	Basaloid carcinoma	8450/3	Papillary cystadenocarcinoma, NOS
8140/2	Adenocarcinoma <i>in situ</i> , NOS	8452/3	Solid pseudopapillary carcinoma
8140/3	Adenocarcinoma, NOS	8470/3	Mucinous cystadenocarcinoma, NOS
8141/3	Scirrhous adenocarcinoma	8471/3	Papillary mucinous cystadenocarcinoma
8147/3	Basal cell adenocarcinoma	8480/3	Mucinous adenocarcinoma
8148/2	Glandular intraepithelial neoplasia, grade III	8481/3	Mucin-producing adenocarcinoma
8200/3	Adenoid cystic carcinoma	8490/3	Signet ring cell carcinoma
8211/3	Tubular adenocarcinoma	8525/3	Polymorphous low grade adenocarcinoma
8230/3	Solid adenocarcinoma with mucin formation	8530/3	Inflammatory carcinoma
8250/3	Bronchiolo-alveolar adenocarcinoma, NOS	8550/3	Acinar cell carcinoma
8251/3	Alveolar adenocarcinoma	8551/3	Acinar cell cystadenocarcinoma
8252/3	Bronchiolo-alveolar carcinoma, non-mucinous	8560/3	Adenosquamous carcinoma
8253/3	Bronchiolo-alveolar carcinoma, mucinous	8562/3	Epithelial-myoepithelial carcinoma
8254/3	Bronchiolo-alveolar carcinoma, mixed mucinous and non-mucinous	8570/3	Adenocarcinoma with squamous metaplasia
8255/3	Adenocarcinoma with mixed subtypes	8571/3	Adenocarcinoma with cartilaginous and osseous metaplasia
8260/3	Papillary adenocarcinoma, NOS	8572/3	Adenocarcinoma with spindle cell metaplasia
8310/3	Clear cell adenocarcinoma, NOS	8573/3	Adenocarcinoma with apocrine metaplasia
8314/3	Lipid-rich carcinoma	8720/3	Malignant melanoma, NOS ( <i>primary only</i> )
8315/3	Glycogen-rich carcinoma	8815/3	Solitary fibrous tumor, malignant
		8940/3	Mixed tumor, malignant, NOS
		8941/3	Carcinoma in pleomorphic adenoma

# LUNG

<b>Hospital Name/Address</b>     
--

<b>Patient Name/Information</b>     
---

Type of Specimen \_\_\_\_\_  
Tumor Size \_\_\_\_\_

Histopathologic Type \_\_\_\_\_  
Laterality:     Bilateral     Left     Right

## DEFINITIONS

Clinical	Pathologic		Primary Tumor (T)
<input type="checkbox"/>	<input type="checkbox"/>	TX	Primary tumor cannot be assessed, or tumor proven by the presence of malignant cells in sputum or bronchial washings but not visualized by imaging or bronchoscopy
<input type="checkbox"/>	<input type="checkbox"/>	T0	No evidence of primary tumor
<input type="checkbox"/>	<input type="checkbox"/>	Tis	Carcinoma <i>in situ</i>
<input type="checkbox"/>	<input type="checkbox"/>	T1	Tumor 3 cm or less in greatest dimension, surrounded by lung or visceral pleura, without bronchoscopic evidence of invasion more proximal than the lobar bronchus <sup>(1)</sup> (i.e., not in the main bronchus)
<input type="checkbox"/>	<input type="checkbox"/>	T2	Tumor with any of the following features of size or extent: <ul style="list-style-type: none"> <li>• More than 3 cm in greatest dimension</li> <li>• Involves main bronchus, 2 cm or more distal to the carina</li> <li>• Invades the visceral pleura</li> <li>• Associated with atelectasis or obstructive pneumonitis that extends to the hilar region but does not involve the entire lung</li> </ul>
<input type="checkbox"/>	<input type="checkbox"/>	T3	Tumor of any size that directly invades any of the following: chest wall (including superior sulcus tumors), diaphragm, mediastinal pleura, parietal pericardium; or tumor in the main bronchus less than 2 cm distal to the carina, but without involvement of the carina; or associated atelectasis or obstructive pneumonitis of the entire lung
<input type="checkbox"/>	<input type="checkbox"/>	T4	Tumor of any size that invades any of the following: mediastinum, heart, great vessels, trachea, esophagus, vertebral body, carina; or separate tumor nodules in the same lobe; or tumor with malignant pleural effusion <sup>(2)</sup>

Clinical	Pathologic		Regional Lymph Nodes (N)
<input type="checkbox"/>	<input type="checkbox"/>	NX	Regional lymph nodes cannot be assessed
<input type="checkbox"/>	<input type="checkbox"/>	N0	No regional lymph node metastasis
<input type="checkbox"/>	<input type="checkbox"/>	N1	Metastasis to ipsilateral peribronchial and/or ipsilateral hilar lymph nodes, and intrapulmonary nodes including involvement by direct extension of the primary tumor
<input type="checkbox"/>	<input type="checkbox"/>	N2	Metastasis to ipsilateral mediastinal and/or subcarinal lymph nodes(s)
<input type="checkbox"/>	<input type="checkbox"/>	N3	Metastasis to contralateral mediastinal, contralateral hilar, ipsilateral or contralateral scalene, or supraclavicular lymph nodes(s)

Clinical	Pathologic		Distant Metastasis (M)
<input type="checkbox"/>	<input type="checkbox"/>	MX	Distant metastasis cannot be assessed
<input type="checkbox"/>	<input type="checkbox"/>	M0	No distant metastasis
<input type="checkbox"/>	<input type="checkbox"/>	M1	Distant metastasis present <sup>(3)</sup> Biopsy of metastatic site performed ..... <input type="checkbox"/> Y ..... <input type="checkbox"/> N Source of pathologic metastatic specimen _____

### Notes

1. The uncommon superficial tumor of any size with its invasive component limited to the bronchial wall, which may extend proximal to the main bronchus, is also classified T1.
2. Most pleural effusions associated with lung cancer are due to tumor. However, there are a few patients in whom multiple cytopathologic examinations of pleural fluid are negative for tumor. In these cases, fluid is non-bloody and is not an exudate. Such patients may be further evaluated by videothoracoscopy (VATS) and direct pleural biopsies. When these elements and clinical judgment dictate that the effusion is not related to the tumor, the effusion should be excluded as a staging element and the patient should be staged T1, T2, or T3.
3. M1 includes separate tumor nodule(s) in a different lobe (ipsilateral or contralateral).

(continued on reverse side)

Clinical	Pathologic	Stage Grouping				Notes
<input type="checkbox"/>	<input type="checkbox"/>	Occult Carcinoma	TX	N0	M0	<b>Additional Descriptors</b> <b>Lymphatic Vessel Invasion (L)</b> LX Lymphatic vessel invasion cannot be assessed L0 No lymphatic vessel invasion L1 Lymphatic vessel invasion <b>Venous Invasion (V)</b> VX Venous invasion cannot be assessed V0 No venous invasion V1 Microscopic venous invasion V2 Macroscopic venous invasion
<input type="checkbox"/>	<input type="checkbox"/>	0	Tis	N0	M0	
<input type="checkbox"/>	<input type="checkbox"/>	IA	T1	N0	M0	
<input type="checkbox"/>	<input type="checkbox"/>	IB	T2	N0	M0	
<input type="checkbox"/>	<input type="checkbox"/>	IIA	T1	N1	M0	
<input type="checkbox"/>	<input type="checkbox"/>	IIB	T2	N1	M0	
<input type="checkbox"/>	<input type="checkbox"/>	IIIA	T3	N0	M0	
<input type="checkbox"/>	<input type="checkbox"/>		T2	N2	M0	
<input type="checkbox"/>	<input type="checkbox"/>		T3	N1	M0	
<input type="checkbox"/>	<input type="checkbox"/>	IIIB	Any T	N3	M0	
<input type="checkbox"/>	<input type="checkbox"/>		T4	Any N	M0	
<input type="checkbox"/>	<input type="checkbox"/>	IV	Any T	Any N	M1	

**Histologic Grade (G)**

- GX Grade cannot be assessed
- G1 Well differentiated
- G2 Moderately differentiated
- G3 Poorly differentiated
- G4 Undifferentiated

**Residual Tumor (R)**

- RX Presence of residual tumor cannot be assessed
- R0 No residual tumor
- R1 Microscopic residual tumor
- R2 Macroscopic residual tumor

**Additional Descriptors**

For identification of special cases of TNM or pTNM classifications, the "m" suffix and "y," "r," and "a" prefixes are used. Although they do not affect the stage grouping, they indicate cases needing separate analysis.

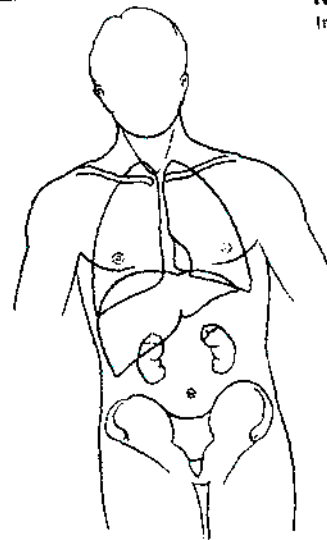
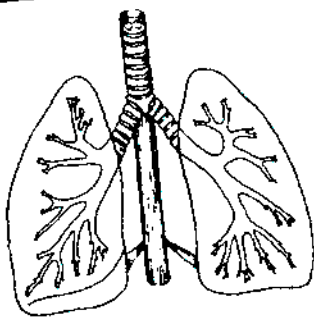
- m suffix** indicates the presence of multiple primary tumors in a single site and is recorded in parentheses: pT(m)NM.
- y prefix** indicates those cases in which classification is performed during or following initial multimodality therapy. The cTNM or pTNM category is identified by a "y" prefix. The ycTNM or ypTNM categorizes the extent of tumor actually present at the time of that examination. The "y" categorization is not an estimate of tumor prior to multimodality therapy.
- r prefix** indicates a recurrent tumor when staged after a disease-free interval, and is identified by the "r" prefix: rTNM.
- a prefix** designates the stage determined at autopsy: aTNM.

**Prognostic Indicators (if applicable)**

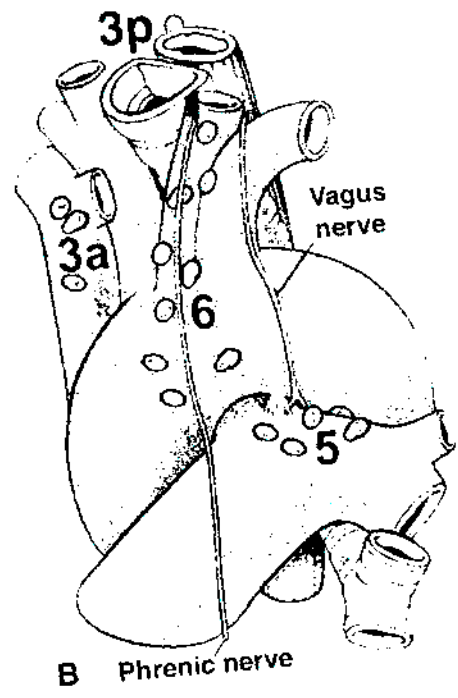
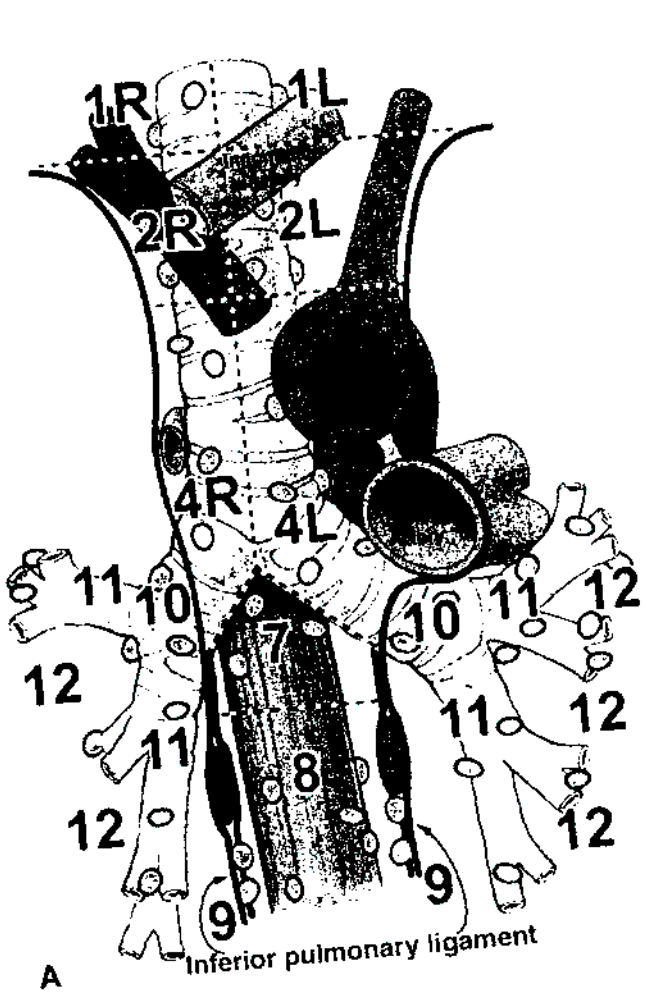
# LUNG

**ILLUSTRATION (Top right)**  
Indicate metastatic sites.

**ILLUSTRATION (Top left)**  
Indicate on diagram primary tumor and regional nodes involved.



4



For a description of the lymph node maps of the lung, see Chapter 19 of the *AJCC Cancer Staging Manual*

Physician's Signature \_\_\_\_\_ Date \_\_\_\_\_



## Pleural Mesothelioma

*(Tumors metastatic to the pleura and lung tumors that have extended to the pleural surfaces are not included.)*

C38.4 Pleura, NOS

### SUMMARY OF CHANGES

- The AJCC has adopted the staging system proposed by the International Mesothelioma Interest Group (IMIG) in 1995. It is based on updated information about the relationships between tumor T and N status and overall survival. This staging system applies only to tumors arising in the pleura.
- T categories have been redefined.
- T1 lesions have been divided into T1a and T1b, leading to the division of Stage I into Stage IA and Stage IB.
- T3 is defined as locally advanced but potentially resectable tumor.
- T4 is defined as locally advanced, technically unresectable tumor.
- Stage II no longer involves tumors with nodal metastasis; all nodal metastasis is categorized in Stage III or Stage IV.

### INTRODUCTION

Malignant mesotheliomas are relatively rare tumors that arise from the mesothelium lining the pleural, pericardial, and peritoneal cavities. They represent less than 2% of all malignant tumors. The most common risk factor for malignant mesotheliomas is previous exposure to asbestos. The latency period between asbestos exposure and the development of malignant mesothelioma is generally 20 years or more. Although peritoneal mesotheliomas are thought to occur in individuals who have had heavier exposure than those with pleural mesothelioma, there is no clearly documented relationship between the amount of asbestos exposure and the subsequent development of this neoplasm. Malignant mesotheliomas were previously thought to be virulent tumors. However, this impression was probably related to the fact that most mesotheliomas are diagnosed when they are already at an advanced stage. Recent data indicate that the clinical and biological behavior of mesotheliomas is variable and that most mesotheliomas grow relatively slowly.

All mesotheliomas are fundamentally epithelial tumors. However, their morphology ranges from a pure epithelial appearance to an entirely sarcomatoid or even desmoplastic

appearance. Distinguishing the pleiomorphic histology of mesotheliomas from that of other neoplasms can be difficult, especially for the pure epithelial mesotheliomas, which may closely resemble metastatic adenocarcinoma. Therefore, confirmation of the histologic diagnosis by immunohistochemistry and/or electron microscopy is essential.

During the past 30 years, many staging systems have been proposed for malignant pleural mesothelioma. The first staging system for this disease published by the American Joint Committee on Cancer (AJCC), and simultaneously accepted by the International Union Against Cancer, appeared in the fifth edition of the *AJCC Cancer Staging Manual*. The staging system described here represents adoption of the one proposed in 1995 by the International Mesothelioma Interest Group (IMIG), which is based on updated information about the relationships between tumor T and N status and overall survival. Although this system has been validated by several surgical reports, it will probably require revision in the future as further data in larger numbers of patients become available. This staging system applies only to tumors arising in the pleura. Peritoneal and pericardial mesotheliomas are rare and do not lend themselves easily to a TNM staging system.

## ANATOMY

**Primary Site.** The mesothelium covers the external surface of the lungs and the inside of the chest wall. It is usually composed of flat, tightly connected cells no more than one layer thick.

**Regional Lymph Nodes.** The regional lymph nodes include:

- Internal mammary
- Intrathoracic
- Scalene
- Supraclavicular

The regional lymph node map and nomenclature adopted for the mesothelioma staging system is identical to that used for lung cancer. See Chapter 19 for a detailed list of intrathoracic lymph nodes. For pN, histologic examination of a *mediastinal* lymphadenectomy or lymph node sampling specimen will ordinarily include regional nodes taken from the ipsilateral N1 and N2 nodal stations. Contralateral and supraclavicular nodes may be available if a mediastinoscopy or node biopsy is also performed.

**Distant Metastatic Sites.** Advanced malignant pleural mesotheliomas often metastasize widely to uncommon sites, including retroperitoneal lymph nodes, the brain and spine, or even organs such as the thyroid or prostate. However, the most frequent sites of metastatic disease are the peritoneum, contralateral pleura, and lung.

## RULES FOR CLASSIFICATION

This staging system serves both clinical and pathologic staging. Clinical staging depends on imaging, especially computed tomography scanning. Pathologic staging is based on surgical resection. The extent of disease before and after resection should be carefully documented. In some cases, complete N staging may not be possible, especially if technically unresectable tumor (T4) found at thoracotomy prevents access to both N1 and N2 lymph nodes.

## DEFINITION OF TNM

### IMIG Staging System for Diffuse Malignant Pleural Mesothelioma

#### Primary Tumor (T)

- TX Primary tumor cannot be assessed
- T0 No evidence of primary tumor
- T1 Tumor involves ipsilateral parietal pleura, with or without focal involvement of visceral pleura
- T1a Tumor involves ipsilateral parietal (mediastinal, diaphragmatic) pleura. No involvement of the visceral pleura

- T1b Tumor involves ipsilateral parietal (mediastinal, diaphragmatic) pleura, with focal involvement of the visceral pleura
- T2 Tumor involves any of the ipsilateral pleural surfaces with at least one of the following:
  - confluent visceral pleural tumor (including fissure)
  - invasion of diaphragmatic muscle
  - invasion of lung parenchyma
- T3\* Tumor involves any of the ipsilateral pleural surfaces, with at least one of the following:
  - invasion of the endothoracic fascia
  - invasion into mediastinal fat
  - solitary focus of tumor invading the soft tissues of the chest wall
  - non-transmural involvement of the pericardium
- T4\*\* Tumor involves any of the ipsilateral pleural surfaces, with at least one of the following:
  - diffuse or multifocal invasion of soft tissues of the chest wall
  - any involvement of rib
  - invasion through the diaphragm to the peritoneum
  - invasion of any mediastinal organ(s)
  - direct extension to the contralateral pleura
  - invasion into the spine
  - extension to the internal surface of the pericardium
  - pericardial effusion with positive cytology
  - invasion of the myocardium
  - invasion of the brachial plexus

\*T3 describes locally advanced but potentially resectable tumor

\*\*T4 describes locally advanced, technically unresectable tumor

#### Regional Lymph Nodes (N)

- NX Regional lymph nodes cannot be assessed
- N0 No regional lymph node metastases
- N1 Metastases in the ipsilateral bronchopulmonary and/or hilar lymph node(s)
- N2 Metastases in the subcarinal lymph node(s) and/or the ipsilateral internal mammary or mediastinal lymph node(s)
- N3 Metastases in the contralateral mediastinal, internal mammary, or hilar lymph node(s) and/or the ipsilateral or contralateral supraclavicular or scalene lymph node(s)

#### Distant Metastasis (M)

- MX Distant metastases cannot be assessed
- M0 No distant metastasis
- M1 Distant metastasis

## STAGE GROUPING

Stage I	T1	N0	M0
Stage IA	T1a	N0	M0
Stage IB	T1b	N0	M0
Stage II	T2	N0	M0
Stage III	T1, T2	N1	M0
	T1, T2	N2	M0
	T3	N0, N1, N2	M0
Stage IV	T4	Any N	M0
	Any T	N3	M0
	Any T	Any N	M1

## HISTOPATHOLOGIC TYPE

There are four types of malignant pleural mesothelioma. They are listed here in descending order of frequency.

Epithelioid

Biphasic (at least 10% of both epithelioid and sarcomatoid components)

Sarcomatoid

Desmoplastic

In general, the pure epithelioid tumors are associated with a better prognosis than the biphasic or sarcomatoid tumors. Despite their bland histologic appearance, desmoplastic tumors appear to have the worst prognosis. The biology underlying these differences is not yet understood.

## BIBLIOGRAPHY

- Allen KB, Faber LP, Warren WH: Malignant pleural mesothelioma: extrapleural pneumonectomy and pleurectomy. *Chest Surg Clin N Amer* 4:113-126, 1994
- Boutin C, Rey F, Gouvernet J, Viallat J-R, Astoul P, Ledoray V: Thoracoscopy in pleural malignant mesothelioma: a prospective study of 188 consecutive patients. Part 2: Prognosis and staging. *Cancer* 72:394-404, 1993
- Butchart EG, Ashcroft T, Barnsley WC, Holden MP: Pleuro-pneumonectomy in the management of diffuse malignant mesothelioma of the pleura: experience with 29 patients. *Thorax* 31:15-24, 1976
- Pass HI, Temeck BK, Kranda K, Steinberg SM, Feuerstein IR: Preoperative tumor volume is associated with outcome in malignant pleural mesothelioma. *J Thorac Cardiovasc Surg* 115:310-318, 1998
- Pass HI, Temeck BK, Kranda K, et al: Phase III randomized trial of surgery with or without intraoperative photodynamic therapy and postoperative immunochemotherapy for malignant pleural mesothelioma. *Ann Surg Oncol* 4:628-633, 1997
- Patz EF Jr., Rusch VW, Heelan R: The proposed new international TNM staging system for malignant pleural mesothelioma: application to imaging. *Am J Roentgenol* 166:323-327, 1996
- Ruffie P, Feld R, Minkin S, et al: Diffuse malignant mesothelioma of the pleura in Ontario and Quebec: a retrospective study of 332 patients. *J Clin Oncol* 7:1157-1168, 1989
- Rusch VW, The International Mesothelioma Interest Group: A proposed new international TNM staging system for malignant pleural mesothelioma. *Chest* 108:1122-1128, 1995
- Rusch VW, Piantadosi S, Holmes EC: The role of extrapleural pneumonectomy in malignant pleural mesothelioma. *J Thorac Cardiovasc Surg* 102(1):1-9, 1991
- Rusch VW, Venkatraman ES: The importance of surgical staging in the treatment of malignant pleural mesothelioma. *J Thorac Cardiovasc Surg* 111:815-826, 1996
- Rusch VW, Venkatraman ES: Important prognostic factors in patients with malignant pleural mesothelioma, managed surgically. *Ann Thorac Surg* 68:1799-1804, 1999
- Sugarbaker DJ, Flores RM, Jaklitsch MT, et al: Resection margins, extrapleural nodal status, and cell type determine postoperative long-term survival in trimodality therapy of malignant pleural mesothelioma: results of 183 patients. *J Thorac Cardiovasc Surg* 117:54-65, 1999
- Sugarbaker DJ, Strauss GM, Lynch TJ, et al: Node status has prognostic significance in the multimodality therapy of diffuse, malignant mesothelioma. *J Clin Oncol* 11(6):1172-1178, 1993
- Tammilehto L, Kivisaari L, Salminen US, Maasilta P, Mattson K: Evaluation of the clinical TNM staging system for malignant pleural mesothelioma: an assessment in 88 patients. *Lung Cancer* 12:25-34, 1995

## HISTOLOGIES—PLEURAL MESOTHELIOMA

- 9050/3 Mesothelioma, malignant
- 9051/3 Fibrous mesothelioma, malignant
- 9052/3 Epithelioid mesothelioma, malignant
- 9053/3 Mesothelioma, biphasic, malignant

## PLEURAL MESOTHELIOMA

Hospital Name/Address
-----------------------

Patient Name/Information
--------------------------

Type of Specimen \_\_\_\_\_  
Tumor Size \_\_\_\_\_

Histopathologic Type \_\_\_\_\_  
Laterality:     Bilateral     Left     Right

### DEFINITIONS

Clinical	Pathologic	Primary Tumor (T)	
<input type="checkbox"/>	<input type="checkbox"/>	TX	Primary tumor cannot be assessed
<input type="checkbox"/>	<input type="checkbox"/>	T0	No evidence of primary tumor
<input type="checkbox"/>	<input type="checkbox"/>	T1	Tumor involves ipsilateral parietal pleura, with or without focal involvement of visceral pleura
<input type="checkbox"/>	<input type="checkbox"/>	T1a	Tumor involves ipsilateral parietal (mediastinal, diaphragmatic) pleura. No involvement of the visceral pleura
<input type="checkbox"/>	<input type="checkbox"/>	T1b	Tumor involves ipsilateral parietal (mediastinal, diaphragmatic) pleura, with focal involvement of the visceral pleura
<input type="checkbox"/>	<input type="checkbox"/>	T2	Tumor involves any of the ipsilateral pleural surfaces with at least one of the following: <ul style="list-style-type: none"> <li>• confluent visceral pleural tumor (including fissure)</li> <li>• invasion of diaphragmatic muscle</li> <li>• invasion of lung parenchyma</li> </ul>
<input type="checkbox"/>	<input type="checkbox"/>	T3 <sup>(1)</sup>	Tumor involves any of the ipsilateral pleural surfaces, with at least one of the following: <ul style="list-style-type: none"> <li>• invasion of the endothoracic fascia</li> <li>• invasion into mediastinal fat</li> <li>• solitary focus of tumor invading the soft tissues of the chest wall</li> <li>• non-transmural involvement of the pericardium</li> </ul>
<input type="checkbox"/>	<input type="checkbox"/>	T4 <sup>(2)</sup>	Tumor involves any of the ipsilateral pleural surfaces, with at least one of the following: <ul style="list-style-type: none"> <li>• diffuse or multifocal invasion of soft tissues of the chest wall</li> <li>• any involvement of rib</li> <li>• invasion through the diaphragm to the peritoneum</li> <li>• invasion of any mediastinal organ(s)</li> <li>• direct extension to the contralateral pleura</li> <li>• invasion into the spine</li> <li>• extension to the internal surface of the pericardium</li> <li>• pericardial effusion with positive cytology</li> <li>• invasion of the myocardium</li> <li>• invasion of the brachial plexus</li> </ul>
<b>Regional Lymph Nodes (N)</b>			
<input type="checkbox"/>	<input type="checkbox"/>	NX	Regional lymph nodes cannot be assessed
<input type="checkbox"/>	<input type="checkbox"/>	N0	No regional lymph node metastases
<input type="checkbox"/>	<input type="checkbox"/>	N1	Metastases in the ipsilateral bronchopulmonary and/or hilar lymph node(s)
<input type="checkbox"/>	<input type="checkbox"/>	N2	Metastases in the subcarinal lymph node(s) and/or the ipsilateral internal mammary or mediastinal lymph node(s)
<input type="checkbox"/>	<input type="checkbox"/>	N3	Metastases in the contralateral mediastinal, internal mammary, or hilar lymph node(s), and/or the ipsilateral or contralateral supraclavicular or scalene lymph node(s)

**Notes**  
1. T3 describes locally advanced but potentially resectable tumor  
2. T4 describes locally advanced, technically unresectable tumor

4

*(continued on reverse side)*

## PLEURAL MESOTHELIOMA

Clinical	Pathologic	<b>Distant Metastasis (M)</b>	
<input type="checkbox"/>	<input type="checkbox"/>	MX	Distant metastases cannot be assessed
<input type="checkbox"/>	<input type="checkbox"/>	M0	No distant metastasis
<input type="checkbox"/>	<input type="checkbox"/>	M1	Distant metastasis
Biopsy of metastatic site performed..... IY..... <input type="checkbox"/> N			
Source of pathologic metastatic specimen _____			

### Notes

#### Additional Descriptors

**Lymphatic Vessel Invasion (L)**  
LX Lymphatic vessel invasion cannot be assessed

L0 No lymphatic vessel invasion

L1 Lymphatic vessel invasion

#### Venous Invasion (V)

VX Venous invasion cannot be assessed

V0 No venous invasion

V1 Microscopic venous invasion

V2 Macroscopic venous invasion

<b>Stage Grouping</b>					
<input type="checkbox"/>	<input type="checkbox"/>	I	T1	N0	M0
<input type="checkbox"/>	<input type="checkbox"/>	IA	T1a	N0	M0
<input type="checkbox"/>	<input type="checkbox"/>	IB	T1b	N0	M0
<input type="checkbox"/>	<input type="checkbox"/>	II	T2	N0	M0
<input type="checkbox"/>	<input type="checkbox"/>	III	T1, T2	N1	M0
<input type="checkbox"/>	<input type="checkbox"/>		T1, T2	N2	M0
<input type="checkbox"/>	<input type="checkbox"/>		T3	N0, N1, N2	M0
<input type="checkbox"/>	<input type="checkbox"/>	IV	T4	Any N	M0
<input type="checkbox"/>	<input type="checkbox"/>		Any T	N3	M0
<input type="checkbox"/>	<input type="checkbox"/>		Any T	Any N	M1

#### Residual Tumor (R)

- RX Presence of residual tumor cannot be assessed
- R0 No residual tumor
- R1 Microscopic residual tumor
- R2 Macroscopic residual tumor

#### Additional Descriptors

For identification of special cases of TNM or pTNM classifications, the "m" suffix and "y," "r," and "a" prefixes are used. Although they do not affect the stage grouping, they indicate cases needing separate analysis.

- m suffix** indicates the presence of multiple primary tumors in a single site and is recorded in parentheses: pT(m)NM.
- y prefix** indicates those cases in which classification is performed during or following initial multimodality therapy. The cTNM or pTNM category is identified by a "y" prefix. The ycTNM or ypTNM categorizes the extent of tumor actually present at the time of that examination. The "y" categorization is not an estimate of tumor prior to multimodality therapy.
- r prefix** indicates a recurrent tumor when staged after a disease-free interval, and is identified by the "r" prefix: rTNM.
- a prefix** designates the stage determined at autopsy: aTNM.

#### Prognostic Indicators (if applicable)

Physician's Signature _____	Date _____
-----------------------------	------------



# **PART V**

## **Musculoskeletal Sites**

## Bone

*(Primary malignant lymphoma and multiple myeloma are not included.)*

C40.0 Long bones of upper limb, scapula, and associated joints	C40.8 Overlapping lesion of bones, joints, and articular cartilage of limbs	C41.3 Rib, sternum, clavicle, and associated joints
C40.1 Short bones of upper limb and associated joints	C40.9 Bone of limb, NOS	C41.4 Pelvic bones, sacrum, coccyx, and associated joints
C40.2 Long bones of lower limb and associated joints	C41.0 Bones of skull and face and associated joints	C41.8 Overlapping lesion of bones, joints, and articular cartilage
C40.3 Short bones of lower limb and associated joints	C41.1 Mandible	C41.9 Bone, NOS
	C41.2 Vertebral column	

### SUMMARY OF CHANGES

- T1 has changed from “Tumor confined within the cortex” to “Tumor 8 cm or less in greatest dimension.”
- T2 has changed from “Tumor invades beyond the cortex” to “Tumor more than 8 cm in greatest dimension.”
- T3 designation of skip metastasis is defined as “Discontinuous tumors in the primary bone site.” This designation is a Stage III tumor that was not previously defined.
- M1 lesions have been divided into M1a and M1b.
- M1a is lung-only metastases.
- M1b is metastases to other distant sites, including lymph nodes.
- In the Stage Grouping, Stage IVA is M1a, and Stage IVB is M1b.

### INTRODUCTION

This classification is used for all primary malignant tumors of bone except primary malignant lymphoma and multiple myeloma. Cases are categorized by histologic type (e.g., osteosarcoma, chondrosarcoma) and by histologic grade of differentiation.

### ANATOMY

**Primary Site.** All bones of the skeleton.

**Regional Lymph Nodes.** Regional lymph metastases from bone tumors is extremely rare.

**Metastatic Sites.** A metastatic site includes any site beyond the regional lymph nodes of the primary site. Spread to the lungs is frequent.

### RULES FOR CLASSIFICATION

**Clinical Staging.** Clinical staging includes all relevant data prior to primary definitive therapy, including physical examination, imaging, and biopsy.

The radiograph remains the mainstay in determining whether a lesion of bone requires further staging and usually is the modality that permits reliable prediction of the probable histology of a lesion of bone.

Staging of all potentially malignant tumors of bone is most accurately achieved by magnetic resonance (MR) imaging. Axial imaging, complemented by either coronal or sagittal imaging planes using T1 and T2 weighted SPIN echo sequences, most often provides accurate depiction of intra- and extraosseous tumor. To improve conspicuity in locations such as the pelvis or vertebrae, these sequences could be augmented by fat-suppressed pulse sequences. The maximum

dimension of the tumor must be measured prior to any treatment.

Computerized tomography has a limited role in local staging of tumors but remains the examination of choice for evaluating the thorax for metastatic disease. In those situations, usually in flat bones such as the pelvis, scapula, or posterior elements of the vertebrae where characterization of a lesion by radiography may be incomplete or difficult because of inadequate visualization of the matrix of a lesion, CT is preferred to MR imaging. The role of CT in these circumstances is to characterize the lesion and determine whether it is potentially malignant or not, and the obtained CT images may suffice for local staging.

Technetium scintigraphy is the examination of choice for evaluating the entire skeleton to determine whether there are multiple lesions. The role of positron emission tomography (PET) in the evaluation and staging of bone sarcomas, if any, has not yet been determined.

Biopsy of the tumor completes the staging process, and the location of the biopsy must be carefully planned to allow for eventual en bloc resection of a malignant neoplasm together with the entire biopsy tract. Staging of the lesion should precede biopsy. Imaging the tumor after biopsy may compromise the accuracy of the staging process. The pathologic diagnosis is based on the microscopic examination of tissue, correlated with imaging studies.

**Pathologic Staging.** Pathologic staging includes pathologic data obtained from examination of a resected specimen sufficient to evaluate the highest T category, histopathologic type and grade, regional lymph nodes as appropriate, or distant metastasis. Because regional lymph node involvement from bone tumors is rare, the pathologic stage grouping includes any of the following combinations: pT pG pN pM, or pT pG cN cM, or cT cN pM.

## DEFINITION OF TNM

### Primary Tumor (T)

- TX Primary tumor cannot be assessed
- T0 No evidence of primary tumor
- T1 Tumor 8 cm or less in greatest dimension
- T2 Tumor more than 8 cm in greatest dimension
- T3 Discontinuous tumors in the primary bone site

### Regional Lymph Nodes (N)

- NX Regional lymph nodes cannot be assessed
- N0 No regional lymph node metastasis
- N1 Regional lymph node metastasis

*Note:* Because of the rarity of lymph node involvement in sarcomas, the designation NX may not be appropriate and could be considered N0 if no clinical involvement is evident.

### Distant Metastasis (M)

- MX Distant metastasis cannot be assessed
- M0 No distant metastasis
- M1 Distant metastasis
- M1a Lung
- M1b Other distant sites

## STAGE GROUPING

Stage IA	T1	N0	M0	G1,2 Low grade
Stage IB	T2	N0	M0	G1,2 Low grade
Stage IIA	T1	N0	M0	G3,4 High grade
Stage IIB	T2	N0	M0	G3,4 High grade
Stage III	T3	N0	M0	Any G
Stage IVA	Any T	N0	M1a	Any G
Stage IVB	Any T	N1	Any M	Any G
	Any T	Any N	M1b	Any G

## HISTOLOGIC GRADE (G)

- GX Grade cannot be assessed
- G1 Well differentiated—Low Grade
- G2 Moderately differentiated—Low Grade
- G3 Poorly differentiated—High Grade
- G4 Undifferentiated—High Grade

*Note:* Ewing's sarcoma is classified as G4.

## CLASSIFICATION OF PRIMARY MALIGNANT BONE TUMORS

- I. Osteosarcoma
  - A. Intramedullary high grade
    1. Osteoblastic
    2. Chondroblastic
    3. Fibroblastic
    4. Mixed
    5. Small cell
    6. Other (telangiectatic, epithelioid, chondromyxoid fibroma-like, chondroblastoma-like, osteoblastoma-like, giant cell rich)
  - B. Intramedullary low grade
  - C. Juxtacortical high grade (high grade surface osteosarcoma)
  - D. Juxtacortical intermediate grade chondroblastic (periosteal osteosarcoma)
  - E. Juxtacortical low grade (parosteal osteosarcoma)
- II. Chondrosarcoma
  - A. Intramedullary
    1. Conventional (hyaline/myxoid)
    2. Clear cell
    3. Dedifferentiated
    4. Mesenchymal
  - B. Juxtacortical



- III. Primitive neuroectodermal tumor/Ewing's sarcoma
- IV. Angiosarcoma
  - A. Conventional
  - B. Epithelioid hemangioendothelioma
- V. Fibrosarcoma/malignant fibrous histiocytoma
- VI. Chordoma
  - A. Conventional
  - B. Dedifferentiated
- VII. Adamantinoma
  - A. Conventional
  - B. Well differentiated–osteofibrous dysplasia-like
- VIII. Other
  - A. Liposarcoma
  - B. Leiomyosarcoma
  - C. Malignant peripheral nerve sheath tumor
  - D. Rhabdomyosarcoma
  - E. Malignant mesenchymoma
  - F. Malignant hemangiopericytoma
  - G. Sarcoma, NOS; primary malignant lymphoma; and multiple myeloma are not included.

## PROGNOSTIC FACTORS

Known prognostic factors for malignant bone tumors are as follows: (1) T1 tumors have a better prognosis than T2 tumors. (2) Histopathologic low grade (G1, G2) has a better prognosis than high grade (G3, G4). (3) Location of the primary tumor is a prognostic factor. Patients who have an anatomically resectable primary tumor have a better prognosis than those with a non-resectable tumor, and tumors of the spine and pelvis tend to have a poor prognosis. (4) The size of the primary tumor is a prognostic factor for osteosarcoma and Ewing's sarcoma. Ewing's sarcoma patients with a tumor 8 cm or less in greatest dimension have a better prognosis than those with a tumor greater than 8 cm. Osteosarcoma patients with a tumor 9 cm or less in greatest dimension have a better prognosis than those with a tumor greater than 9 cm. (5) Patients who have a localized primary tumor have a better prognosis than those with metastases. (6) Certain metastatic sites are associated with a poorer prognosis than other sites: bony and hepatic metastases convey a much worse prognosis than do lung metastases, and patients with solitary lung metastases have a better prognosis than those with multiple lung lesions. (7) Histologic response of the primary tumor to chemotherapy is a prognostic factor for osteosarcoma and Ewing's sarcoma. Those patients with a "good" response, >90% tumor necrosis, have a better prognosis than those with less necrosis. (8) Recent studies have shown that the biologic behavior of osteosarcoma and Ewing's sarcoma is related to specific molecular abnormalities identified in these neoplasms. The prognostically relevant molecular aberrations can be classified into the broad categories of gene translocations, expression of multidrug-resistance genes, expression of growth factor receptors, and mutations in cell cycle regulators. Specifically, Ewing's sarcomas having the EWS-FL1 type 1 translocation, which appears to

code for a weaker transactivator, have a better prognosis than those that have other types of translocations. Studies examining the expression of the multidrug-resistance gene MDR1 and its protein product P-glycoprotein in osteosarcoma have reported conflicting results; some investigations have shown that the expression of P-glycoprotein is associated with a poor outcome, whereas a prospective analysis did not find a correlation with MDR1 RNA expression and disease progression. High levels of expression of the c-erbB-2 proto-oncogene, which encodes the human epidermal growth factor receptor 2 (HER2), in osteosarcomas, has been shown to correlate with an inferior histologic response of tumors to preoperative chemotherapy, as well as with decreased patient event-free survival. In Ewing's sarcoma, the status of the cell cycle regulators P53 and INK4A has been shown to correlate with outcome; tumors that express P53 or have a deletion of INK4A have a poorer outcome than those that do not demonstrate these abnormalities. It is anticipated that future investigations on the molecular profile of bone sarcomas will provide valuable information regarding their genesis and prognosis.

## BIBLIOGRAPHY

- Bacci G, Ferrari S, Bertoni F, et al: Prognostic factors in non-metastatic Ewing's sarcoma of bone treated with adjuvant chemotherapy: analysis of 359 patients at the Istituto Ortopedico Rizzoli. *J Clin Oncol* 18:4–11, 2000
- Baldini M, Scottani K, Barbanti-Brodano G, et al: Expression of P-glycoprotein in high-grade osteosarcomas in relation to clinical outcome. *N Engl J Med* 333:1380–1385, 1995
- Bieling P, Rehan N, Winkler P, et al: Tumor size and prognosis in aggressively treated osteosarcoma. *J Clin Oncol* 14(3): 848–858, 1996
- Cotterill SJ, Ahrens S, Paulussen M, et al: Prognostic factors in Ewing's tumor of bone: analysis of 975 patients from the European Intergroup Cooperative Ewing's Sarcoma Study Group. *J Clin Oncol* 18:3108–3114, 2000
- Davis A, Bell R, Goodwin P: Prognostic factors in osteosarcoma: a critical review. *J Clin Oncol* 12(2):423–431, 1994
- de Alva E, Antonescu CR, Panizo A, et al: Prognostic impact of P53 status in Ewing sarcoma. *Cancer*; 89:783–792, 2000
- de Alva E, Kawai A, Healey JH, et al: EWS-FL11 fusion transcript structure is an independent determinant of prognosis in Ewing's sarcoma. *J Clin Oncol* 16:1248–1255, 1998
- Enneking WF, Spanier S, Goodman M: A system for the surgical staging of musculoskeletal sarcoma. *Clin Orth and Rel Research* No. 153, 106–120, 1980
- Evans R, Nesbit M, Askin F, et al: Local recurrence, rate and sites of metastases, and time to relapse as a function of treatment regimen, size of primary and surgical history in 62 patients presenting with nonmetastatic Ewing's sarcoma of the pelvic bones. *Int J Radiat Oncol Biol Phys* 11:129–136, 1985
- Glasser DB, Lane JM, Huvos AG, et al: Survival, prognosis and therapeutic response in osteosarcoma: the Memorial Hospital experience. *Cancer* 67:698–708, 1992
- Gorlick R, Hubos AG, Heller G, et al: Expression of HER2/erbB-2 correlates with survival in osteosarcoma. *J Clin Oncol* 17:2781–2788, 1999

- Hornicek FJ, Gebhardt MC, Wolfe M, et al: P-glycoprotein levels predict poor outcome in patients with osteosarcoma. *Clin Orthop and Rel Research* 373:11–17, 2000
- Mankin HJ, Mankin CJ, Simon MA: The hazards of biopsy, revisited. *J Bone and Joint Surg* 78A:659–663, 1996
- Peabody TD, Gibbs CP, Simon MA: Evaluation and staging of musculoskeletal neoplasms. *J Bone and Joint Surg* 80A:1204–1218, 1998
- Scully SP, Temple HT, Okeefe RJ, et al: Role of surgical resection in pelvic Ewing's sarcoma. *J Clin Oncol* 13(9):2336–2341, 1995
- Simon MA, Bierman JS: Biopsy of bone and soft-tissue lesions. *J Bone and Joint Surg* 75A:616–621, 1993
- Sundaram M, McDonald DJ: Magnetic resonance imaging in the evaluation of the solitary tumor of bone. *Current Opinion in Radiology* 2:697–702, 1990
- Sundaram M, McDonald DJ: The solitary tumor or tumor-like lesion of bone. *Top Magn Reson Imag* 1(4):17–29, 1989
- Sundaram M, McGuire MH: Computed tomography or magnetic resonance for evaluating the solitary tumor or tumor-like lesion of bone? *Skeletal Radiology* 17:393–401, 1988
- Ward WG, Mikaelian K, Dorey F, et al: Pulmonary metastases of stage IIB extremity osteosarcoma and subsequent pulmonary metastases. *J Clin Oncol* 12(9):1849–1858, 1994
- Wei G, Antonescu CR, de Alva E, et al: Prognostic impact of INK4A deletion in Ewing sarcoma. *Cancer* 89:793–799, 2000
- Wuisman P, Enneking WF: Prognosis for patients who have osteosarcoma with skip metastasis. *J Bone and Joint Surg* 72A(1):60–68, 1990
- Wunder JS, Bull SB, Aneliunas V, et al: MDR1 gene expression and outcome in osteosarcoma: a prospective, multicenter study. *J Clin Oncol* 18:2685–2694, 2000

## HISTOLOGIES—BONE

- |        |                         |        |   |
|--------|-------------------------|--------|---|
| 8810/3 | Fibrosarcoma, NOS       | 8830/3 | Malignant fibrous histiocytoma                |
| 8812/3 | Periosteal fibrosarcoma | 8850/3 | Liposarcoma, NOS                              |
| 8814/3 | Infantile fibrosarcoma  | 8890/3 | Leiomyosarcoma, NOS                           |
|        |                         | 8900/3 | Rhabdomyosarcoma, NOS                         |
|        |                         | 8990/3 | Malignant mesenchymoma                        |
|        |                         | 9120/3 | Angiosarcoma, NOS                             |
|        |                         | 9130/3 | Hemangioendothelioma, malignant               |
|        |                         | 9133/3 | Epithelioid hemangioendothelioma, malignant   |
|        |                         | 9150/3 | Hemangiopericytoma, malignant                 |
|        |                         | 9170/3 | Lymphangiosarcoma                             |
|        |                         | 9180/3 | Osteosarcoma, NOS                             |
|        |                         | 9181/3 | Chondroblastic osteosarcoma                   |
|        |                         | 9182/3 | Fibroblastic osteosarcoma                     |
|        |                         | 9183/3 | Telangiectatic osteosarcoma                   |
|        |                         | 9184/3 | Osteosarcoma in Paget disease of bone         |
|        |                         | 9185/3 | Small cell osteosarcoma                       |
|        |                         | 9186/3 | Central osteosarcoma                          |
|        |                         | 9187/3 | Intraosseous well differentiated osteosarcoma |
|        |                         | 9192/3 | Parosteal osteosarcoma                        |
|        |                         | 9193/3 | Periosteal osteosarcoma                       |
|        |                         | 9194/3 | High grade surface osteosarcoma               |
|        |                         | 9195/3 | Intracortical osteosarcoma                    |
|        |                         | 9220/3 | Chondrosarcoma, NOS                           |
|        |                         | 9221/3 | Juxtacortical chondrosarcoma                  |
|        |                         | 9230/3 | Chondroblastoma, malignant                    |
|        |                         | 9231/3 | Myxoid chondrosarcoma                         |
|        |                         | 9240/3 | Mesenchymal chondrosarcoma                    |
|        |                         | 9242/3 | Clear cell chondrosarcoma                     |
|        |                         | 9243/3 | Dedifferentiated chondrosarcoma               |
|        |                         | 9250/3 | Giant cell tumor of bone, malignant           |
|        |                         | 9260/3 | Ewing sarcoma                                 |
|        |                         | 9261/3 | Adamantinoma of long bones                    |
|        |                         | 9310/3 | Adamantinoma, malignant                       |
|        |                         | 9364/3 | Peripheral neuroectodermal tumor              |
|        |                         | 9370/3 | Chordoma, NOS                                 |
|        |                         | 9371/3 | Chondroid chordoma                            |
|        |                         | 9372/3 | Dedifferentiated chordoma                     |
|        |                         | 9540/3 | Malignant peripheral nerve sheath tumor       |
|        |                         | 9560/3 | Neurilemoma, malignant                        |

**BONE**

**Hospital Name/Address**

**Patient Name/Information**

Type of Specimen \_\_\_\_\_

Histopathologic Type \_\_\_\_\_

Tumor Size \_\_\_\_\_

Laterality:     Bilateral     Left     Right

**DEFINITIONS**

<i>Clinical</i>	<i>Pathologic</i>	<b>Primary Tumor (T)</b>
<input type="checkbox"/>	<input type="checkbox"/>	TX    Primary tumor cannot be assessed
<input type="checkbox"/>	<input type="checkbox"/>	T0    No evidence of primary tumor
<input type="checkbox"/>	<input type="checkbox"/>	T1    Tumor 8 cm or less in greatest dimension
<input type="checkbox"/>	<input type="checkbox"/>	T2    Tumor more than 8 cm in greatest dimension
<input type="checkbox"/>	<input type="checkbox"/>	T3    Discontinuous tumors in the primary bone site

<i>Clinical</i>	<i>Pathologic</i>	<b>Regional Lymph Nodes (N)</b>
<input type="checkbox"/>	<input type="checkbox"/>	NX    Regional lymph nodes cannot be assessed <sup>(1)</sup>
<input type="checkbox"/>	<input type="checkbox"/>	N0    No regional lymph node metastasis
<input type="checkbox"/>	<input type="checkbox"/>	N1    Regional lymph node metastasis

<i>Clinical</i>	<i>Pathologic</i>	<b>Distant Metastasis (M)</b>
<input type="checkbox"/>	<input type="checkbox"/>	MX    Distant metastasis cannot be assessed
<input type="checkbox"/>	<input type="checkbox"/>	M0    No distant metastasis
<input type="checkbox"/>	<input type="checkbox"/>	M1    Distant metastasis
<input type="checkbox"/>	<input type="checkbox"/>	M1a    Lung
<input type="checkbox"/>	<input type="checkbox"/>	M1b    Other distant sites
		Biopsy of metastatic site performed ..... <input type="checkbox"/> Y ..... <input type="checkbox"/> N
		Source of pathologic metastatic specimen _____

<i>Clinical</i>	<i>Pathologic</i>	<b>Stage Grouping</b>
<input type="checkbox"/>	<input type="checkbox"/>	IA    T1    N0    M0    G1,2    Low grade
<input type="checkbox"/>	<input type="checkbox"/>	IB    T2    N0    M0    G1,2    Low grade
<input type="checkbox"/>	<input type="checkbox"/>	IIA    T1    N0    M0    G3,4    High grade
<input type="checkbox"/>	<input type="checkbox"/>	IIB    T2    N0    M0    G3,4    High grade
<input type="checkbox"/>	<input type="checkbox"/>	III    T3    N0    M0    Any G
<input type="checkbox"/>	<input type="checkbox"/>	IVA    Any T    N0    M1a    Any G
<input type="checkbox"/>	<input type="checkbox"/>	IVB    Any T    N1    Any M    Any G
		Any T    Any N    M1b    Any G

**Notes**

1. Because of the rarity of lymph node involvement in sarcomas, the designation NX may not be appropriate and could be considered N0 if no clinical involvement is evident.

2. Ewing's sarcoma is classified as G4.

**5**

*(continued on reverse side)*

**Histologic Grade (G)**

- GX Grade cannot be assessed
- G1 Well differentiated—Low Grade
- G2 Moderately differentiated—Low Grade
- G3 Poorly differentiated—High Grade
- G4 Undifferentiated—High Grade<sup>(2)</sup>

**Residual Tumor (R)**

- RX Presence of residual tumor cannot be assessed
- R0 No residual tumor
- R1 Microscopic residual tumor
- R2 Macroscopic residual tumor

**Additional Descriptors**

For identification of special cases of TNM or pTNM classifications, the “m” suffix and “y,” “r,” and “a” prefixes are used. Although they do not affect the stage grouping, they indicate cases needing separate analysis.

- m suffix** indicates the presence of multiple primary tumors in a single site and is recorded in parentheses: pT(m)NM.
- y prefix** indicates those cases in which classification is performed during or following initial multimodality therapy. The cTNM or pTNM category is identified by a “y” prefix. The ycTNM or ypTNM categorizes the extent of tumor actually present at the time of that examination. The “y” categorization is not an estimate of tumor prior to multimodality therapy.
- r prefix** indicates a recurrent tumor when staged after a disease-free interval, and is identified by the “r” prefix: rTNM.
- a prefix** designates the stage determined at autopsy: aTNM.

**Prognostic Indicators**

**Notes**

**Additional Descriptors**

- Lymphatic Vessel Invasion (L)**  
 LX Lymphatic vessel invasion cannot be assessed  
 L0 No lymphatic vessel invasion  
 L1 Lymphatic vessel invasion
- Venous Invasion (V)**  
 VX Venous invasion cannot be assessed  
 V0 No venous invasion  
 V1 Microscopic venous invasion  
 V2 Macroscopic venous invasion

Physician's Signature \_\_\_\_\_ Date \_\_\_\_\_

## Soft Tissue Sarcoma

*(Kaposi's sarcoma, dermatofibrosarcoma protuberans, fibromatosis [desmoid tumor], and sarcoma arising from the dura mater, brain, parenchymatous organs, or hollow viscera are not included.)*

C38.0 Heart	C47.5 Peripheral nerves and autonomic nervous system of pelvis	C49.2 Connective, subcutaneous, and other soft tissues of lower limb and hip
C38.1 Anterior mediastinum	C47.6 Peripheral nerves and autonomic nervous system of trunk, NOS	C49.3 Connective, subcutaneous, and other soft tissues of thorax
C38.2 Posterior mediastinum	C47.8 Overlapping lesion of peripheral nerves and autonomic nervous system	C49.4 Connective, subcutaneous, and other soft tissues of abdomen
C38.3 Mediastinum, NOS	C47.9 Autonomic nervous system, NOS	C49.5 Connective, subcutaneous, and other soft tissues of pelvis
C38.8 Overlapping lesion of heart, mediastinum, and pleura	C48.0 Retroperitoneum	C49.6 Connective, subcutaneous, and other soft tissues of trunk, NOS
C47.0 Peripheral nerves and autonomic nervous system of head, face, and neck	C48.1 Specified parts of peritoneum	C49.8 Overlapping lesion of connective, subcutaneous, and other soft tissues
C47.1 Peripheral nerves and autonomic nervous system of upper limb and shoulder	C48.2 Peritoneum, NOS	C49.9 Connective, subcutaneous, and other soft tissues, NOS
C47.2 Peripheral nerves and autonomic nervous system of lower limb and hip	C48.8 Overlapping lesion of retroperitoneum and peritoneum	
C47.3 Peripheral nerves and autonomic nervous system of thorax	C49.0 Connective, subcutaneous, and other soft tissues of head, face, and neck	
C47.4 Peripheral nerves and autonomic nervous system of abdomen	C49.1 Connective, subcutaneous, and other soft tissues of upper limb and shoulder	

### SUMMARY OF CHANGES

- Angiosarcoma and malignant mesenchymoma are no longer included in the list of histologic types for this site.
- Gastrointestinal stromal tumor and Ewing's sarcoma/primitive neuroectodermal tumor have been added to the list of histologic types for this site.
- Fibrosarcoma grade I has been replaced by fibromatosis (desmoid tumor) in the list of histologic types *not* included in this site.
- G 1–2, T2b, N0 M0 tumors have been reclassified as Stage I rather than Stage II disease.

### INTRODUCTION

The staging system applies to all soft tissue sarcomas except Kaposi's sarcoma, dermatofibrosarcoma, infantile fibrosarcoma, and angiosarcoma. In addition, sarcomas arising within the confines of the dura mater, including the brain, and sarcomas arising in parenchymatous organs

and from hollow viscera are not optimally staged by this system.

Data to support this staging system are based on current analyses from multiple institutions and represent the recommendations of an AJCC task force on soft tissue sarcoma. In the era of cytoreductive neoadjuvant treatments, clinical and pathologic staging may be altered in the future. Because

pathologic staging drives adjuvant therapy decisions, patients should be restaged after neoadjuvant therapies have been administered.

Histologic type, grade, and tumor size and depth are essential for staging. Histologic grade of a sarcoma is one of the most important parameters of the staging system. Grade is based on analysis of various pathologic features of a tumor, such as histologic subtype, degree of differentiation, mitotic activity, and necrosis. Accurate grading requires an adequate sample of well-fixed tissue for evaluation. Accurate grading is not always possible on the basis of needle biopsies or in tumors that have been previously irradiated or treated with chemotherapy.

The current staging system does not take into account anatomic site. However, anatomic site is known to influence outcome, and therefore outcome data should be reported specifying site. Generic grouping of site is accepted. The following site groups can be used for reports that include sarcomas arising in tissues other than soft tissues (such as parenchymal organs). Extremity and superficial trunk can be combined; viscera, including all the intra-abdominal viscera, can also be combined. Where enough numbers exist, these can be reported by subdivision into the various components of the gastrointestinal tract. Lung, gastrointestinal, genitourinary, and gynecologic sarcomas should be grouped separately.

#### **Site Groups for Soft Tissue Sarcoma**

Head and neck  
Extremity and superficial trunk  
Gastrointestinal  
Genitourinary  
Visceral  
Retroperitoneal  
Gynecologic  
Breast  
Lung, pleura, mediastinum  
Other

## **STAGING OF SOFT TISSUE SARCOMA**

**Inclusions.** The present staging system applies to soft tissue sarcomas. Primary sarcomas can arise from a variety of soft tissues. These tissues include fibrous connective tissue, fat, smooth or striated muscle, vascular tissue, peripheral neural tissue, and visceral tissue.

**Regional Lymph Nodes.** Involvement of regional lymph nodes by soft tissue sarcomas is uncommon in adults. When present, regional nodal disease has prognostic significance similar to that of visceral metastatic disease.

**Metastatic Sites.** Metastatic sites for soft tissue sarcoma are often dependent on the original site of the primary lesion. For example, the most common site of metastatic disease for patients with extremity sarcoma is the lung, whereas retro-

peritoneal and gastrointestinal sarcomas often have liver as the first site of metastasis.

## **RULES FOR CLASSIFICATION**

**Clinical Staging.** Clinical staging is dependent on characteristics of T, N, and M. T is divided into lesions of maximum dimension 5 cm or less and lesions of more than 5 cm in greatest dimension. Tumor size can be measured clinically or radiologically. Metastatic disease should be described according to the most likely sites of metastasis. In general, the minimal clinical staging workup of soft tissue sarcoma is accomplished by axial imaging of the involved site using MRI or CT scan and by imaging of the lungs, the most likely site for occult metastatic disease, using chest CT scans.

**Pathologic Staging.** Pathologic (pTNM) staging consists of the removal and pathologic evaluation of the primary tumor and clinical/radiologic evaluation for regional and distant metastases. In circumstances where it is not possible to obtain accurate measurements of the excised primary sarcoma specimen, it is acceptable to use radiologic assessment to assign a pT stage using the dimensions of the sarcoma. In examining the primary tumor, the pathologist should subclassify the lesion and assign a histopathologic grade via an accepted grading system. Occasionally, immunohistochemistry or cytogenetics may be necessary for accurate assignment of subtype.

**Definition of T.** Although size is currently designated as  $\leq 5$  cm or  $> 5$  cm, particular emphasis should be placed on providing size measurements (or even volume determinants) in sites other than the extremity or superficial trunk. Size should be regarded as a continuous variable, with 5 cm as merely an arbitrary division that makes it possible to dichotomize patient populations.

**Depth.** Depth is evaluated relative to the investing fascia of the extremity and trunk. *Superficial* is defined as lack of any involvement of the superficial investing muscular fascia in extremity or trunk lesions. For staging, all retroperitoneal and visceral lesions are considered to be deep lesions.

Depth is also an independent variable, and is defined as follows:

1. Superficial
  - a. Lesion does not involve superficial fascia.
2. Deep
  - a. Lesion is deep to, or involves, the superficial fascia.
  - b. All intraperitoneal visceral lesions, retroperitoneal lesions intrathoracic lesions, and the majority of head and neck tumors are considered deep.
3. Depth is evaluated in relation to tumor size (T):
  - a. Tumor  $\leq 5$  cm: T1a = superficial, T1b = deep
  - b. Tumor  $> 5$  cm: T2a = superficial, T2b = deep

**Nodal Disease.** Nodal involvement is rare in adult soft tissue sarcomas and has a very poor prognosis when evident. The outcome of patients with N1 disease is similar to those with M1 disease. In the assigning of stage group, patients whose nodal status is not determined to be positive for tumor, either clinically or pathologically, should be designated as N0.

**Grade.** Grade should be assigned to all sarcomas. A number of published grading systems exist; these vary in the number of tiers or grade groupings. Because many clinicians prefer a two-tiered system (“low” versus “high” grade) for recording data, the current staging system accommodates this approach. As a result, new recommendations for the translation of three- and four-tiered systems into a two-tiered system are suggested. In the most commonly employed three-tiered systems, Grade 1 will be considered “low grade” and Grades 2 and 3 “high grade.” In the less common four-tiered systems, Grades 1 and 2 will be considered “low grade” and Grades 3 and 4 “high grade.” However, it should be remembered that grade, like size, is a continuous variable in which arbitrary distinctions have been made to facilitate the evaluation of data.

**Restaging of Recurrent Tumors.** The same staging should be used when a patient requires restaging of sarcoma recurrence. Such reports should specify whether patients have primary lesions or lesions that were previously treated and have subsequently recurred. The identification and reporting of etiologic factors such as radiation exposure and inherited or genetic syndromes are encouraged. Appropriate workup for recurrent sarcoma should include cross-sectional imaging (CT scan or MRI scan) of the tumor, a CT scan of the chest, and a tissue biopsy to confirm diagnosis prior to initiation of therapy.

## DEFINITION OF TNM

### Primary Tumor (T)

- TX Primary tumor cannot be assessed
- T0 No evidence of primary tumor
- T1 Tumor 5 cm or less in greatest dimension
  - T1a superficial tumor
  - T1b deep tumor
- T2 Tumor more than 5 cm in greatest dimension
  - T2a superficial tumor
  - T2b deep tumor

*Note:* Superficial tumor is located exclusively above the superficial fascia without invasion of the fascia; deep tumor is located either exclusively beneath the superficial fascia, superficial to the fascia with invasion of or through the fascia, or both superficial yet beneath the fascia. Retroperitoneal, mediastinal, and pelvic sarcomas are classified as deep tumors.

### Regional Lymph Nodes (N)

- NX Regional lymph nodes cannot be assessed
- N0 No regional lymph node metastasis
- N1\* Regional lymph node metastasis

\**Note:* Presence of positive nodes (N1) is considered Stage IV.

### Distant Metastasis (M)

- MX Distant metastasis cannot be assessed
- M0 No distant metastasis
- M1 Distant metastasis

## STAGE GROUPING

Stage I	T1a, 1b, 2a, 2b	N0	M0	G1–2	G1	Low
Stage II	T1a, 1b, 2a	N0	M0	G3–4	G2–3	High
Stage III	T2b	N0	M0	G3–4	G2–3	High
Stage IV	Any T	N1	M0	Any G	Any G	High or Low
	Any T	N0	M1	Any G	Any G	High or Low

## HISTOLOGIC GRADE (G)

- GX Grade cannot be assessed
- G1 Well differentiated
- G2 Moderately differentiated
- G3 Poorly differentiated
- G4 Poorly differentiated or undifferentiated (four-tiered systems only)

## HISTOPATHOLOGIC TYPE

Tumors included in the soft tissue category are listed below:

- Alveolar soft-part sarcoma
- Desmoplastic small round cell tumor
- Epithelioid sarcoma
- Clear cell sarcoma
- Chondrosarcoma, extraskeletal
- Osteosarcoma, extraskeletal
- Gastrointestinal stromal tumor
- Ewing’s sarcoma/primitive neuroectodermal tumor
- Fibrosarcoma
- Leiomyosarcoma
- Liposarcoma
- Malignant fibrous histiocytoma
- Malignant hemangiopericytoma
- Malignant peripheral nerve sheath tumor
- Rhabdomyosarcoma
- Synovial sarcoma
- Sarcoma, NOS

**TABLE 22.1.** Five-year survival rates in extremity soft tissue sarcoma

Stage	N	Freedom from Local Recurrence	Disease-free Survival	Overall Survival
I	137	88.04%	86.13%	90.00%
II	491	81.97%	71.68%	80.89%
III	469	83.44%	51.77%	56.29%

Local recurrence, disease-free survival, and overall survival by stage. Source: Memorial Sloan-Kettering Cancer Center (MSKCC) for the time period of 7/1/82 to 6/30/00.

The following histologic types are *not* included: angiosarcoma, dermatofibrosarcoma protuberans, inflammatory myofibroblastic tumor, fibromatosis (desmoid tumor), mesothelioma, sarcomas arising in tissues apart from soft tissue (e.g., parenchymal organs). Malignant mesenchymoma has been deleted because it is a diagnostic term that is no longer used.

## PROGNOSTIC FACTORS

**Neurovascular and Bone Invasion.** In earlier staging systems, neurovascular and bone invasion by soft tissue sarcomas had been included as a determinant of stage. It is not included in the current staging system, and no plans are proposed to add it at the present time. Nevertheless, neurovascular and bone invasion should always be reported where possible, and further studies are needed to determine whether or not such invasion is an independent prognostic factor.

**Molecular Markers.** Molecular markers and genetic abnormalities are being evaluated as determinants of outcome. At the present time, however, insufficient data exist to include specific molecular markers in the staging system.

For the present time, molecular and genetic markers should be considered as important information to aid in histopathologic diagnosis, rather than as determinants of stage.

**Validation.** The current staging system has the capacity to discriminate the overall survival of patients with soft tissue sarcoma. Patients with Stage I lesions are at low risk for disease-related mortality, whereas Stages II and III entail progressively greater risk (Table 22.1). These figures are based on large numbers [patients in Stage I ( $n = 137$ ); patients in Stage II ( $n = 491$ ); patients in Stage III ( $n = 469$ )] of patients with primary tumors treated at a single institution. Patients with nodal or disseminated metastases have a poor prognosis. Validation of this staging system is also illustrated by the fact that the local recurrence rate is similar for all three

stages (Table 22.1). For this reason, any of these patients can be incorporated into studies that examine the consequences of adjuvant therapy for local recurrence.

## BIBLIOGRAPHY

- Billingsley KG, Burt ME, Jara E, Ginsberg RJ, Woodruff JM, Leung DHY, et al: Pulmonary metastases from soft tissue sarcoma: analysis of patterns of disease and postmetastasis survival. *Ann Surg* 229(5):602–610, 1999
- Brennan MF: Staging of soft tissue sarcomas. *Ann Surg Oncol* 6:8–9, 1999
- Coindre JM. Pathology and grading of soft tissue sarcomas. *Cancer Treat Res* 67:1–22, 1993
- Coindre JM, Terrier P, Bui NB, Bonichon F, Collin CF, Le Dousal V, et al: Prognostic factors in adult patients with locally controlled soft tissue sarcoma: a study of 546 patients from the French Federation of Cancer Centers Sarcoma Group. *J Clin Oncol* 14(3):869–877, 1996
- Fleming JB, Berman R, Cheng S, Chen NP, Hunt K, Feig BW, et al: Long-term outcome of patients with American Joint Committee on Cancer Stage IIB extremity soft tissue sarcoma. *J Clin Oncol* 17(9):2772–2780, 1999
- Fong V, Coit DG, Woodruff JM, et al: Lymph node metastasis from soft tissue sarcoma: analysis of data from a prospective database of 1772 sarcoma patients. *Ann Surg* 217:72, 1993
- Gaynor JJ, Tan CC, Casper ES, Collin CF, Friedrich C, Shiu MH, et al: Refinement of clinicopathologic staging for localized soft tissue sarcoma of the extremity: a study of 423 adults. *J Clin Oncol* 10:1317–1329, 1993
- Geer RJI, Woodruff JM, Casper ES, et al: Management of small soft tissue sarcoma of the extremity in adults. *Arch Surg* 127:1285–1289, 1992
- Guillou L, Coindre JM, Bonichon F, Bui NB, Terrier P, Collin CF, et al: Comparative study of the National Cancer Institute and French Federation of Cancer Centers Sarcoma Group grading systems in a population of 410 adult patients with soft tissue sarcoma. *J Clin Oncol* 15:350–362, 1997
- Heslin MJ, Lewis JJ, Nadler E, Newman E, Woodruff JM, Casper ES, et al: Prognostic factors associated with long-term survival for retroperitoneal sarcoma: implications for management. *J Clin Oncol* 15(8):2832–2839, 1997
- Pisters PWT, Leung DHY, Woodruff JM, Shi W, Brennan MF. Analysis of prognostic factors in 1041 patients with localized soft tissue sarcomas of the extremities. *J Clin Oncol* 14:1679–1689, 1996
- Pisters PWT, Pollock RE: Prognostic factors in soft tissue sarcoma. In Gospodarowicz M, O'Sullivan B (Eds.) *UICC: prognostic factors in cancer*. New York: Wiley, in press
- Van Glabbeke M, van Oosterom AT, Oosterhuis JW, Mouridsen H, Crowther D, Somers R, Verwij J, Santoro A, Buesa J, Tursz T: Prognostic factors for the outcome of chemotherapy in advanced soft tissue sarcoma: an analysis of 2185 patients treated with anthracycline-containing first-line regimens—European Organization for Research and Treatment of Cancer Soft Tissue and Bone Sarcoma group study. *J Clin Oncol* 17(1):150–157, 1999
- Weiss, SW, Goldblum, JR: *Enzinger and Weiss's soft tissue tumor*, 4th ed. Philadelphia: Mosby-Harcourt Brace, 2001



## HISTOLOGIES—SOFT TISSUE SARCOMA

8800/3	Sarcoma, NOS	8936/3	Gastrointestinal stromal tumor
8804/3	Epithelioid sarcoma	9040/3	Synovial sarcoma
8806/3	Desmoplastic small round cell tumor	9044/3	Clear cell sarcoma
8810/3	Fibrosarcoma	9150/3	Malignant hemangiopericytoma
8830/3	Malignant fibrous histiocytoma	9180/3	Osteosarcoma
8850/3	Liposarcoma	9220/3	Chondrosarcoma
8890/3	Leiomyosarcoma	9260/3	Ewing's sarcoma
8900/3	Rhabdomyosarcoma	9540/3	Malignant peripheral nerve sheath tumor
		9581/3	Alveolar soft-part sarcoma
		9743/3	Primitive neuroectodermal tumor

# SOFT TISSUE SARCOMA

**Hospital Name/Address**

**Patient Name/Information**

Type of Specimen \_\_\_\_\_

Histopathologic Type \_\_\_\_\_

Tumor Size \_\_\_\_\_

Laterality:     Bilateral     Left     Right

### DEFINITIONS

<i>Clinical</i>	<i>Pathologic</i>	<b>Primary Tumor (T)</b>	
<input type="checkbox"/>	<input type="checkbox"/>	TX	Primary tumor cannot be assessed
<input type="checkbox"/>	<input type="checkbox"/>	T0	No evidence of primary tumor
<input type="checkbox"/>	<input type="checkbox"/>	T1	Tumor 5 cm or less in greatest dimension
<input type="checkbox"/>	<input type="checkbox"/>	T1a	superficial tumor <sup>(1)</sup>
<input type="checkbox"/>	<input type="checkbox"/>	T1b	deep tumor
<input type="checkbox"/>	<input type="checkbox"/>	T2	Tumor more than 5 cm in greatest dimension
<input type="checkbox"/>	<input type="checkbox"/>	T2a	superficial tumor <sup>(1)</sup>
<input type="checkbox"/>	<input type="checkbox"/>	T2b	deep tumor

<i>Clinical</i>	<i>Pathologic</i>	<b>Regional Lymph Nodes (N)</b>	
<input type="checkbox"/>	<input type="checkbox"/>	NX	Regional lymph nodes cannot be assessed
<input type="checkbox"/>	<input type="checkbox"/>	N0	No regional lymph node metastasis
<input type="checkbox"/>	<input type="checkbox"/>	N1	Regional lymph node metastasis

<i>Clinical</i>	<i>Pathologic</i>	<b>Distant Metastasis (M)</b>	
<input type="checkbox"/>	<input type="checkbox"/>	MX	Distant metastasis cannot be assessed
<input type="checkbox"/>	<input type="checkbox"/>	M0	No distant metastasis
<input type="checkbox"/>	<input type="checkbox"/>	M1	Distant metastasis

Biopsy of metastatic site performed ....  Y .....  N

Source of pathologic metastatic specimen \_\_\_\_\_

<b>Stage Grouping</b>								
<input type="checkbox"/>	<input type="checkbox"/>	I	T1a	N0	M0	G1-2	G1	Low
			T1b	N0	M0	G1-2	G1	Low
			T2a	N0	M0	G1-2	G1	Low
			T2b	N0	M0	G1-2	G1	Low
<input type="checkbox"/>	<input type="checkbox"/>	II	T1a	N0	M0	G3-4	G2-3	High
			T1b	N0	M0	G3-4	G2-3	High
			T2a	N0	M0	G3-4	G2-3	High
<input type="checkbox"/>	<input type="checkbox"/>	III	T2b	N0	M0	G3-4	G2-3	High
<input type="checkbox"/>	<input type="checkbox"/>	IV	Any T	N1	M0	Any G	Any G	High or Low
			Any T	N0	M1	Any G	Any G	High or Low

**Notes**

1. Superficial tumor is located exclusively above the superficial fascia without invasion of the fascia; deep tumor is located either exclusively beneath the superficial fascia, superficial to the fascia with invasion of or through the fascia, or both superficial yet beneath the fascia. Retroperitoneal, mediastinal, and pelvic sarcomas are classified as deep tumors.

2. Ewing's sarcoma is classified as G4.



*(continued on reverse side)*

**Histologic Grade (G)**

- GX Grade cannot be assessed
- G1 Well differentiated
- G2 Moderately differentiated
- G3 Poorly differentiated
- G4 Poorly differentiated or undifferentiated (four-tiered systems only)<sup>(2)</sup>

**Residual Tumor (R)**

- RX Presence of residual tumor cannot be assessed
- R0 No residual tumor
- R1 Microscopic residual tumor
- R2 Macroscopic residual tumor

**Additional Descriptors**

For identification of special cases of TNM or pTNM classifications, the "m" suffix and "y," "r," and "a" prefixes are used. Although they do not affect the stage grouping, they indicate cases needing separate analysis.

- m suffix** indicates the presence of multiple primary tumors in a single site and is recorded in parentheses: pT(m)NM.
- y prefix** indicates those cases in which classification is performed during or following initial multimodality therapy. The cTNM or pTNM category is identified by a "y" prefix. The ycTNM or ypTNM categorizes the extent of tumor actually present at the time of that examination. The "y" categorization is not an estimate of tumor prior to multimodality therapy.
- r prefix** indicates a recurrent tumor when staged after a disease-free interval, and is identified by the "r" prefix: rTNM.
- a prefix** designates the stage determined at autopsy: aTNM.

**Prognostic Indicators (if applicable)**

**Notes**

**Additional Descriptors**

**Lymphatic Vessel Invasion (L)**

LX Lymphatic vessel invasion cannot be assessed

L0 No lymphatic vessel invasion

L1 Lymphatic vessel invasion

**Venous Invasion (V)**

VX Venous invasion cannot be assessed

V0 No venous invasion

V1 Microscopic venous invasion

V2 Macroscopic venous invasion

Physician's Signature \_\_\_\_\_ Date \_\_\_\_\_