

In this guide we will cover how to download the pretest results from the Learning Management System.

1. Login at <https://learning.facs.org>. Access the course activity by clicking on the title of the course from under the “In-Progress Activities”.

ACS / AMERICAN COLLEGE OF SURGEONS

Home Course Catalog **Learner Dashboard** ▾ How To Guides ▾ Contact Us About Us

In-Progress

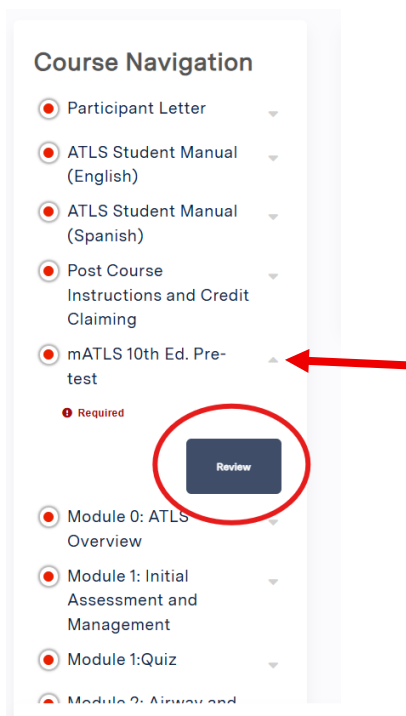
In-Progress Activities
Certificates & Transcript

View Edit Bookmarks **My activities** Orders

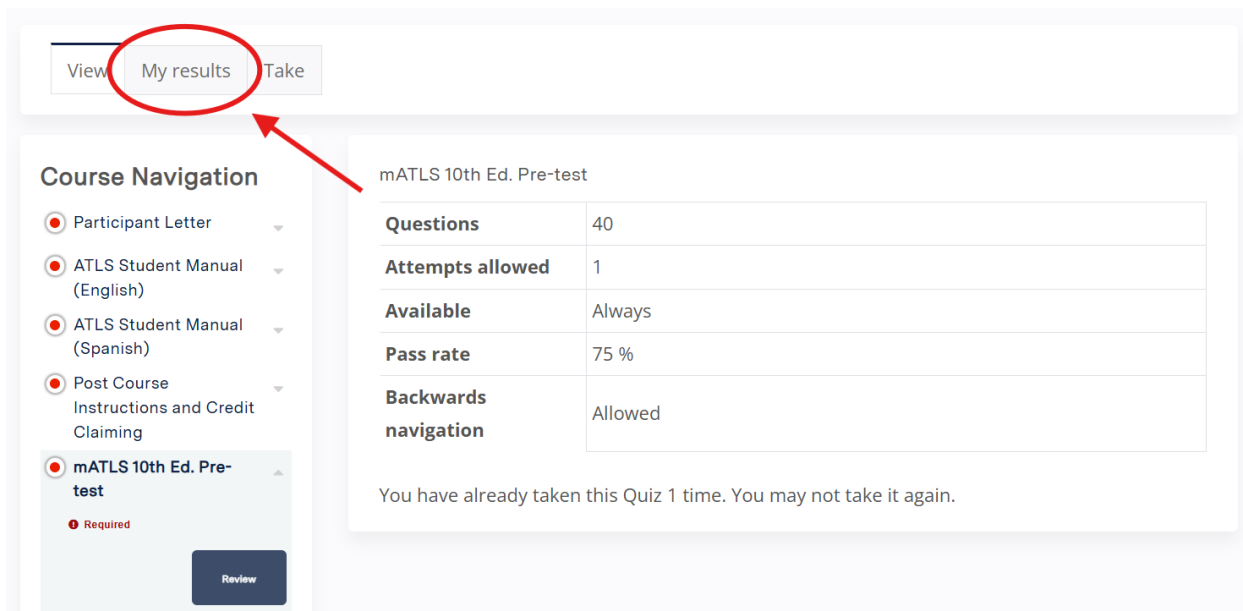
<u>Title</u>	<u>Status</u>	<u>Enrolled date</u>
<u>mATLS Hybrid - 1 day</u>	Pending Result In-Person Course	Sun, 05/18/2025 - 3:13pm



2. Under the “Course Navigation” select the arrow drop down for the Pre-test module and click the “Review” button.



3. Once on the Pre-test module, click on the “My results” button.



View **My results** Take

Course Navigation

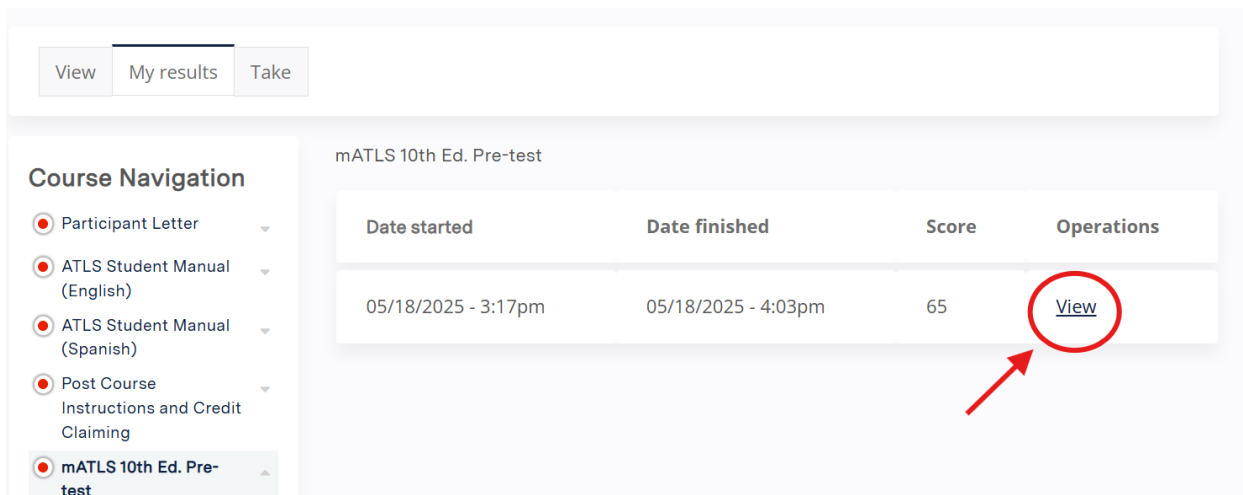
- Participant Letter
- ATLS Student Manual (English)
- ATLS Student Manual (Spanish)
- Post Course Instructions and Credit Claiming
- mATLS 10th Ed. Pre-test**
 - Required
 - Review

mATLS 10th Ed. Pre-test

Questions	40
Attempts allowed	1
Available	Always
Pass rate	75 %
Backwards navigation	Allowed

You have already taken this Quiz 1 time. You may not take it again.

4. Click the “View” button to open the Pre-test results.



View **My results** Take

Course Navigation

- Participant Letter
- ATLS Student Manual (English)
- ATLS Student Manual (Spanish)
- Post Course Instructions and Credit Claiming
- mATLS 10th Ed. Pre-test**

mATLS 10th Ed. Pre-test

Date started	Date finished	Score	Operations
05/18/2025 - 3:17pm	05/18/2025 - 4:03pm	65	View



5. To download a pdf of the results, select the “Download Pdf” option.

mATLS 10th Ed. Pre-test

Question results

You got 26 of 40 possible points.
Your score: 65%

Question 1

A 22-year-old man is hypotensive and tachycardic after a shotgun wound to the left shoulder. His blood pressure is initially 80/40 mm Hg. After initial fluid resuscitation his blood pressure increases to 122/84 mm Hg. His heart rate is now 100 beats per minute and his respiratory rate is 28 breaths per minute. A tube thoracostomy is performed for decreased left chest breath sounds with the return of a small amount of blood and no air leak. After chest tube insertion, what is the most appropriate next step?

Score: 1 of 1

Your answer	Choice	Correct?	Score
➔	Re-examine the chest	✓	1
	Perform an aortogram		0
	Obtain a CT scan of the chest		0
	Obtain arterial blood gas analysis		0
	Perform transesophageal echocardiography		0

If you have any questions please contact traumaeducation@facs.org

