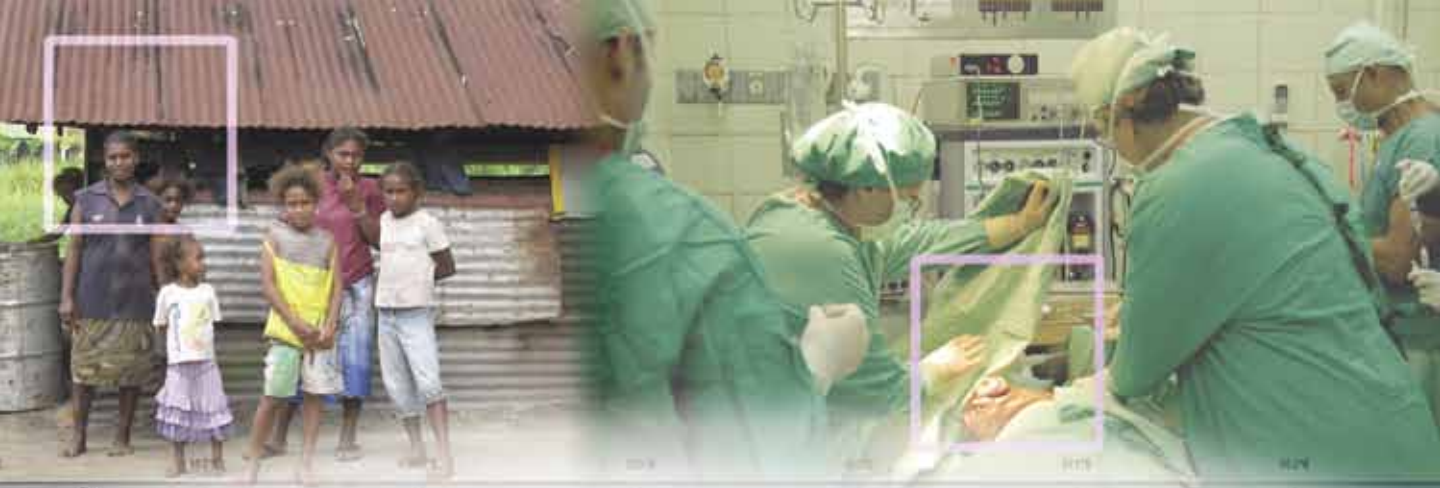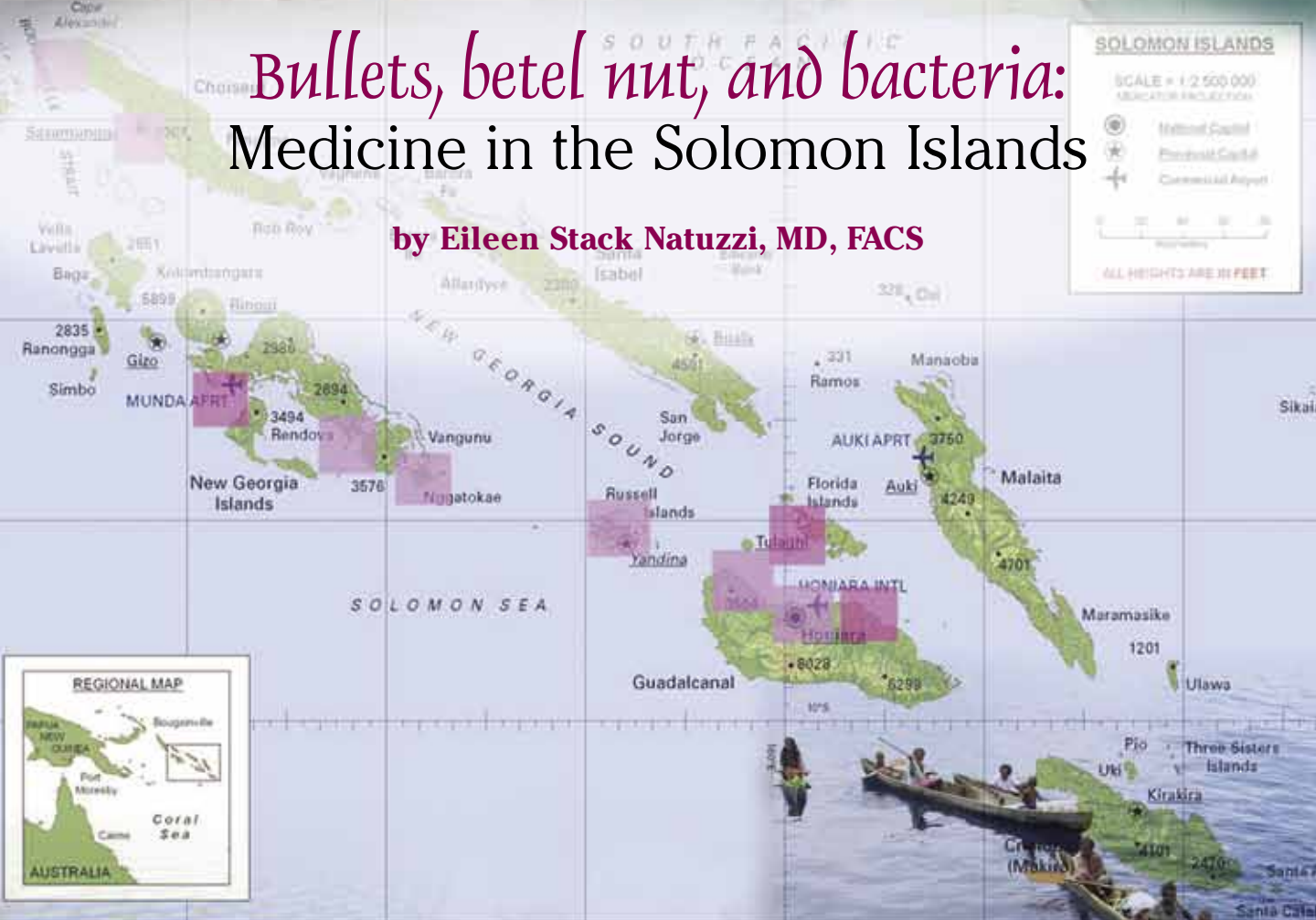




# Bullets, betel nut, and bacteria: Medicine in the Solomon Islands

by Eileen Stack Natuzzi, MD, FACS



---

In 1942, during World War II, nearly every American could tell you where the Solomon Islands were located and why they were important to us. Some of the fiercest and most savage battles between Allied and Japanese forces were waged on land, sea, and air throughout the islands. Over time, and with the gradual loss of many World War II veterans, very few Americans know about this small island country.

### ■ *The Solomon Islands*

The Solomon Islands are located in the Melanesian portion of the South Pacific, just north-east of Australia and New Zealand. The country consists of approximately seven large islands, 30 small islands, and many islets, spanning more than 1.3 million square kilometers. The population is just over 500,000, with 82 percent of the population living in a rural setting where there is limited electricity and no clean drinking water. Spoken languages include Solomon Island Pidgin, English, and 120 indigenous languages. The capital is Honiara, a dusty, dirty town located on the northern coast of Guadalcanal. Most of its infrastructure—including the airport, known as Henderson Field—was built during World War II. There are limited inter-island flights, and transportation between islands is mainly by ferry, outboard motorboat, or canoe.

I first heard of the Solomon Islands as a child during family gatherings. My mother's oldest brother, Bill, went there while in the navy during World War II. He was killed in action when his ship, the USS *Quincy CA-39*, was sunk during the Battle of Savo Island just off the coast of Guadalcanal. To my aunts and uncles, the Solomon Islands were very remote, tropical, and hostile. Their assessment was not unlike that of most Americans, post-World War II, after all the waters of Iron Bottom Sound and the jungles of

Guadalcanal and Tulagi had claimed thousands of lives and kept the remains of many men. I visited the Solomon Islands for the first time in 2004, drawn there by family history. But I came away from the trip with another take—what life was like for the people of the Solomon Islands.

The Solomon Islands is a country lost in time. There is very little manufacturing and production, and most people hunt, fish, and grow their own food. People live in villages and have very strong connections with their own village people, a support system known locally as wantok.

The Solomon Islands has had civil unrest over land use and ownership in the past. Thanks to the RAMSI (Regional Assistance Mission to Solomon Islands) multinational police force, the country is stable now.

Since being granted its independence from Britain in 1978, this young democracy has struggled to provide basic services, including health care, to its citizens. The ratio of practicing physicians to islanders is 1:28,000. In the U.S., the ratio is 1:300. There is one main hospital in the Solomon Islands. It is the National Referral Hospital (NRH), also known as “Number Nine,” or the Ninth Army Hospital from its World War II days (see Figure 1, page 18). The NRH is located in Honiara on Guadalcanal. This is the specialty care facility for the country, providing general surgery, orthopaedic surgery, gynecology, and obstetrics, as well as other forms of medical care. The hospital has three operating theaters. Patients are referred into the NRH from throughout the country, resulting in overcrowded clinics and long delays in the delivery of specialty care.

There are seven provincial hospitals, one of which, located in Gizo, was seriously damaged in the 2007 tsunami and is not yet fully operational. Each provincial hospital provides medical care for 30,000 to 40,000 people. Each hospital is staffed by nurses, and usually has a general medical doctor associated with it, but he or she is not necessarily present at all times. The most common procedure performed at the provincial hospitals is obstetrical deliveries; however, cesarean sections are not done. With the exception of incision and drainage of abscesses, surgical care is woefully lacking at the provincial hospitals. Nearly all of these hospitals are lacking an operating theater.

---

Opposite: Background photo: A map of the Solomon Islands; places where Loloma Foundation has worked are marked by purple boxes.

Border photos, clockwise from upper left: In a typical village scene, women and children pose by the communal kitchen building; Dr. Natuzzi's surgical team work in the operating theatre in the NRH; women in dugout canoes make up floating vegetable markets; Dr. Noble with a patient.

Throughout the different islands, there are hundreds of village-based small clinics or health outposts, staffed by nurses and nurse aids. Nurses confer with physicians via shortwave radio before prescribing drugs to patients. Doctors might visit a village once a year. Clinics, hospitals, and pharmacies frequently run out of supplies and medicines.

Geography adds to the problems the people of the Solomon Islands have in accessing urgent medical care. Since specialty care, including surgical services, is centralized to the NRH, a child with appendicitis might have to travel across rough seas for hours in a small outboard motor boat in order to get surgical treatment. Delays in surgical treatment result in children dying from the sequela of a ruptured appendix, and from curable diseases presenting in advanced stages. Emergency helicopter transportation for a critically ill patient can be provided by the medical arm of the RAMSI police force known as Aspen Medical Care, but provincial doctors hesitate to use this service, as charges for evacuation come out of their already meager monthly operational grant.

### ■ *The Loloma Foundation*

I am a member of the Loloma Foundation, which provides volunteer medical and surgical services in the Solomon Islands. The Loloma Foundation is the brainchild of Lance Hendricks, MD, an anesthesiologist at Scripps Clinic in San Diego, CA. “Heartchild” would probably be a better term, as loloma means “from the heart” in Fijian. Dr. Hendricks and other like-minded professionals recognized that the South Pacific is an area in dire need of a volunteer medical workforce because of a critical shortage of physicians. Loloma started out working in the outer islands of Fiji, and now it provides medical and surgical care for thousands of people in the Solomon Islands, as well.

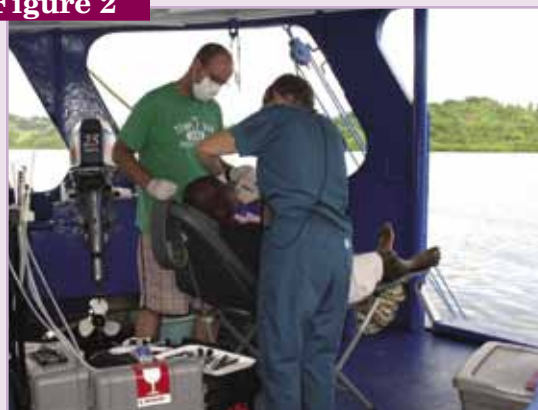For the past two years, we have sent teams of volunteer health care providers to the Solomon Islands in order to provide dental, medical, surgical, and vision care. On each trip, our group brings more than \$2 million dollars worth of donated medical supplies, corrective lenses, sunglasses, and tooth care products into the country. Gore, Ethicon, Abbott Point of Service,

**Figure 1**



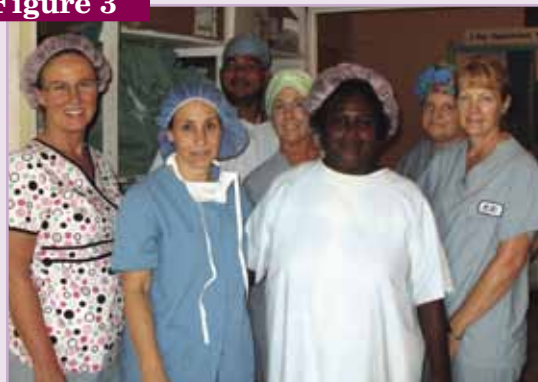The entrance to Casualty and Emergency Room at the NRH.

**Figure 2**



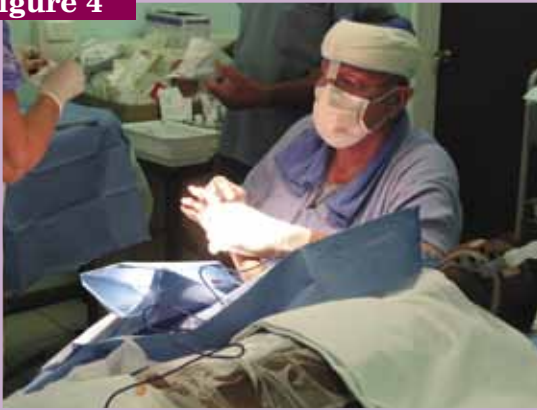The stern of the boat was used for dental procedures and some minor surgical procedures.

**Figure 3**



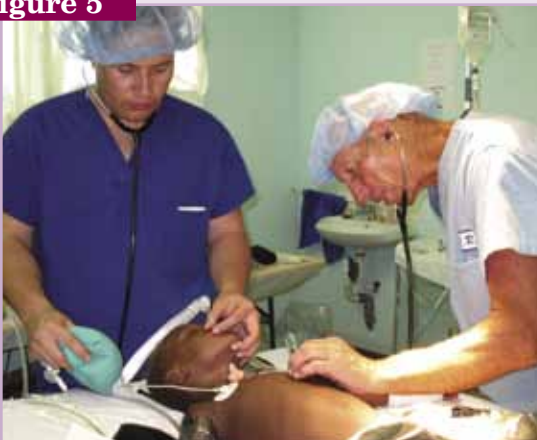The OR and PACU nurses pose with surgical staff at Helena Goldie Hospital in Munda. Left to right: Paula King, Kelly Laubach, Toma (local surgical technician), Chris DeWald, Gladys (local surgical nurse), Stacy Strah, and Grace Walker. Not pictured: Amy Kornasiewicz.

**Figure 4**



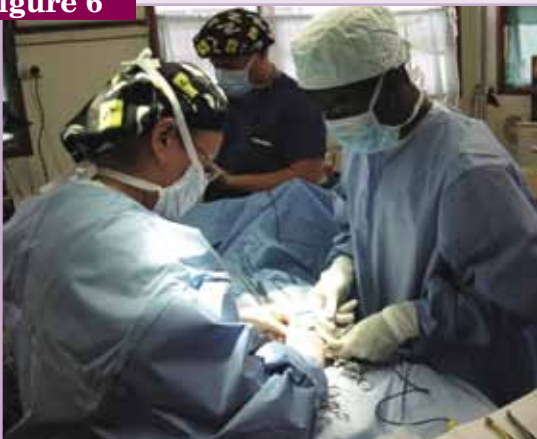Dr. Schneider in surgery.

**Figure 5**



Anesthesiologists: Dr. Tupuna (left) and Dr. Hendricks with a patient.

**Figure 6**



In Munda, Dr. Natuzzi (left) teaches Dr. Andrew Soma how to do a hernia repair. Teaching is very important, as it is a sustainable way to impact health care.

---

Sonosite, ConMed, Direct Relief International, Americares, Dioptics, and MAP International donate supplies to us. These supplies ship out of Santa Barbara, CA, in a 40-foot container, a few months before our trips, in order to have them in Honiara when we arrive.

### ■ *Spirit of the Solomons*

In order to reach the outer western islands of the Solomon Islands, where medical and surgical care is most needed, we charter a 125-foot dive boat, the *Spirit of the Solomons*. Medical supplies are loaded on the bow of the boat. We travel from island to island at night in order to treat patients during the day. Sites where we provide surgical care are visited for three days, in order to set up our MASH operating theater and conduct surgery as well as medical clinics (see Figure 2, page 18).

Our most recent team of health care providers included one obstetrician/gynecologist, two nurse practitioners, five internal medicine doctors, three optometrists, three support staff, and a video filmmaker, in addition to the surgical team. On previous trips, we have had a dentist and dermatologists with us as well. The ship's crew members, normally accustomed to assisting passengers with their dive gear, helped us with eye exams and translating. As a result of this experience, one of them, Philip, a local Solomon Islander, has decided to go on to medical studies.

The surgical team consisted of four very hard-working operating room (OR) nurses and two recovery room nurses from Scripps Green Hospital in San Diego (see Figure 3, page 18). We had three surgeons: myself, a general and vascular surgeon; Gerry Schneider, MD, FACS, a plastic surgeon (see Figure 4, this page); and Gary Noble, MD, a retired plastic surgeon. We also had two anesthesiologists: Dr. Hendricks, and Gabriel Tupuna, MD (see Figure 5, this page). Dr. Tupuna is an anesthesia registrar at Fiji School of Medicine, where Lance is a faculty member through the Scripps-Fiji Alliance. This alliance was created in order to facilitate academic exchanges between Scripps Health in San Diego and the Fiji School of Medicine in Suva, Fiji. Dr. Tupuna is from the Solomon Islands, so this trip gave him a chance to see how our team provides mobile surgical care

---

at the provincial hospitals in his country, and it gave us a chance to learn about Solomon Island tradition and culture from him.

Sites to provide surgical care were determined by reconnaissance visits months in advance of the trip, as well as by the overall need for surgical care due to remote location and lack of available surgical services. The participating provincial hospital doctors screened patients for surgical evaluation. Upon arriving at a surgical site, setup usually took about three hours, including conversion of a preselected room into an operating theater.

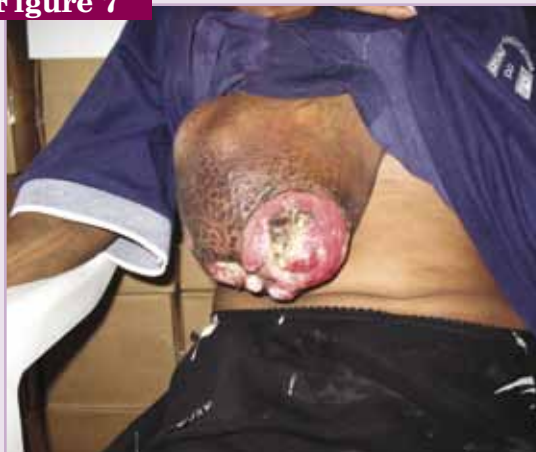There were no working anesthesia machines at the provincial hospitals where we worked. Dr. Hendricks and Dr. Tupuna used an oxygen tank available at each of the hospitals, and ran the oxygen through a sevoflurane vaporizer into a T-piece breathing system attached to a reservoir bag for ventilating the patients. All controlled ventilation for intubated, paralyzed patients was done manually. Whenever possible, procedures were done under spinal, regional, or local with monitored anesthesia care. Propaq monitors with EKG, blood pressure, and oximetry readings were used in the OR and in the makeshift post-anesthesia care unit (PACU). Pre-op lab assessment, mainly basic electrolytes and hemoglobin and hematocrit, were screened using a handheld iStat analyzer donated by Abbott Point of Care. We were unable to get a portable suction machine, so a very resourceful Dr. Hendricks created one using a shop vacuum.

The type of surgery we provided was practical and basic surgical care. We did not do laparoscopic procedures, due to the lack of equipment and at times lack of electricity.

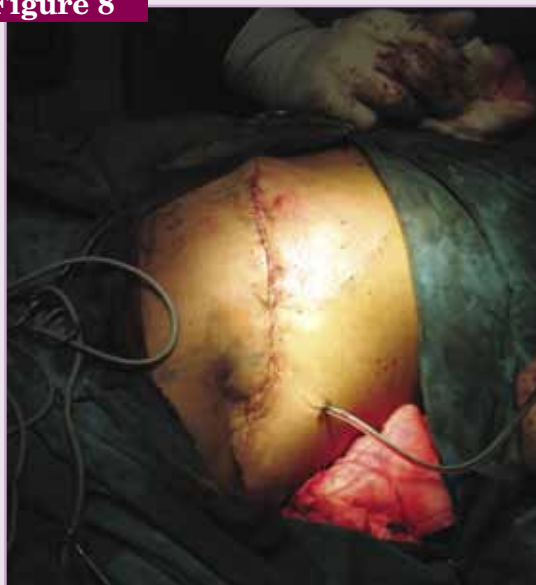Whenever possible, local provincial doctors scrubbed in as assistants in order to learn surgical skills (see Figure 6, page 19).

To date, we have treated more than 7,000 patients, and provided surgical care to just under 100 people in the Solomon Islands. In addition to excising lumps, treating trauma, and draining abscesses, our surgical team has performed umbilical and inguinal hernia repairs, varicose vein excisions, thyroid goiter excisions, parotid tumor excisions, cleft lip and syndactyly repairs, and exploratory laparotomies for ovarian tumors that were resectable and unresectable, as well as operating on advanced breast cancer and filariasis.

**Figure 7**



**Figure 8**

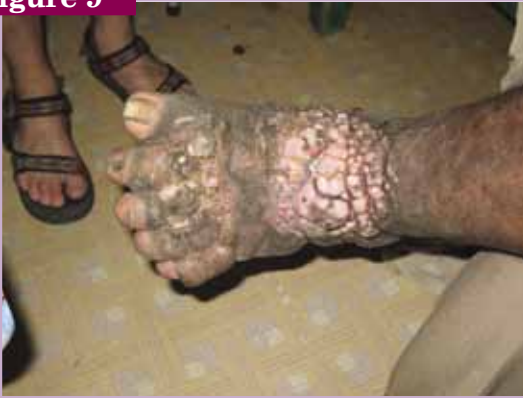

Diseases present in advanced stages due to lack of health care access. A large necrotic and fungating breast cancer, and the post-op mastectomy result.

### ■ *Treating cancer on the islands*

One of the most advanced cases of breast cancer I have ever seen was on Guadalcanal. The patient's name was Frieda. She was brought into one of our clinics with the diagnosis of a "breast lump." When Frieda arrived, I noticed a striking asymmetry to her chest. When she removed her shirt and some rather old and soiled bandages, I was shocked. She had the largest necrotic, fungating breast cancer that I had ever seen. It encompassed her entire right breast and had

**Figure 9**



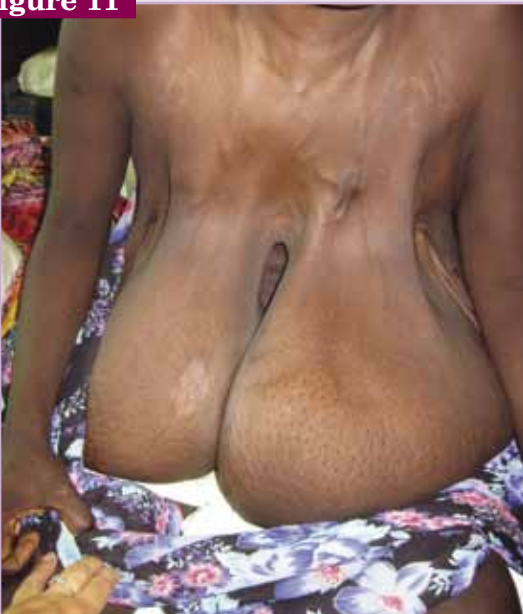A case of filariasis.

**Figure 10**



A lymphadenovarius involving the cheek.

**Figure 11**



Massive breast enlargement due to filariasis in a 26-year-old woman.

---

eroded through the skin, completely destroying the nipple (see Figure 7, page 20). I cleaned the open wounds with betadine and removed as much dead tissue as I could. It had just rained, and so the air was hot, thick, humid, and still. I was overwhelmed by the smell of rotting flesh and the numerous flies that surrounded Frieda, and could not imagine what it was like for her to live with this. We performed a palliative mastectomy at the NRH that night (see Figure 8, page 20). The weight of the tumor had stretched the skin over the breast like a tissue expander, and so we were able to close the defect primarily. Unfortunately, her axilla was full of matted tumor laden lymph nodes and she expired six months after surgery.

Breast cancer, cervical cancer, oral cancer, and lung cancer are the most common cancers in the Solomon Islands. The number of cases is difficult to determine, because many patients do not seek medical treatment due to availability, cost, or distance to travel to get care. Their village healers treat them, and then most succumb to their disease locally. There is limited chemotherapy treatment available, and no radiation treatment.

Cancer of the oral cavity has a strong association with the habit of chewing betel nut. 77 percent of adults in the Solomon Islands chew betel nut. Islanders' teeth are stained blood red from chewing betel nut, and the roads are peppered with red spit splats, the product of excess salivation caused by chewing the mix of betel nut, betel leaf, and lime powder made from coral. The mix is tucked between the gums and cheek, keeping its irritating contents in contact with the oral mucosa. We operated on two men with superficial parotid tumors, both of whom chew betel nut; studies from the British Columbia Cancer Research Center suggest there is a correlation between betel nut chewing and these types of tumors.

### ■ *Infectious diseases*

Infectious diseases and their long-term sequelae remain the leading cause of morbidity and mortality in the Solomon Islands, with malaria leading the scourge. Although malaria is not a surgical disease, it is important to know that it is the most common cause of an enlarged spleen

**Figure 12**



Dr. Natuzzi with children at a clinic in Tulagi, Florida Islands.

in young children in the Solomon Islands. Young children are particularly vulnerable to this complication of the disease. All throughout the islands, we saw children with complications resulting from prior malaria attacks, including cerebral palsy, dense hemiparesis, and deafness. The Pacific Malaria Initiative, through funding from the Australian Agency for International Development (AusAID), is very active in prevention and eradication of the disease in the Solomon Islands, as well as in Vanuatu. The introduction of Coartem (Novartis) combination drug therapies of artemether-lumefantrine and rapid malaria testing protocols to provincial hospitals and clinics may decrease the number of people suffering from malaria.

Filariasis, caused by *Wuchereria bancrofti*, is also prevalent in the Solomon Islands. We saw more than one patient with elephantiasis involving the lower extremity (see Figure 9, page 21). We also resected what we believe to be a lymphadenovarius involving the face, a variation from the usual presentation of filariasis. Both men we treated presented with soft mobile drooping masses hanging from the lower side of the face

(see Figure 10, page 21). The most impressive case of filariasis that we saw involved both breasts in a 26-year-old woman. Her breasts were enormous and so heavy that she could no longer stand upright (see Figure 11, page 21).


Appendicitis is a serious problem, and can result in death. It is usually diagnosed very late, and typically the appendix has already ruptured, causing generalized peritonitis or abscess formation. Treatment is further delayed by the need to travel long distances in order to get to the NRH, where surgical care is available. While we were working in Munda, a 28-week pregnant woman came to the hospital with right side and flank pain. Her urine dip test was normal and ultrasound evaluation showed normal adnexal structures and a viable fetus. My clinical suspicion was appendicitis. After admitting her to the hospital for a short period of observation, I decided to operate. The decision was the right one; she had a ruptured appendix that was compressed between her uterus and the right psoas muscle. Although she developed some mild contractions after surgery, we were able to control them and prevent premature delivery of her baby.

---

## ■ *Physician shortage crisis*

The physician shortage in the Solomon Islands is a crisis that cannot be ignored. Cuba has begun sending doctors to assist with the critical doctor shortage, and programs have been put in place for Solomon Island students to obtain their medical education in Havana.

Pacific Partnership, a U.S. Navy-supported program, treated patients in the western part of the Solomon Islands during their missions in 2007 and 2008. This year, we coordinated our efforts in the Solomon Islands with Pacific Partnership in order to provide seamless care to the people. Loloma Foundation and Pacific Partnership's medical trips collectively assist in the care of thousands of people in the Solomon Islands, but we must recognize that these are band-aid solutions for a country that needs a comprehensive program in order to end the physician shortage and improve the delivery of health care to its people. The type of program needed would require an initial infusion of volunteer manpower in the form of physicians, nurse practitioners, and nurse anesthetists. The program must include training and recruitment of the indigenous people of the Solomon Islands in order to create a sustainable health care force.

Surgical services must be considered a part of the "preventative medicine" strategy, and therefore, operating theaters and surgical care must be distributed throughout the islands. Without a basic health care scaffolding, money from the World Health Organization, AusAID, and the Global Fund that is directed toward treating specific diseases, such as malaria and tuberculosis, could be wasted, and could actually make things worse for the people of the Solomon Islands. I believe it is time for the U.S. to join with Australia and New Zealand, as well as the people of the Solomon Islands, in creating a sustainable health care system. With adequate numbers of doctors and nurses, in addition to well-stocked clinics and hospitals, the life expectancy and maternal mortality—which are measures of how well a health care system is providing for its people—will improve. Only then will the eradication of diseases such as malaria, tuberculosis, and HIV follow. 

---

## **Bibliography**

- Bennett J. *Wealth of the Solomons: A History of a Pacific Archipelago, 1800-1987*. Honolulu, HI: University of Hawaii Press; 1987.
- Debas H. Surgery. In: Jameson D, ed. *Disease Control Priorities in Developing Countries, 2nd edition*. Washington, DC: World Bank; 2005.
- Diamond J. *Guns, Germs and Steel: The Fates of Human Societies*. New York, NY: W.W. Norton and Company; 1997.
- Edelson M, Davidson R, Wilkinson R, Pierini S. *Oxford Handbook of Tropical Medicine, 2nd edition*. New York, NY: Oxford University Press; 2006.
- Fraenkel J. *The Manipulation of Custom*. Wellington, New Zealand: Victoria University Press; 2004.
- Garrett L. The challenge of global health. *Foreign Aff*. 2007;86(1):1-11.
- United Nations Development Programme. *UNDP Human Development Reports. 2007/2008 Human Development Index Rating*. Available at: <http://hdr.undp.org/en/statistics/>. Accessed December 2008.
- World Health Organization. *TB Country Profile*. Available at: [www.who.int/GlobalAtlas/predefinedReports/TB/PDF\\_Files/slb.pdf](http://www.who.int/GlobalAtlas/predefinedReports/TB/PDF_Files/slb.pdf). Accessed December 2008.

---

*Dr. Natuzzi is a vascular surgeon in private practice in San Diego, CA. She is executive director of the William Moore Stack Foundation, which supports education in the Solomon Islands. She is also the surgical coordinator for the Loloma Medical Foundation. Dr. Natuzzi may be reached at [esnmd@mac.com](mailto:esnmd@mac.com).*